

Review

A review of multiomics platforms in pituitary adenoma pathogenesis

Nikolaos Mouchtouris¹, Rupert D. Smit¹, Keenan Piper¹, Giyarpuram Prashant¹, James J. Evans¹, Michael Karsy^{2,*}

¹Department of Neurosurgery, Thomas Jefferson University Hospital, Philadelphia, PA 19107, USA

²Department of Neurosurgery, University of Utah, Salt Lake City, UT 84132, USA

*Correspondence: michael.karsy@hsc.utah.edu (Michael Karsy)

Academic Editor: Graham Pawelec

Submitted: 30 November 2021 Revised: 31 January 2022 Accepted: 10 February 2022 Published: 4 March 2022

Abstract

Pituitary adenomas (PA), or pituitary neuroendocrine tumors (PitNETs), represent 15% of all central nervous system tumors. Classic description of PitNETs solely by hormonal classification has given way to key transcription factors that play a role in the pathology of PitNETs including steroidogenic factor-1 (SF-1), t-box pituitary transcription factor (TPIT), and pituitary transcription factor 1 (PIT-1). Germline mutations in various familial PitNETs are discussed including those in familial isolated pituitary adenoma (FIPA), multiple endocrine neoplasia (MEN), neurofibromatosis 1 (NF1), and Carney complex. Recent advances in next generation sequencing have improved insight into the pathogenesis of PitNETs. A review of key studies in evaluating the genomic analysis of PitNETs was performed. Chromosomal mutations, whole exome sequencing, microRNA genomics, methylomics and transcriptomics were analyzed. Moreover, the multiomic analysis of various genomic panels has helped to better understand PA classification.

Keywords: pituitary adenoma; molecular genetics; PitNET; genomics; SF-1; TPIT; PIT-1

1. Introduction

Pituitary tumors represent nearly 15% of all central nervous system (CNS) tumors and are mostly comprised of pituitary neuroendocrine tumors (PitNETs), formerly called pituitary adenomas in earlier World Health Organization (WHO) classifications [1]. While most often benign, PitNETs can lead to a wide range of clinical symptoms through hormone secretion or mass effect on critical structures. The diagnosis and evaluation of PitNETs has evolved from the original histological description, e.g., acidophil, basophil, or chromophobe tumors as determined by hematoxylin and eosin staining. Most recently, however, there has been a concerted effort to develop a more personalized approach to diagnosing PitNETs that relies on the genetic, transcription, and protein biomarkers. In 2014, Raverot *et al.* [2] demonstrated the prognostic value of using genetic markers in the identification of tumors by proposing a novel clinicopathological classification that consisted of tumor size, hormonal immunochemistry, invasiveness, and markers of proliferation. The proposed classification demonstrated high prognostic value in predicting post-operative outcomes. With each successive iteration to the WHO classification, there has been a pivot away from the nonspecific nomenclature of “hormone-producing pituitary adenomas” and a shift towards the adenohypophyseal cell lineage designation of the tumors. In 2017, the WHO published the 4th edition of the classification of endocrine tumors and updated their diagnostic guidelines for PitNETs, introducing transcription factors into the diagnostic criteria [3]. This has been further solidified in the 2021 WHO guidelines [4].

The advancement of next generation sequencing genomics, including methylomics, transcriptomics, proteomics and even glycomics, have reinvigorated the discovery of disease pathogenesis. The integration of multiple platforms, termed multiomics, can be an effective way to understand disease across different levels of gene regulation. Biomarkers can also be combined with imaging and clinical assessment. Studying the multiomics of PitNETs has the tremendous potential of enhancing our understanding of the pathogenesis, invasiveness, recurrence, and prognosis of these tumors. In this review paper, we provide a detailed account of how multiomics is being utilized for optimizing the diagnosis and treatment of PitNETs.

2. Incorporation of multiomics in 2017 WHO classification of tumors of the pituitary gland

In 2017, WHO revised the classification of PitNETs to better represent the clinical characteristics of these tumors. A new emphasis was placed on identifying lineage-restricted pituitary transcription factors to determine adenohypophyseal cell lineages. Recent studies have revealed that key transcription factors which drive normal adenohypophyseal cell differentiation also play key roles in PitNET cytodifferentiation and hormone production [5]. The three main adenohypophyseal cell lineages and their correlated transcription factors are (Fig. 1): (1) gonadotrophs driven by expression of steroidogenic factor-1 (SF-1), (2) corticotrophs driven by t-box pituitary transcription factor (TBX19 or TPIT), and (3) somatotrophs, thyrotrophs, lactotrophs, and mammosomatotrophs driven by pituitary tran-



scription factor 1 (PIT-1; also known as POU1F1) [6]. Null cell tumors and plurihormonal tumors are considered separately: null cell tumors do not express any transcription factors, immunomarkers, or hormones, whereas plurihormonal tumors produce multiple hormones and are usually associated with PIT-1.

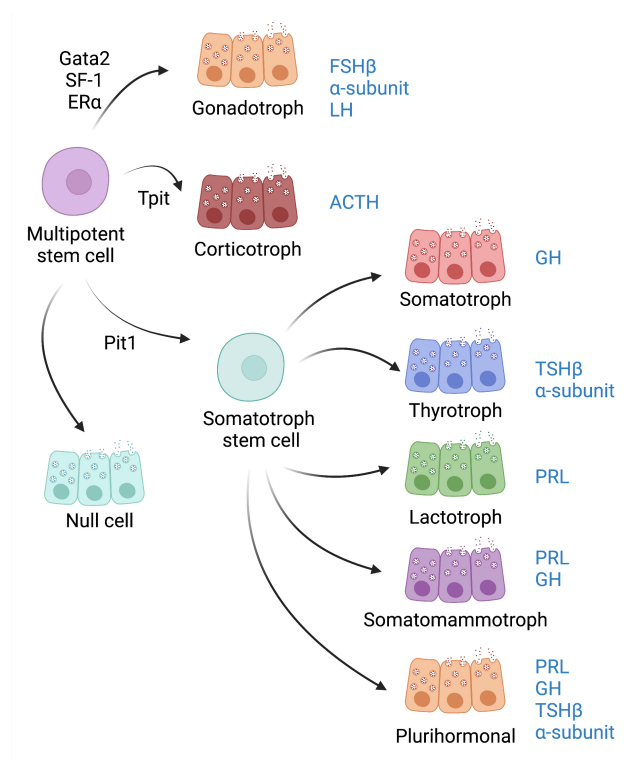


Fig. 1. Classification of pituitary tumors by transcription factors and hormonal staining. ACTH, adrenocorticotrophic hormone; FSH β , follicle-stimulating hormone; GH, growth hormone; PIT-1, pituitary transcription factor 1; PRL, prolactin; SF-1, steroidogenic factor 1; TPIT, t-box pituitary transcription factor; TSH β , thyroid stimulating hormone β .

The use of transcription factors is more reliable than prior methods that relied on microscopic morphology, immunohistochemistry against hormones, in situ hybridization, reverse hemolytic plaque assays, and electron microscopy [6]. Transcription factor identification is especially useful in tumors with minimal immunopositivity such as silent corticotrophs, somatotrophs, plurihormonal and immunonegative tumors [5]. Approximately 70–80% of non-functioning adenomas show staining for gonadotrophins, termed silent gonadotrophin adenomas (SGA) which overlap histologically with null cell adenomas that are more clinically aggressive [7]. Various transcription factors, including SF-1, PIT-1, and TPIT have been able to distinguish SGA from null cell adenomas (NCA). Importantly, while transcriptomics has improved the specificity of adenoma diagnosis, it is only partially descriptive of the tumor and should be used in conjunction with classi-

cal methods of diagnosis such as hormone expression [5,8].

The 2017 WHO reclassification also abandoned the term “atypical adenoma”, which was previously defined by mitotic index >3%, Ki-67 expression >3%, and positive p53 staining, as its prognostic value was inconsistent [3]. Instead, the authors suggest considering the rate of growth, extent of invasion, and Ki-67 expression to define the aggressiveness of a tumor [3,6].

Several specific PitNET tumors have been identified as especially high-risk. One type, silent corticotroph adenomas are TPIT positive, often large, and tend to invade the cavernous sinus [9,10]. Given their propensity towards more frequent and earlier recurrences, they should be monitored closely postoperatively. Notably, they often exhibit inconsistent Ki-67 and p53 levels and may rarely transform into carcinomas [11]. Crooke’s cell adenomas are another aggressive subtype of the corticotroph lineage that require close monitoring following resection given their exceptional tendency to recur [12]. Sparsely granulated somatotroph adenomas are an aggressive subtype of PitNETs which can be identified by their PIT-1 positivity and characteristic sparse granulation on histology [13]. Finally, plurihormonal PIT-1-positive adenomas, formerly known as silent adenoma type III, are large, monomorphous, invasive tumors with very high rates of recurrence [10,14].

The 2021 WHO classification of central nervous system (CNS) follows the 2017 WHO classification, grouping PitNETs by adenohypophyseal cell lineage and expression of pituitary hormones and transcription factors [4]. Both the 2017 and 2021 WHO classifications also recognize a new entity, the pituitary blastoma, which is a rare embryonal neoplasm of infancy composed of primitive blastemal cells, neuroendocrine cells, and Rathke epithelium. Pituitary blastomas are usually seen as part of the DICER1 syndrome and most commonly produce ACTH followed by GH [4].

While the 2017 WHO classification transitioned towards the use of transcription factor use for tumor identification, there has also been a rapidly growing body of literature on the multiomic dysregulations that contribute to the pathogenesis of nonfunctioning, functioning, and familial pituitary adenomas. For each type of tumor, we discuss the genomics, epigenetic, exomic, transcriptomic, and proteomic dysregulations as well as provide their clinical correlates.

3. Pathogenesis of nonfunctioning pituitary neuroendocrine tumors

3.1 Dysregulated signaling pathways in non-functioning PitNETs

Nonfunctioning pituitary adenomas (NF-PitNETs) are typically benign, characterized by their absence of hormonal overproduction, and show specific molecular changes that are hallmarks to their pathogenesis. Using immunohistochemical testing, NF-PitNETs are divided

into null cell adenomas and clinically silent gonadotrophs. Based on the 2017 WHO classification, null cell adenomas are defined as a pituitary adenomas without immunohistochemical evidence of cell-type-specific differentiation when using pituitary transcription factors and adeno-hypophyseal hormones. Silent gonadotrophs are discussed separately in section 4.2.

Two major signaling pathways at the genomic level contribute to the pathogenesis of nonfunctioning pituitary adenomas (Fig. 2): phosphoinositide 3-kinase (PI3K)/AKT and mitogen-activated protein kinase (MAPK). The PI3K/AKT signaling pathway promotes pathogenesis when there is dysregulation of the mammalian target of rapamycin (mTOR), Wnt, nuclear factor kappa B (NF- κ B), and pro-apoptotic pathways [15,16]. Aberrant AKT and mTOR activity is often implicated across the spectrum of malignancies. Long *et al.* [17] demonstrated that *AKT1*, *AKT2*, and *AKT3* are upregulated in NF-PitNETs relative to normal pituitary tissue. Upregulation of SHIP, GRB2 Associated Binding Protein 1/2 (GAB1/2), SHC, Son of Sevenless (SOS), AKT, IkappaB Kinase (IKK), NF- κ B, MEK1/2, ERK1/2, mTOR, 4E-BP1, glycogen synthase kinase 3 Beta (GSK3), and β -catenin along with downregulation of phosphoinositide 3-kinases (PI3K) p85, heat shock protein 90 (HSP90), and *BAD* were seen in patients with NF-PA, which are all downstream of PI3K/AKT signaling. Dysregulation of AKT results in disturbances in the mTORC1 signaling, Wnt pathway, NF κ B signaling, and *BAD* pro-apoptotic activity. The mTOR pathway is downstream to PI3K/AKT and can be contributory through upregulation of the *extracellular signal-regulated kinase 1/2 (ERK1/2)*, *AKT*, *ribosomal s6 kinase (RSK)*, *mTOR*, *PRAS40*, *RPTOR Independent Companion Of MTOR Complex 2 (RICTOR)*, *4EBP*, *ribosomal protein S6 (RPS6)* and *40S ribosome*, while downregulation of *protein kinase C (PKC)*, *PKCa*, and *p-AEBP*.

The MAPK signaling can be dysregulated in NF-PitNETs through alterations in the ERK1/2, JNK, p38 and ERK5 pathways. Through pathway network analysis, Long *et al.* [17] demonstrated that ERK/MAPK pathways were significantly activated in NF-PA development. It is well reported that ERK/MAPK can regulate proliferation apoptosis, and stress responses. ERK1/2 is upregulated through the cascade reactions in the RAS-Raf-MEK-ERK1/2 activation fashion. Phosphorylation at Ser446 or Ser447 in B-Raf are significantly increased in NF-PitNETs, in turn causing abnormal constitutive activation of the ERK/MAPK pathway. The two final important stress-activated cascades are p38 and JNK; they share synergistic functionality and both play important roles in inflammatory responses and controlling apoptosis. Both p38 and JNK pathways are involved in NF-PitNETs.

3.2 DNA hypermethylation in non-functioning PitNETs

Genome-wide methylation assays of functioning vs. nonfunctioning adenomas revealed that NF-PitNETs, in general, are defined by a higher frequency of gene hypermethylation [18]. Assessing β -values, with 0 being unmethylated and 1 being totally methylated, between normal pituitary sections and tumor sections reveal more methylation on average in NF-PitNETs. The researchers were able to identify the aberrantly methylated CpG loci, and upon further analysis of the regions of interest they found significantly higher levels of methylation occurring on select promoters *stratifin (SFN)*, *signal transducer and activator of transcription 5A (STAT5A)*, *fibroblast growth factor receptor 2 (FGFR2)*, *dual specificity phosphatase 1 (DUSP1)*, and *protein tyrosine phosphatase receptor type E (PTPRE)*. These promoters have not been extensively studied in the context of pituitary tumors, but the epigenetic silencing of *SFN* which encodes for the 14-3-3 protein, a known tumor suppressor, is similar to effects in other tumors such as gynecological malignancies. *STAT5A* expression is inversely correlated with promoter DNA methylation and downregulated in NF-PitNETs. Methylation profiles can also elucidate which downstream pathways are driven by the changes: Kober *et al.* [19] found that Wnt signaling, p53 signaling, and PI3K/AKT signaling were significantly more enriched in NF-PitNETs compared to normal pituitary sections.

3.3 Transcriptomics in non-functioning PitNETs

Principal component analysis (PCA) of the transcriptomics of non-functional compared to functional PitNETs revealed that pituitary tumors clustered according to the transcription factor responsible for cytodifferentiation of the pituitary gland. Pituitary tumors, were seen to cluster among 3 subtypes depending on driving transcription factors [20]. Clinically follicle stimulating hormone (FSH)/leutinizing hormone (LH)-PitNETs and NCAs were driven by SF-1, while adrenocorticotrophic hormone (ACTH)-PitNETs, and silent corticotroph PitNETs were driven by TPIT, and thyroid-stimulating hormone (TSH), prolactin (PRL)-, and growth hormone (GH)-PitNETs were driven by PIT-1. Pathway enrichment analysis found several NF-PitNETs demonstrated significant alterations of genes involved in metabolism resulting in higher upregulation of calcium signaling pathways compared with functional adenomas. Moreover, the transcriptome of NF-PitNETs showing alterations in calcium-related genes implicated a wide-range of disrupted signaling pathways. Distinctly, ACTH-PitNETs showed enrichment of renin-angiotensin system regulation and TSH-/PRL-/GH-PitNETs showed clustering of fatty acid metabolism genes.

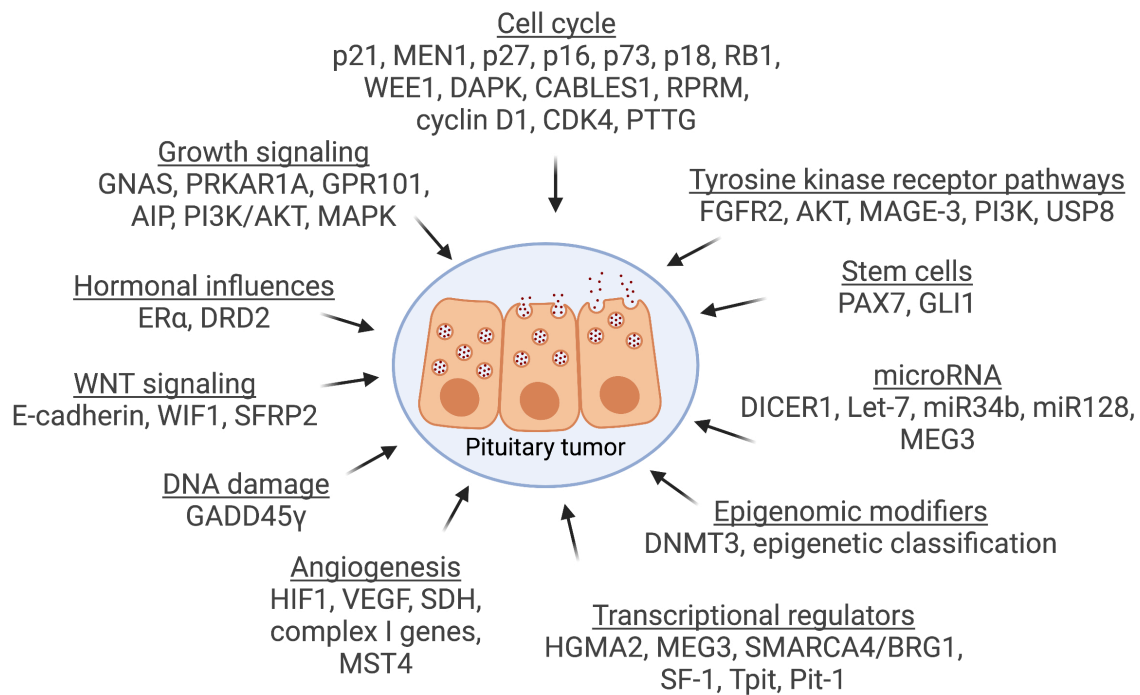


Fig. 2. Genetic factors and molecular changes involved in pituitary adenoma pathogenesis. Various genetic factors and molecular changes that play a role in pituitary tumor pathogenesis. AIP, aryl hydrocarbon receptor interacting protein; CABLES1, Cdk5 and Abl Enzyme Substrate 1; DAPK, death-associated protein kinase; DNMT1, DNA methyltransferase 1; DRD2, dopamine receptor D2; FGFR2, fibroblast growth factor receptor 2; GADD45 γ , Growth arrest and DNA-damage-inducible protein 45 γ ; HGMA2, High Mobility Group AT-Hook 2; HIF1, hypoxia inducible factor 1; MAGE-3, melanoma-associated antigen 3; MAPK, mitogen-activated protein kinase; MEG3, maternally expressed gene 3; PAX7, paired box protein 7; PI3K, phosphoinositide 3-kinases; PIT-1, pituitary transcription factor 1; PRKAR1A, cAMP dependent protein kinase A (PKA) type I- α regulatory subunit (RI α); PTTG, securing; RPRM, reprimo; SDH, succinate dehydrogenase; SFRP2, secreted frizzled related protein 2; SF-1, steroidogenic factor 1; SMARCA4, SWI/SNF related, matrix associated, actin dependent regulator of chromatin A4; TPIT, t-box pituitary transcription factor; USP8, ubiquitin specific peptidase 8; VEGF, vascular endothelial growth factor; WIF1, wnt inhibitory factor 1.

4. Pathogenesis of functioning pituitary adenomas

4.1 Overview of functional PitNET classification

Functioning PitNETs are divided into 5 main “troph” subtypes (with respective hormone markers): lactotrophs (PRL), somatotrophs (GH), thyrotrophs (TSH), corticotrophs (ACTH), gonadotrophs (FSH/LH). However, there are multiple layers of genetic, transcriptomic, proteomic alterations that have redefined the PitNET landscape where single driver gene mutations have been unable (Fig. 2). While 80% of PitNETs show some disruption to the cell cycle, most tumors present with no observed genetic changes [21]. However, somatic mutations that accelerate tumorigenesis can be seen in up to 40% of PitNETs [22].

Neou *et al.* [23] evaluated 134 patients with a large variety of functional tumor types with differing aggressiveness via multiomics, specifically assessing chromosomal alterations, miRNomics, methylomics and RNA transcriptomics. They demonstrated that the methylome of PitNETs stratified the tumors into three groups, based on

collapsed CpGs and associated with secretion type: met1 correlated with somatotrophs, lactotrophs, and thyrotrophs; met2 correlated with gonadotrophs; met3 correlated with corticotrophs. They noted that PIT-1 mutations may drive expression of *tet methylcytosine dioxygenase 2 (TET2)*, which encodes a demethylating enzyme where PIT-1 derived tumors demonstrate global hypomethylation.

With regards to assessing epigenetic activity Neou *et al.* [23] investigated the viability of microRNAs (miRNA) as a method for classification. MicroRNA are noncoding RNAs responsible for gene expression/silencing through RNA cleavage. PitNETs were divided into 4 groups based on miRNA clusters and these groups separated PRL (miR1), GH (miR2), ACTH (miR3), and FSH/LH tumors (miR4).

Finally, investigating the transcriptome of PitNETs by RNA sequencing produced arguably the most informative profile to date. To bypass the need for exome enrichment, researchers may opt for RNA sequencing (transcriptome sequencing), analyzing the RNA being tran-

scribed in a cell/tissue at that time. A benefit to high throughput RNA sequencing is that it provides insight into which genes are active and quantifies how much they are transcribed, however it does not identify eventual downstream translated proteins. Using their 134 samples to determine mRNA clusters, Neou and colleagues categorized the tumors into 6 distinct groups (t1–t6) that correlated with the WHO 2017 classification guidelines, with a few notable discrepancies. Mixed GH-PRL PitNETs were clustered together with somatotroph PitNETs (t6 cluster), implying that they are GH-predominant in origin. USP8 wild-type corticotrophs (t1 cluster) appeared more aggressive with greater sphenoid sinus invasion, which was further supported by the transcriptome demonstrating increased epithelial-mesenchymal-transition (EMSA) signature. Overall, multifactor analysis that combined transcriptome classification with GNAS/USP8 mutation status better fit the molecular groups than the WHO 2017 histoprognostic classifications.

Neou *et al.* [23] performed whole exome, single nucleotide polymorphisms (SNP), DNA methylation, microRNA profiling, and mRNA sequencing on 134 PitNETs. Multifactor analysis provided a comprehensive and new molecular classification for PitNETs that, in addition to confirming the histological relevance of WHO 2017 classifications, provided an accurate pangenomic blueprint for predicting a tumor's aggressiveness and responsiveness to treatment.

4.2 Gonadotrophs

Gonadotrophs are a great example of the need for genetic testing to determine the PitNET subtype. Gonadotrophs are commonly negative for FSH and LH but can be reliably detected by their nuclear immunoreactivity for SF-1. Given the lack of hormone secretion, they are often clinically silent and therefore act like nonfunctioning adenomas [24]. Among those that stained positive for a pituitary hormone, FSH-positive tumors were significantly more common than LH-positive tumors. Despite being clinically silent, these tumors are distinct from null cell tumors. In addition to SF-1 expression, these tumors show variable expression of nuclear transcription factors including estrogen receptor α (Er α), and GATA2/3 [25]. When comparing to NCAs, SGAs had lower MIB-1 levels ($2.49 \pm 1.41\%$) than NCAs ($3.43 \pm 2.76\%$; $p = 0.044$). Further, Hong *et al.* [26] showed that NCAs more commonly invade the cavernous sinus than gonadotroph adenomas ($p = 0.043$), which led to a significant difference in extent of gross total resection ($p = 0.039$). Gonadotrophs tend to be indolent in nature. In a study for 1166 patients with pituitary adenomas, 12.8% ($n = 149$) were SGAs and 9.2% ($n = 107$) were NCAs. NCAs were significantly more common in female patients than SGAs (61.7% vs 26.8%, $p < 0.001$). Gonadotrophs had a significantly lower recurrence ($p = 0.021$), adjuvant radiation therapy usage ($p = 0.002$),

and postoperative diabetes insipidus ($p = 0.028$) than NCAs. NCA subtypes were independently associated with tumor recurrence (HR 3.64, 95% CI 1.07–12.30; $p = 0.038$), cavernous sinus invasion (HR 3.97, 95% CI 1.04–15.14; $p = 0.043$) and larger anteroposterior dimension of the tumor (HR 2.23, 95% CI 1.09–4.59; $p = 0.030$).

Gonadotrophs can also present as part of a synchronous multiple PitNET lesion. In a study of 1055 PitNETs, 13 (1.23%) tumors had more than one cell lineage [25]. Of the 13 tumors, 8 were gonadotrophs that co-existed with one of the following tumors: lactotroph, poorly differentiated PIT-1 tumor, or corticotroph.

Epigenetic dysregulation also significantly varies by PitNET subtype and makes up an important part of PitNET multiomics. In a study of 105 PitNETs, 35 (33.3%) were SGAs and were found to have hypermethylation of *estrogen receptor 1* (*ESR1*) and *Ras Association Domain Family Member 1* (*RASSF1*) genes ($p = 0.055$ and $p = 0.050$, respectively) [27]. Both *ESR1* and *RASSF1* are implicated in cancer progression.

Further, a study by Principe *et al.* [28] discovered that gonadotrophs have an increased number of CD68+ and CD163+ M2-like macrophages. Presence of M2-like macrophages correlated well with increased gonadotroph tumor invasion that is mediated by collagen degradation via the matrix metalloproteinase-9 enzyme (MMP-9). M2-like macrophages exert a protumor role in solid tumors, promoting aggressiveness, proliferation, and invasion.

4.3 Corticotrophs

The second most commonly-identified somatic mutation, a gain-of-function *Ubiquitin Specific Peptidase 8* (*USP8*) mutation, occurs in 30% of corticotroph tumors. Song *et al.* [29] sequenced 125 adenomas and found recurring mutations of *USP8* in corticotrophs. *USP8* encodes for a deubiquitinase enzyme that removes conjugated ubiquitin from epidermal growth factor receptor (EGFR), thus preventing EGFR degradation. Gain-of-function mutations in *USP8* increase deubiquitination of EGFR leading to excess EGFR signaling as well as increased proopiomelanocortin (POMC) levels. Cleavage of POMC leads to the ACTH peptide hormone. Clinically, *USP8*-positive tumors are smaller, more frequently found in females, produce more ACTH, and have better outcomes when compared to *USP8*-negative corticotrophs. *USP8* wild-type PitNETs appeared more aggressive when compared to *USP8*-mutated PitNETs ($p = 0.018$) with more common sphenoid sinus invasion ($p = 0.007$). However, in a study by Albani *et al.* [30], *USP8*-mutated corticotroph tumors were diagnosed at a younger age ($p = 0.028$), had higher preoperative 24-hour urinary-free cortisol levels ($p = 0.045$), and had a higher recurrence rate ($p = 0.026$) at the 10-year follow-up than the *USP8*-wild type tumors. Further, the elevated invasiveness of PitNETs with wild-type *USP8* was corroborated by the increased the epithelial-mesenchymal-transition signature

in the transcriptome signature of corticotrophs, a genetic marker of tumor aggressiveness. Interestingly, *USP8* status did not affect cavernous sinus invasion or MIB1/Ki67 index. Furthermore, *somatostatin receptor 5 (SSTR5)* expression is increased in *USP8*-mutated corticotroph PitNETs. The presence of *USP8* mutation may reflect more favorable response to somatostatin receptor ligands (e.g., paserotide) and EGFR-directed therapies (e.g., gefitinib).

Epigenetic alterations in DNA methylation also play a role in corticotroph PitNET tumorigenesis. Salomon *et al.* [31] reported that DNA hypomethylation was seen in only some of the PitNET subtypes; more specifically, POMC hypomethylation was noted in ACTH-secreting tumors. It is worth noting that in corticotroph PitNETs, expression of *SSTR5* was also higher in *USP8*-mutated tumors compared with *USP8*-wild type tumors.

4.4 Somatotrophs

The most frequent somatic change in somatotroph PitNETs is the heterozygous gain-of-function mutation of the *GNAS* gene. The mutation to the G-protein subunit negatively affects GTPase activity, increases cAMP production, ultimately resulting in increased cell proliferation. *GNAS* is an imprinted gene and any somatotroph PitNET with a *GNAS* mutation will be located on the maternal allele. *GNAS* mutations are found in 30–40% of somatotroph PitNETs and are clinically relevant because they may increase the sensitivity to somatostatin therapies. Song *et al.* [29] reported that *GNAS*-mutated somatotrophs correlated with being less invasive and less resistant to somatostatin analogs. Similarly, *GNAS*-mutated tumors also had an increased expression of *Dopamine Receptor 2 (DRD2)*; the impact of the *DRD2* is well-known from their high prevalence in lactotrophs, where it is thought to explain why lactotrophs are so responsive to dopamine agonists. However, the relationship between increased dopamine receptor expression and responsiveness to dopamine agonists has not been established yet in somatotrophs [32]. Interestingly, the gonadotroph transcription factor SF-1 has been found to be expressed in *GNAS*-wild type somatotrophs [22]. Somatotrophs have also been shown to have increased *SSTR5* and *SSTR2* expression in comparison to other SST receptors, which impacts their response to somatostatin analogs (SSA) [33,34]. SSAs mainly target *SSTR2* and *SSTR5* and have shown promising results. First-generation SSAs, octreotide and lanreotide, preferentially bind *SSTR2* and have moderate affinity for *SSTR5*. The newer SSA, pasireotide, has greater binding affinity for *SSTR5* and less for the rest (*SSTR2* > *SSTR1* > *SSTR3*). The resistance to SSAs is also influenced by *GNAS* imprinting [35]. PitNETs with relaxed *GNAS* imprinting had lower expression of *GNAS* and *SSTR* expression, resulting in lower sensitivity to analogs and therefore more aggressive behavior.

DNA hypomethylation of *GHI* and *SSTR5* is seen in GH-secreting tumors. Song *et al.* [29] sequenced 125 ade-

nomas and found recurring mutations of *GNAS* in somatotrophs. Also, Song *et al.* [29] found additional recurring loss-of-function mutations in *MEN1* in plurihormonal adenomas producing both GH and PRL from patients without a history of familial MEN1 syndrome or without germline mutations of *MEN1*. Lastly, alterations of chromosome 1, 2, 11 and 18 positively correlated with tumor recurrence.

4.5 Thyrotrophs

Thyrotroph PitNETs account for 0.5–3% of all PitNETs [32]. Most of these tumors are sporadic and produce TSH, leading to a clinical presentation consistent with central hyperthyroidism. The most common transcription factors involved in this tumor subtype are the PIT-1, GATA-2/3, β -TSH, and/or α -subunit (α -SU). They also express *SSTR1*, *SSTR2*, *SSTR3*, and *SSTR5*. Additionally, Luo *et al.* [32] suggest the involvement of *Wnt4* gene in tumorigenesis, as evidenced by the increased *Wnt4* gene expression seen in TSH PitNETs.

Thyrotroph tumors are often composed of fascicles of spindle cells and can contain calcification and fibrous connective tissue. Basic fibroblast growth factor (bFGF) is involved in regulation of TSH and mediates the process of fibrosis, which may explain why 40% of thyrotroph tumors are more fibrotic than the rest of the PitNETs subtypes.

TSH-secreting PitNETs also include poorly-differentiated PIT-1 tumors, previously known as silent subtype 3. These are more aggressive and invasive tumors; they express *PIT-1*, *GATA-2/3*, *ER- α* , *α -SU*, *TSH β* , *GH*, *PRL*, and/or *CAM5.2* and do not have a consistent hormone expression pattern. Furthermore, TSH can be secreted in conjunction with GH and PRL as part of a plurihormonal PitNET. More specifically, co-secretion with GH and PRL is seen in 16% and 10% of TSH PitNETs respectively. Co-secretion with the rest of the hormones is very rare.

While surgery is the first line treatment for thyrotroph tumors, somatostatin analogues can be effective against some TSH-secreting tumors given their *SSTR* expression. Unfortunately, poorly-differentiated PIT-1 tumors are resistant to medical therapy. Thyrotroph cells also express dopamine receptors on their cell membrane, which is why dopamine receptor agonists, such as bromocriptine and cabergoline can be effective.

4.6 Lactotrophs

Lactotroph pituitary adenomas express mainly PRL and arise from PIT-1 lineage of adenohypophyseal cells. They are the most common functioning PitNETs, accounting for 30–50% of all adenomas. In addition to PIT-1, lactotrophs also express *ER- α* . They are further subdivided into three subtypes: sparsely granulated lactotroph adenomas (SGLA), densely granulated lactotroph adenomas (DGSA), and acidophil stem cell adenomas (ASCA). SGLAs are the most common subtype and have an excellent response to treatment with a dopamine agonist. SGLAs

demonstrate Golgi-like PRL expression, while DGLAs and ASCAs show expression diffusely in the cytoplasm. ASCAs will usually demonstrate scattered GH expression as well diffuse PRL reactivity.

While lactotrophs can appear as part of a familial syndrome such as MEN1, FIPA, or Carney complex, somatic mutations can occur in up to 19.8% of prolactinomas. The most common mutation identified was in the *splicing factor 3 subunit B1 (SF3B1)*, which results in stronger binding of the pituitary-specific positive transcription factor 1, leading to abnormally elevated prolactin levels as well as more rapid tumor growth. The presence of mutated *SF3B1* portends worse prognosis for patients. Furthermore, lactotroph PitNETs demonstrated higher expression of *Dopamine receptor 2 (DRD2)* which explains the effectiveness of dopamine agonists (e.g., cabergoline) as treatment and their adoption as the first-line agent. They also express SSTR5, which is why SSA can influence prolactinomas. Given its affinity for SSTR5, pasireotide seems to have the most effective SSA for this subtype.

Further multiomic research is necessary to elucidate which lactotroph PitNETs are refractory to medical therapy. A study by Delgrange *et al.* [36] identified lactotroph PitNETs in men as more likely to be treatment resistant and demonstrate histopathological aggressiveness as compared to women, and are thus considered another high-risk variant. As other studies have shown contradicting results [37,38], further investigation utilizing multiomic analysis is thereby needed.

5. Pathogenesis of familial PitNETs

Although most pituitary tumors are sporadic in nature, 5% of PitNETs are driven by monogenic germline mutations (Fig. 3). The familial subset of PitNETs can be divided into isolated (only pituitary affected) and syndromic, such as multiple endocrine neoplasia 1 and 4 (MEN1/4), neurofibromatosis type 1, and Carney complex. Familial isolated pituitary adenoma (FIPA) and MEN1 account for most familial cases of pituitary adenoma. FIPA is characterized by the presence of PitNETs in two or more family members with no other syndromic features. Twenty percent of FIPA patients are positive for a mutation in the *Aryl hydrocarbon receptor Interacting Protein (AIP)* gene, which normally regulates inflammatory pathways by stabilizing the aryl hydrocarbon receptor (AHR) in the cytoplasm; a widely distributed tumor suppressor protein expressed in GH cells and PRL-secreting cells of the pituitary. The *AIP* mutation promotes somatotrophs and lactotrophs in patients in their 20s, with 40% of patients presenting with gigantism, reflective of its impact on younger patients. Another key characteristic is that *AIP* mutations predispose patients to more aggressive and large tumors with an increased risk for apoplexy, that are poorly responsive to somatostatin analogues.

MEN1 patients typically present with the triad of a PitNET, primary hyperparathyroidism, and a pancreatic neu-

roendocrine tumor (i.e., gastrinoma) [33,34]. The MEN1 phenotype is inherited in an autosomal dominant fashion with a germline mutation to the *MEN1* gene located on chromosome 11, a ubiquitous transcription cofactor that normally regulates G₁-S cell cycle proteins, in turn serving as a tumor suppressor. It encodes for the MENIN protein that is a scaffold protein and exerts its effect on cell proliferation via histone methylation [33,34]. Patients with MEN1 syndrome that do not present with a mutation to the *MEN1* gene often have mutations in *CDKN1B*; this phenotype is called the MEN4 syndrome. Correspondingly, MEN1 pituitary-related disease usually presents with lactotrophs while MEN4 syndrome patients present with somatotroph PitNETs. Tumors that are *MEN1* mutation carriers are more aggressive than *MEN1*-negative tumors.

Other familial syndromes, such as McCune-Albright syndrome, Carney complex, and X-linked acrogerism, may result in either PitNETs or, less commonly, pituitary hyperplasia [35]. McCune Albright syndrome is caused by a missense mutation at Gln227 or Arg201 of the *GNAS* gene during embryogenesis, leading to increased intracellular cAMP and subsequent hormonal dysregulation [39]. Because the mutation is acquired spontaneously during embryogenesis, the cells affected, and myriad symptoms are distributed in a mosaic pattern. The typical triad of symptoms are osteotic fibrous dysplasia, café-au-lait spots, and hyperfunctioning endocrinopathies, including acromegaly in 20% of cases and hyperprolactinemia in 81% [40]. In a review of all 112 patients with MAS and acromegaly, 54% had a PitNET, and many of these tumors were exceptionally resistant to treatment. Surgery, which was attempted in a minority of the patients, rarely cured GH/IGF-1 excess, and medical treatment with somatostatin analogs achieved control of acromegaly in only 30% of patients.

Carney complex is another multiple endocrine neoplasia that is most often inherited in an autosomal dominant fashion [41]. Germline mutation of the *PRKARIA* gene on chromosome 17, responsible for 70% of familial cases, leads to dysregulation of protein kinase A (PKA) activity and tumor development in endocrine and non-endocrine organs. PKA is a cAMP-dependent threonine kinase that is involved in numerous intracellular signaling processes and its role in each cell type is dependent on the substrates present, its localization within the cell, and the activity of regulatory proteins [41]. Loss of function of PKA regulation, as seen in the *PRKARIA* mutation of Carney complex, results in increased mitosis and cell proliferation in specific cells, including the somatotrophs of the anterior pituitary. In a study of 353 patients, this mutation resulted in a GH-secreting PitNET in 12% of cases [42]. The *PRKARIA* mutation also drives development in 37% of non-familial cases of Carney complex, an even more rare occurrence [41]. Other mutations in the protein kinase A regulatory subunit, such as *PRKACB*, have been described [43]. Interestingly, the acromegaly that results from Carney complex may be due

Syndrome	Mutation	Clinical findings
FIPA	AIP GPR101	Pituitary tumor only
MEN1/4	MEN1 CDKN1B	parathyroid, pancreatic, neuroendocrine, adrenal cortical, neuroendocrine, angiofibroma, lipoma, meningioma, ependymoma
Carney complex	PRKAR1A PRKACB	Myxoma, adrenal, thyroid, gonads, LCSST, psammomatous melanotic schwannoma, osteochondromyxoma
McCune-Albright	GNAS	Polyostotic fibrous dysplasia, thyroid, pancreas, gastrointestinal polyps, cafe-au-lait spots, early puberty
HPGL/PCC	SDH MAX	Renal cell carcinoma, gastrointestinal stromal, pheochromocytoma, paraganglioma, thyroid
USP8 syndrome	USP8	Delayed development, dysmorphic features, lung
* Lynch syndrome	MLH1 PMS2	Colon, brain, uterine, pancreatic, ovarian, stomach, small intestine, gallbladder cut, urinary tract, sebaceous
* Neurofibromatosis ₁	NF1	Pheochromocytoma, neurofibromas, cafe-au-lait spots, iris Lisch nodules, skeletal abnormalities, learning disability, optic glioma, malignant peripheral nerve sheath tumor, leukemia, breast cancer, gastrointestinal stromal tumor, rhabdomyosarcoma
* Tuberous sclerosis	TSC2	Hamartoma, skin lesion, subependymal giant cell astrocytoma, cortical dysplasia, angiomyolipoma, developmental delay, rhabdomyoma, renal cysts, pneumocyte hyperplasia
* CDH23 syndrome	CDH23	Usher syndrome, deafness, vestibular dysfunction
* CABLES1 syndrome	CABLES1	Early onset Cushing disease

Fig. 3. Familial syndromes or germline mutations associated with pituitary adenoma. AIP, aryl hydrocarbon receptor-interacting protein; CDKN1B, cyclin dependent kinase inhibitor 1B; FIPA, familial isolated pituitary adenoma; HPGL/PCC, hereditary paraganglioma-pheochromocytoma; MAX, MYC Associated Factor X; MEN1/4, multiple endocrine neoplasia 1/4; NF1, neurofibromin 1; PRKAR1A, cAMP dependent protein kinase A (PKA) type I- α regulatory subunit (Ri α); SDH, succinate dehydrogenase; TSC2, tuberous sclerosis complex 2; USP8, ubiquitin specific peptidase 8. The asterisk (*) represents candidate genes for which additional data are needed.

to a single GH-secreting tumor, multiple tumors, or hypersecretion of normal pituitary gland surrounding a tumor [44]. For this reason, surgeons may need to pursue more aggressive resections, including sacrifice of the pituitary stalk, in Carney complex patients to cure the acromegaly. Evidence from pediatric patients with Cushing's disease also identified *CABLES1*, a regulator in adrenal-pituitary negative feedback, as a novel pituitary tumor-predisposing gene [45]. Lastly, screening in familial PA determined that 33% of families harbored cadherin-related 23 (*CDH23*) variants [46].

In X-linked acrogigantism (XLAG), a somatic or germline duplication in the *G protein-coupled receptor 1* (*GPR101*) gene leads to excess release of growth hormone and gigantism in the pediatric population that it affects [47]. Patients can develop either hyperplasia or PitNET, with

the most common subtype being a somatotroph/lactotroph mixed adenoma. Excess growth hormone and prolactin result in acceleration of linear growth early in life and hyperprolactinemia, respectively [47,48]. The duplication is inherited in an X-linked dominant fashion, so females who are heterozygous will also develop the pathology. Most often, XLAG arises from a *de novo* *GPR101* duplication and therefore only a single individual is affected; only three familial cases have been described [49]. Approximately 7.8 to 10% of patients with gigantism harbor this mutation [50]. Although PitNETs are often macroadenomas, they are less likely to invade locally or cause pituitary apoplexy than do the *AIP*-mutated somatotroph/lactotroph mixed macroadenomas [48]. While PitNETs should be treated with surgical resection as first-line therapy, pituitary hyperplasia may be controlled with GH receptor antagonist drugs [48,51].

Neurofibromatosis 1 is a syndrome characterized by changes in skin pigmentation and development of nerve sheath tumors. Its pathology is driven by a mutation in the *NF1* gene, which encodes for the tumor suppressor neurofibromin, and is either inherited in an autosomal dominant manner or results from a de novo mutation. Although central nervous system tumors (e.g., optic gliomas) are common, pituitary adenomas are very rarely associated with *NF-1* but there does not appear to be a clear link between the two [52]. Similarly, tuberous sclerosis and Lynch syndrome are two entities rarely associated with PitNETs, however, there is not a clear link to PitNET tumorigenesis. Further multiomic investigation is warranted to elucidate these relationships.

The “three PAs” is a new term describing the association between PitNETs, pheochromocytomas, and paragangliomas [53,54]. Although they may co-occur by coincidence, growing evidence suggests classical pheochromocytoma/paraganglioma-predisposing genes may also promote pituitary tumorigenesis. These tumor cells are driven by a mutated form of *succinate dehydrogenase*, an enzyme critical for cellular energy production, and mutations in any of the four genes encoding the SDH subunits (*SDHx*; *SDHA*, *SDHB*, *SDHC*, *SDHD*) are associated with the 3PAs [49,54]. Less frequently, other genetic causes of this association have been implicated, namely the MEN hereditary endocrine syndromes [55–58]. The PitNETs involved are commonly lactotrophs, somatotrophs, or non-functioning and represent more aggressive and treatment resistant tumors [58]. In a comprehensive review of patients with both PitNETs and pheochromocytoma/paraganglioma, the genetic screening was limited with nearly half of the patients not undergoing any testing, highlighting the need for comprehensive genome-wide analysis to ascertain association/causality [54].

6. Conclusions

The increased reliance on transcription factor characterization of PitNETs will likely add to current hormonal immunostaining and continue to be refined. Developing a better understanding of PitNET multiomics will be instrumental in improving our management of PitNETs that are refractory to our current gold-standard treatments. The multiomic approach will allow better patient classification, and prediction of prognosis.

Author contributions

NM, RDS, KP researched and wrote the paper. GP, JJE and MK edited the paper. All authors contributed to editorial changes in the paper. All authors read and approved the final paper.

Ethics approval and consent to participate

Not applicable.

Acknowledgment

We thank Kristin Kraus for her editorial assistance. [Biorender.com](https://www.biorender.com) was used for the drafting of Figs. 1,2,3 in this paper.

Funding

This research received no external funding.

Conflict of interest

The authors declare no conflict of interest.

References

- [1] Melmed S. Pituitary-Tumor Endocrinopathies. *New England Journal of Medicine*. 2020; 382: 937–950.
- [2] Raverot G, Jouanneau E, Trouillas J. Management of endocrine disease: Clinicopathological classification and molecular markers of pituitary tumours for personalized therapeutic strategies. *European Journal of Endocrinology*. 2014; 170: R121–R132.
- [3] Lopes MBS. The 2017 World Health Organization classification of tumors of the pituitary gland: a summary. *Acta Neuropathologica*. 2017; 134: 521–535.
- [4] Louis DN, Perry A, Wesseling P, Brat DJ, Cree IA, Figarella-Branger D, *et al.* The 2021 WHO Classification of Tumors of the Central Nervous System: a summary. *Neuro-Oncology*. 2021; 23: 1231–1251.
- [5] Trouillas J, Jaffrain-Rea ML, Vasiljevic A, Raverot G, Roncaroli F, Villa C. How to Classify the Pituitary Neuroendocrine Tumors (PitNET)s in 2020. *Cancers*. 2020; 12: 514.
- [6] Nishioka H, Inoshita N. New WHO classification of pituitary adenomas (4th edition): assessment of pituitary transcription factors and the prognostic histological factors. *Brain Tumor Pathology*. 2018; 35: 57–61.
- [7] Drummond JB, Ribeiro-Oliveira A Jr, Soares BS. Non-Functioning Pituitary Adenomas. 2000. Available at: <https://www.ncbi.nlm.nih.gov/books/NBK534880/> (Accessed: 12 August 2021).
- [8] Villa C, Vasiljevic A, Jaffrain-Rea ML, Ansorge O, Asioli S, Barresi V, *et al.* A standardised diagnostic approach to pituitary neuroendocrine tumours (PitNETs): a European Pituitary Pathology Group (EPPG) proposal. *Virchows Archiv*. 2019; 475: 687–692.
- [9] Nishioka H, Inoshita N, Sano T, Fukuhara N, Yamada S. Correlation between Histological Subtypes and MRI Findings in Clinically Nonfunctioning Pituitary Adenomas. *Endocrine Pathology*. 2012; 23: 151–156.
- [10] Erickson D, Scheithauer B, Atkinson J, Horvath E, Kovacs K, Lloyd RV, *et al.* Silent subtype 3 pituitary adenoma: a clinicopathologic analysis of the Mayo Clinic experience. *Clinical Endocrinology*. 2009; 71: 92–99.
- [11] Cooper O. Silent corticotroph adenomas. *Pituitary*. 2015; 18: 225–231.
- [12] George DH, Scheithauer BW, Kovacs K, Horvath E, Young WF, Lloyd RV, *et al.* Crooke’s Cell Adenoma of the Pituitary: an aggressive variant of corticotroph adenoma. *The American Journal of Surgical Pathology*. 2003; 27: 1330–1336.
- [13] Inomoto C, Tahara S, Oyama K, Kimura M, Matsuno A, Teramoto A, *et al.* Molecular, functional, and histopathological classification of the pituitary neuroendocrine neoplasms. *Brain Tumor Pathology*. 2021; 38: 183–188.
- [14] Drummond J, Roncaroli F, Grossman AB, Korbonits M. Clinical and Pathological Aspects of Silent Pituitary Adenomas. *The Journal of Clinical Endocrinology & Metabolism*. 2019; 104: 2473–2489.

- [15] Cakir M, Grossman AB. Targeting MAPK (Ras/ERK) and PI3K/Akt pathways in pituitary tumorigenesis. *Expert Opinion on Therapeutic Targets*. 2009; 13: 1121–1134.
- [16] Monsalves E, Juraschka K, Tateno T, Agnihotri S, Asa SL, Ezzat S, *et al*. The PI3K/AKT/mTOR pathway in the pathophysiology and treatment of pituitary adenomas. *Endocrine-Related Cancer*. 2014; 21: R331–R344.
- [17] Long R, Liu Z, Li J, Yu H. COL6a6 interacted with P4HA3 to suppress the growth and metastasis of pituitary adenoma via blocking PI3K-Akt pathway. *Aging*. 2019; 11: 8845–8859.
- [18] Duong CV, Emes RD, Wessely F, Yacub-Usman K, Clayton RN, Farrell WE. Quantitative, genome-wide analysis of the DNA methylome in sporadic pituitary adenomas. *Endocrine-Related Cancer*. 2012; 19: 805–816.
- [19] Kober P, Boresowicz J, Rusetska N, Maksymowicz M, Goryca K, Kunicki J, *et al*. DNA methylation profiling in nonfunctioning pituitary adenomas. *Molecular and Cellular Endocrinology*. 2018; 473: 194–204.
- [20] Taniguchi-Ponciano K, Andonegui-Elguera S, Peña-Martínez E, Silva-Román G, Vela-Patiño S, Gomez-Apo E, *et al*. Transcriptome and methylome analysis reveals three cellular origins of pituitary tumors. *Scientific Reports*. 2020; 10: 19373.
- [21] Malumbres M, Barbacid M. To cycle or not to cycle: a critical decision in cancer. *Nature Reviews Cancer*. 2001; 1: 222–231.
- [22] Chang M, Yang C, Bao X, Wang R. Genetic and Epigenetic Causes of Pituitary Adenomas. *Frontiers in Endocrinology*. 2021; 11: 596554.
- [23] Neou M, Villa C, Armignacco R, Jouinot A, Raffin-Sanson M, Septier A, *et al*. Pangenomic Classification of Pituitary Neuroendocrine Tumors. *Cancer Cell*. 2020; 37: 123–134.e5.
- [24] Nishioka H, Inoshita N, Mete O, Asa SL, Hayashi K, Takeshita A, *et al*. The Complementary Role of Transcription Factors in the Accurate Diagnosis of Clinically Nonfunctioning Pituitary Adenomas. *Endocrine Pathology*. 2015; 26: 349–355.
- [25] Mete O, Asa SL. Structure, Function, and Morphology in the Classification of Pituitary Neuroendocrine Tumors: the Importance of Routine Analysis of Pituitary Transcription Factors. *Endocrine Pathology*. 2020; 31: 330–336.
- [26] Hong SW, Kim SH, Lim SH, Lee EJ, Kim SH, Ku CR, *et al*. Clinical Relevance of New World Health Organization Classification System for Pituitary Adenomas: A Validation Study With 2-Year Experience. *Frontiers in Oncology*. 2021; 11: 739290.
- [27] García-Martínez A, Sottile J, Sánchez-Tejada L, Fajardo C, Cámara R, Lamas C, *et al*. DNA Methylation of Tumor Suppressor Genes in Pituitary Neuroendocrine Tumors. *The Journal of Clinical Endocrinology & Metabolism*. 2019; 104: 1272–1282.
- [28] Principe M, Chantal M, Ilie MD, Ziverec A, Vasiljevic A, Jouanneau E, *et al*. Immune Landscape of Pituitary Tumors Reveals Association between Macrophages and Gonadotroph Tumor Invasion. *The Journal of Clinical Endocrinology & Metabolism*. 2020; 105: 3459–3473.
- [29] Song Z, Reitman ZJ, Ma Z, Chen J, Zhang Q, Shou X, *et al*. The genome-wide mutational landscape of pituitary adenomas. *Cell Research*. 2016; 26: 1255–1259.
- [30] Albani A, Pérez-Rivas LG, Dimopoulou C, Zopp S, Colón-Bolea P, Roeber S, *et al*. The USP8 mutational status may predict long-term remission in patients with Cushing's disease. *Clinical Endocrinology*. 2018. (in press)
- [31] Salomon MP, Wang X, Marzese DM, Hsu SC, Nelson N, Zhang X, *et al*. The Epigenomic Landscape of Pituitary Adenomas Reveals Specific Alterations and Differentiates among Acromegaly, Cushing's Disease and Endocrine-Inactive Subtypes. *Clinical Cancer Research*. 2018; 24: 4126–4136.
- [32] Luo P, Zhang L, Yang L, An Z, Tan H. Progress in the Pathogenesis, Diagnosis, and Treatment of TSH-Secreting Pituitary Neuroendocrine Tumor. *Frontiers in Endocrinology*. 2020; 11: 580264.
- [33] Thakker RV, Newey PJ, Walls GV, Bilezikian J, Dralle H, Ebeling PR, *et al*. Clinical Practice Guidelines for Multiple Endocrine Neoplasia Type 1 (MEN1). *The Journal of Clinical Endocrinology & Metabolism*. 2012; 97: 2990–3011.
- [34] Thakker RV. Multiple endocrine neoplasia type 1 (MEN1) and type 4 (MEN4). *Molecular and Cellular Endocrinology*. 2014; 386: 2–15.
- [35] Bogusławska A, Korbonits M. Genetics of Acromegaly and Gigantism. *Journal of Clinical Medicine*. 2021; 10: 1377.
- [36] Delgrange E, Sassolas G, Perrin G, Jan M, Trouillas J. Clinical and histological correlations in prolactinomas, with special reference to bromocriptine resistance. *Acta Neurochirurgica*. 2005; 147: 751–758.
- [37] Schaller B. Gender-related differences in prolactinomas. A clinicopathological study. *Neuro Endocrinology Letters*. 2005; 26: 152–159.
- [38] Nishioka H, Haraoka J, Akada K, Azuma S. Gender-related differences in prolactin secretion in pituitary prolactinomas. *Neuroradiology*. 2002; 44: 407–410.
- [39] Holbrook L, Brady R. McCune Albright Syndrome. 2022. Available at: <https://www.ncbi.nlm.nih.gov/books/NBK537092/> (Accessed: 13 August 2021).
- [40] Salenave S, Boyce AM, Collins MT, Chanson P. Acromegaly and McCune-Albright Syndrome. *The Journal of Clinical Endocrinology & Metabolism*. 2014; 99: 1955–1969.
- [41] Kamilaris C, Faucz F, Voutetakis A, Stratakis C. Carney Complex. *Experimental and Clinical Endocrinology & Diabetes*. 2019; 127: 156–164.
- [42] Bertherat J, Horvath A, Groussin L, Grabar S, Boikos S, Cazabat L, *et al*. Mutations in Regulatory Subunit Type 1a of Cyclic Adenosine 5'-Monophosphate-Dependent Protein Kinase (PRKAR1a): Phenotype Analysis in 353 Patients and 80 Different Genotypes. *The Journal of Clinical Endocrinology & Metabolism*. 2009; 94: 2085–2091.
- [43] Forlino A, Vetro A, Garavelli L, Ciccone R, London E, Stratakis CA, *et al*. PRKACB and Carney Complex. *New England Journal of Medicine*. 2014; 370: 1065–1067.
- [44] Lonser RR, Mehta GU, Kindzelski BA, Ray-Chaudhury A, Vortmeyer AO, Dickerman R, *et al*. Surgical Management of Carney Complex–Associated Pituitary Pathology. *Neurosurgery*. 2017; 80: 780–786.
- [45] Hernández-Ramírez LC, Gam R, Valdés N, Lodish MB, Pankratz N, Balsalobre A, *et al*. Loss-of-function mutations in the CABLES1 gene are a novel cause of Cushing's disease. *Endocrine-Related Cancer*. 2017; 24: 379–392.
- [46] Zhang Q, Peng C, Song J, Zhang Y, Chen J, Song Z, *et al*. Germline Mutations in CDH23, Encoding Cadherin-Related 23, are Associated with both Familial and Sporadic Pituitary Adenomas. *The American Journal of Human Genetics*. 2017; 100: 817–823.
- [47] Iacovazzo D, Korbonits M. X-Linked Acrogigantism. 1993. Available at: <https://www.ncbi.nlm.nih.gov/books/NBK476671/> (Accessed: 14 August 2021).
- [48] Iacovazzo D, Caswell R, Bunce B, Jose S, Yuan B, Hernández-Ramírez LC, *et al*. Germline or somatic GPR101 duplication leads to X-linked acrogigantism: a clinic-pathological and genetic study. *Acta Neuropathologica Communications*. 2016; 4: 56.
- [49] Xekouki P, Szarek E, Bullova P, Giubellino A, Quezado M, Mastroyannis SA, *et al*. Pituitary Adenoma with Paraganglioma/Pheochromocytoma (3PitNETs) and Succinate Dehydrogenase Defects in Humans and Mice. *The Journal of Clinical Endocrinology & Metabolism*. 2015; 100: E710–E719.
- [50] Rostomyan L, Daly AF, Petrossians P, Nachev E, Lila AR, Lecoq A, *et al*. Clinical and genetic characterization of pituitary

- gigantism: an international collaborative study in 208 patients. *Endocrine-Related Cancer*. 2015; 22: 745–757.
- [51] Rodd C, Millette M, Iacovazzo D, Stiles CE, Barry S, Evanson J, *et al*. Somatic GPR101 Duplication Causing X-Linked Acro-gigantism (XLAG)-Diagnosis and Management. *The Journal of Clinical Endocrinology and Metabolism*. 2016; 101: 1927–1930.
- [52] Kurozumi K, Tabuchi A, Ono Y, Tamiya T, Ohmoto T, Furuta T, *et al*. Pituitary adenoma associated with neurofibromatosis type 1: case report. *No Shinkei Geka. Neurological Surgery*. 2002; 30: 741–745. (In Japanese)
- [53] Tatsi C, Stratakis CA. The Genetics of Pituitary Adenomas. *Journal of Clinical Medicine*. 2019; 9: 30.
- [54] O’Toole SM, Dénes J, Robledo M, Stratakis CA, Korbonits M. 15 YEARS of PARAGANGLIOMA: the association of pituitary adenomas and pheochromocytomas or paragangliomas. *Endocrine-Related Cancer*. 2015; 22: T105–T122.
- [55] Daly AF, Castermans E, Oudijk L, Guitelman MA, Beckers P, Potorac I, *et al*. Pheochromocytomas and pituitary adenomas in three patients with MAX exon deletions. *Endocrine-Related Cancer*. 2018; 25: L37–L42.
- [56] Dénes J, Swords F, Rattenberry E, Stals K, Owens M, Cranston T, *et al*. Heterogeneous Genetic Background of the Association of Pheochromocytoma/Paraganglioma and Pituitary Adenoma: Results from a Large Patient Cohort. *The Journal of Clinical Endocrinology & Metabolism*. 2015; 100: E531–E541.
- [57] Dwight T, Mann K, Benn DE, Robinson BG, McKelvie P, Gill AJ, *et al*. Familial SDHA Mutation Associated with Pituitary Adenoma and Pheochromocytoma/Paraganglioma. *The Journal of Clinical Endocrinology & Metabolism*. 2013; 98: E1103–E1108.
- [58] Guerrero-Pérez F, Fajardo C, Torres Vela E, Giménez-Palop O, Lisbona Gil A, Martín T, *et al*. 3P association (3PitNETs): Pituitary adenoma and pheochromocytoma/paraganglioma. A heterogeneous clinical syndrome associated with different gene mutations. *European Journal of Internal Medicine*. 2019; 69: 14–19.