

Review

All-Inside Anterior Cruciate Ligament Reconstruction: A Review of Advance and Trends

Yun-tao Yang¹, Zi-jun Cai¹, Miao He¹, Di Liu¹, Wen-qing Xie¹, Yu-sheng Li^{1,2,*},
Wen-feng Xiao^{1,2,*}

¹Department of Orthopaedics, Xiangya Hospital of Central South University, 410008 Changsha, Hunan, China

²National Clinical Research Center for Geriatric Disorders, Xiangya Hospital, Central South University, 410008 Changsha, Hunan, China

*Correspondence: liyusheng@csu.edu.cn (Yu-sheng Li); xiaowenfeng@csu.edu.cn (Wen-feng Xiao)

Academic Editors: Emerito Carlos Rodriguez-Merchan and Viviana di Giacomo

Submitted: 4 November 2021 Revised: 14 February 2022 Accepted: 23 February 2022 Published: 8 March 2022

Abstract

Anterior cruciate ligament (ACL) injury is a common disease in orthopedics and mostly occurs as a noncontact injury in athletes. Patients' knee joint stability, which is crucial to their athletic ability, cannot be restored through conservative treatment; it can only be restored through ACLR (ACL reconstruction) surgery. The surgical techniques of ACLR are constantly evolving, from bone tendon bone (BTB) grafting combined with interface screw fixation to hamstring tendon autograft or allogeneic tendon and of suspension device constructs. In particular, the currently prevalent all-inside technique featuring good cosmetic results and quick recovery of early functions not only ensures the stable fixation of grafts but also reduces surgical trauma. This review compares the advantages and disadvantages of different aspects of all-inside ACLR, including graft selection and preparation, bone socket reconstruction, fixation methods, and surgical technique effects and limitations. It has been found that the all-inside technique excels both anatomically and clinically but still requires further development. Besides, it has some limitations, and high-quality randomized controlled trials are still required to compare the long-term effects of the all-inside technique and other ACLR techniques.

Keywords: ACL reconstruction; all-inside; ACL

1. Introduction

As a crucial stabilizer of the knee joint, the ACL maintains antero-posterior and rotational stability of the knee joint by functioning as a primary passive constraint on the anterior movement of the tibia and a secondary constraint on the varus and valgus of the knee joint [1,2]. ACL consists of an anteromedial (AM) bundle and posterolateral (PL) bundle, which work together in the flexion and extension of the knee. The AM bundle contracts when the knee is flexed, and the PL bundle contracts when the knee is extended. ACL rupture can lead to anterior, posterior and rotational instability of the knee joint and can increase the risk of meniscus injury and early knee joint degeneration [3]. The annual incidence of ACL injury in the United States is 1/3000, which results in more than 175,000 cases of acute knee injury each year and more than 100,000 operations in the past decade [4]. At the same level of activity, the risk of ACL injury in women is 4 times higher than that in men [5].

The treatment of ACL injury has been constantly developing. Historically, the surgical treatment of ACL rupture has evolved from open repair to open reconstruction, to the arthroscopic "2-incision" technique, and then to the "single incision" under arthroscopy or the all-inside technique [2,6]. At present, ACLR has been identified as the gold standard for the treatment of active, symptomatic complete rupture of ACL [7]. Due to the thin synovium and

intra-articular position, ACL injury has a poor ability to spontaneously repair and remodel. Early reports of direct suture repair of the ACL showed that 40% to 100% of cases ended in failure [8]. With the development of surgical techniques and devices, primary repair of acute ACL proximal tears with intact tibial remnants has attracted interest [9–12]. Although primary repair has advantages, it is not suitable for all types of ACL rupture [13]. In addition, the stability of patients' knee joints cannot be restored through conservative treatment, so surgeons tend to perform ACLR to restore knee stability once a rupture occurs.

The success of ACLR depends on long-term factors, including biological factors, mechanical factors and rehabilitation factors, while the short-term outcome of the operation depends on whether the graft can restore the restraint of the ACL as well as the normal kinematic function of the knee joint [3].

This study reviewed the existing literature on all-inside ACL reconstruction, including aspects of graft selection and preparation, construction of bone sockets, fixation methods, surgical techniques and effects and limitations. Our aim was to present a provider reference for clinical treatment and decision-making for patients with ACL injury.



Table 1. Comparison of different graft types.

Graft types	Advantages	Shortcomings
Bone patellar tendon Bone (BTB)	High stability of osteogenic connection [27].	Donor site complications [18]; Anterior patellar or kneeling pain [18].
Allograft	Fit for multiple ligament injury and revision surgery [21].	High risk of retear [19,20]; Slow healing of tendon and bone [28].
Hamstring tendon (HT)	Retain the functional structure of knee extension; Fewer postoperative complications [22].	Saphenous nerve injury; Tendon rupture during graft harvest;
Quadriceps tendon	Large graft size [25,26].	Reduce knee flexion strength [23,24]. Suprapatellar bursa injury [25,26].

2. Introduction of the All-Inside Technique

In 1995, Morgan *et al.* [14] first described an ACLR technique called “all-inside”, which is a technique that requires only the entrance of the arthroscope but not the incision of the femur or tibia when performing surgery using allogeneic tissue. Therefore, this represents a “nonincisional” ACLR technique [14]. In 1997, Stähelin and Weiler published an improved all-inside technique in which the tibial tunnel was made from inside-out and both ends of the graft were fixed with interface screws. The major reasons why it has not been put into use on a wide scale are that it has high technical requirements on the one hand and that the fixed flexion angle of the graft is non-anatomic on the other hand [15]. In 2006, Lubowitz *et al.* [6] described an all-inside ACLR method using nonincisional techniques in which a femoral tunnel was drilled through the tibia, but later they found that there were anatomical risk factors for the posterior tibial tunnel and the high and anteromedial position of the femoral tunnel. Subsequent studies have shown that the standard method of drilling through the tibia may lead to burst fractures of the proximal tibial tunnel, which may reduce the strength of graft fixation, reduce tendon contact, and increase synovial fluid leakage, thereby leading to dilatation of the bone tunnel. However, the use of inverted drilling to create the tibial tunnel can effectively avoid this complication [16]. As a result, Lubowitz *et al.* [17] improved this technique in 2011 and presented a second-generation all-inside ACLR technique. What makes this improved technique different from previous techniques is the use of an outside-in approach to construct the femoral socket, the use of 4-stranded grafts, second-generation flip-cutter inverted drilling, and the use of an adjustable loop cortical suspension device for fixation of both the femoral and tibial ends [17].

This article reviews the advantages and shortcomings of the existing techniques related to all-inside ACLR from the aspects of graft types, fixation methods and bone socket construction and the limitations of the all-inside technique (Fig. 1; Table 1, Ref. [18–28]; Table 2, Ref. [2,21,29–32]; Table 3, Ref. [6,16,17,33–36]; Table 4, Ref. [6,17,21,29,34]).

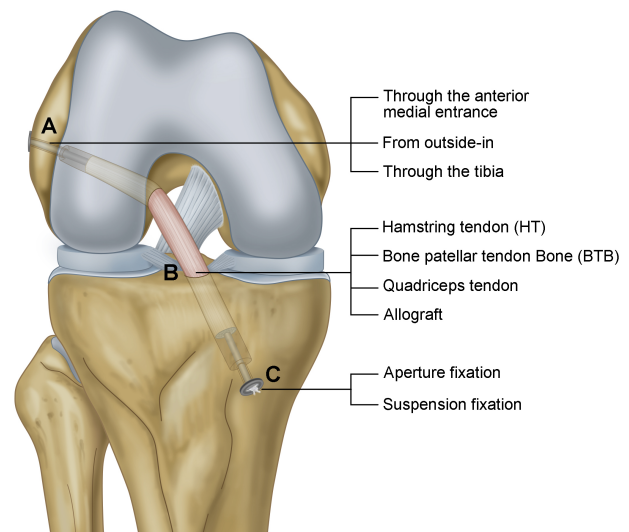


Fig. 1. All-inside ACL reconstruction. (A) Construction of the femoral bone tunnel. (B) Graft types. (C) Fixing modes.

3. Characteristics and Advantages of the All-Inside Technique

The all-inside technique is an advantageous ACLR technique that can preserve the gracilis muscle, reduce muscle strength loss of affected limbs, and reduce the risk of knee joint instability under rotational load [29,37]. Studies have shown that preservation of the gracilis muscle is essential for postoperative rehabilitation, especially for patients with a high demand for knee joint movement [38]. Another 2-year prospective follow-up study included the enrolment of 90 patients, and confirmed that the strength of high-angle knee flexion after operation was significantly higher than that of semitendinosus and gracilis muscle alone [3]. In addition, the all-inside technique can be used to preserve bone mass and maintain the integrity of the cortical bone. The preservation of the epiphysis is of great significance for patients with immature bone ACLR, and the preservation of the periosteum can reduce pain during the postoperative period [1,39]. An 8-year follow-up study of 24 adolescents showed satisfactory results for all-inside ACLR procedures [40]. Another advantage of the all-inside technique is the small incision of the tibia, which can reduce the incidence

Table 2. Comparison of different fixation methods.

Fixation methods	Advantages	Shortcomings
Aperture fixation	Lower elongation and larger pullout stiffness [31].	Synovial fluid leak; Enlargement of bone socket [29,30].
Suspension fixation	Higher ultimate loads [31]; Recovery of footprint anatomical structure [2,32].	“Wiper effect” and “bungee effect”, “Graft loosening” [21].

Table 3. Comparison of different drilling methods on the femoral side.

Construction of femoral bone tunnel	Advantages	Shortcomings
Through the anterior medial entrance	Accord with the anatomical structure [17]; Strong stability of graft [36].	Short bone tunnel; Peroneal nerve injury; Lactogenic cartilage injury; Long learning curve [34].
From outside-in	Longer bone tunnel; simplify operation [33,35].	Difficult to control inside outlet position [33,35].
Through the tibia	Short learning curve [34].	Anatomical risk factors [6]; Burst fractures of the proximal tibial tunnel [16].

of complications such as tibial plateau fractures [4], while a smaller bone socket helps to maintain bone reserves and perform multiple ligament reconstruction or revision during the postoperative period [1,3]. Smaller surgical injuries also allow this technique to be combined with other operations, such as high tibial osteotomy or ACL-PCL (Posterior cruciate ligament) combined with reconstruction [41].

4. Surgical Technique

It mainly consists of six steps.

The first step is the preparation of the patient. The patient generally takes the supine position after general anaesthesia or nerve block anaesthesia and fully exposes both lower limbs.

The second step is graft harvest. The authors prefer to use the semitendinosus muscle as a graft. A standard tibial incision of approximately 1.5–2 cm is usually made between the tibial tubercle and the medial edge of the tibia (Fig. 2A). The tendons are identified under the sartorius fascia, and the semitendinosus and gracilis are separated and stripped with a tendon remover. When the semitendinosus is short or less than three times in diameter (less than 7.5 mm), the gracilis can be harvested [3,17].

The third step is the graft preparation process (Fig. 2B). The harvested tendons are woven and sutured into 2, 3 or 4 strands depending on their diameters, and the ends are suspended on the titanium plate of the locking band loop connected with high-strength sutures and placed on the graft preparation table for pretensioning. The tension is set to approximately 40 N. A buried knot is a technique that means on completion of the suture noose, the final stitch from peripheral to central, so there is no knot on the graft surface [42]. Studies have shown that the use of the buried knot technique in graft preparation has a higher ultimate load and lower elongation than traditional continuous su-

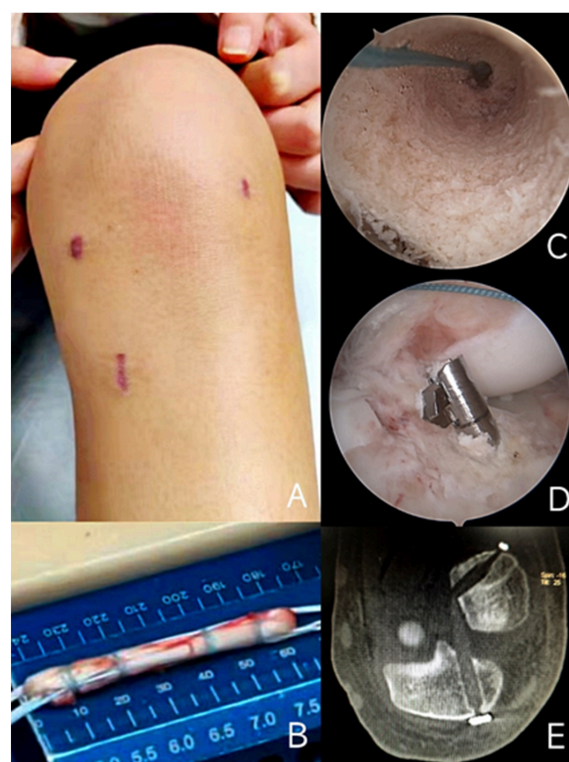


Fig. 2. Surgical technique. (A) The anteromedial and anterolateral portal and tibial incision. (B) Four strand tendon graft by using single semitendinosus muscle tendon. (C) The internal view of femoral bone socket. (D) The construction of tibial bone socket with flipcutter. (E) A postoperative CT show Bone tunnel and suspension device by using all-inside technique.

ture techniques and can provide better early knee joint stability [43]. Another biomechanical study showed that the commonly used end-to-end suture graft preparation technique has higher graft strength than the side-to-side suture

Table 4. Limitations of all-inside technique.

Tendon	The risk of graft “bottoming-out” during tensioning and fixation [6,17]
Fixing mode	Graft micro motions caused by suspension system [21]
Construction of bone tunnel	Destory the stump of ACL when use flipcutter [17,29]
Others	Long learning curve [34]

graft preparation technique, and whether secondary fixation is performed on the tibial button does not significantly affect the biomechanical properties of the graft [44].

The fourth step is the construction of the bone socket (Fig. 2C,D). The characteristic of the all-inside technique is to establish a bone socket rather than a complete bone tunnel (Fig. 2E), with preservation of the bone cortex and periosteum, so to tighten the graft, the graft cannot touch the bottom in the bone socket, and its length must be less than the sum of the femoral socket length, the intra-articular graft length and the tibial socket length [42]. Previous studies have demonstrated that when creating the femoral socket from outside-in, the guide pin should be 60° to the femoral anatomical axis and the transverse condylar Axis 20° to create a normal anatomical shape closest to the footprint area of the original ligament [45]. Some biomechanical studies have shown that the position of the femoral bone tunnel can also affect the postoperative stability of the knee joint [46–48]. A 2-year follow-up clinical cohort study involving 62 patients showed that a lower femoral tunnel position (10 or 2 o'clock) can obtain better internal rotation stability at 0° (10.3° vs. 12.0°; $p = 0.04$) and 30° (14.4° vs. 16.4°; $p = 0.02$) of knee flexion than a higher position (11 or 1 o'clock) [49].

The fifth step is the passage of the graft. The graft is usually introduced from the anterior medial portal of the arthroscope, and the use of a cannula can effectively prevent soft tissue insertion [17].

The last step is the fixation of the graft (Fig. 2E). The commonly used fixation methods include locking titanium plate suspension fixation or aperture fixation using interface screws. The authors prefer to tighten the femoral loop at 90 degrees of knee flexion and then fix the tibial loop in an extended position to avoid the difficulty of knee extension caused by grafts tendons that are relative tight.

5. Selection and Preparation of Grafts

At present, the commonly used grafts include bone-tendon-bone (BTB) autografts, hamstring tendon (HT) autografts, quadriceps tendon autografts, and allografts, and each has distinct advantages and disadvantages. BTB grafts have more complications in the donor site, but they have good graft stability and motor function recovery after operation [18]. However, allografts have a higher risk of retear [19,20], which may be due to the poor strength of grafts after undergoing the sterilization process, but it is of great value in the case of multiple ligament injury and revision surgery [21]. At present, an increasing number of surgeons

choose autologous hamstring tendons as grafts for ACLR because they retain the functional structure of knee extension compared with traditional patellar tendon grafts, have fewer postoperative complications of autologous patellar tendon autografts, such as patellofemoral pain, patellar tendonitis and quadriceps weakness, have a lower incidence [3,30,41] and have a significantly better effect in mitigating the pain at the donor site [22]. However, HT grafts also have the risk of saphenous nerve injury in the tendon area, tendon rupture during graft harvest, and early postoperative rupture of the graft [23,24]. Quadriceps tendon autografts have a sufficient graft size to provide better knee flexion strength than the HT graft and has a lower risk of anterior knee pain than the BTB graft, but it has the risk of donor site complications such as quadriceps tendinopathy and possible injury to the suprapatellar bursa [25,26]. In a recent study, ACLR was performed in athletes under 24 years old, and autologous patellar tendon and all-inside quadruple semitendinosus muscle grafts were used. At the 2-year follow-up, the results of side-to-side laxity measured by KT-1000 showed no significant difference between the two groups (BPTB: 0.0 ± 0.8 mm vs. AIST: 0.3 ± 0.7 mm, $p = 0.197$), but the postoperative pain in the all-inside semitendinosus group was less than that in the BTB group at Days 2 ($p = 0.049$), 3 ($p = 0.004$), and 7 ($p = 0.015$) and was significantly different at 2 years ($p < 0.019$) [50]. Some studies suggest that the risk of anterior knee pain and degeneration after BTB reconstruction is higher than that of HT grafts, while the risk of graft relaxation and reduced knee flexion strength after HT reconstruction is higher [18,51–57]. With the advantages of a short operation time and less postoperative pain, allografts are also used in ACLR, but it remains controversial because several studies have shown that they can produce good results, but more studies have shown that they have a high failure rate, especially in young patients [20]. Biological studies have shown that the speed of revascularization and reconstruction of allografts is slow [58]. Maletis *et al.* [59] found that the revision risk of allografts was 3.02 times higher than that of BTB grafts, and the postoperative revision risk of autologous HT grafts was 1.82 times higher than that of BTB grafts; they further found that the revision risk decreased by 7% with age.

Traditional 4-strand grafts have good biomechanical properties, but when the tendon length or width is not large enough, other construction methods can also be used to ensure sufficient strength of the graft [60–62]. A study showed that anastomosis of 4-strand (699.89 ± 196.73 N), 3-strand (576.20 ± 173.64 N), and loop-and-track 4-strand

grafts (769.67 ± 151.89 N) do not biomechanically differ in ultimate force from traditional 4-strand grafts (778.84 ± 176.11 N) [60]. Another biomechanical study on the graft preparation technique by Colter *et al.* [61] also found that a 4-strand single tendon graft was preferred for all-inside reconstruction of the ACL, while the 3-strand single tendon technique was preferred when the tendon length was insufficient, and the 2-strand technique (2 tendons) had a much Cyclic displacement (After preloading and cyclic loading occurred for 500 loading cycles from 50 to 250 N at 1.0 Hz, the final extension length of the graft) than the other groups, so the last technique is not recommended for all-inside reconstruction of the ACL. Another biomechanical study using bovine digital extensor tendon as material also showed a significantly better ultimate failure load of the “triple” graft (650.70 N, $p = 0.007$) and the “quadrupled” graft (767.02 N, $p = 0.014$) compared to the “half-quadrupled” configuration (513.35 N). Therefore, it could be better to use the “triple” graft instead of the “half-quadrupled” graft when the tendon is inadequate [62].

Recently, Daniel *et al.* [63] found that the length and diameter of 4-strand grafts can be accurately predicted according to the length and width of the harvested semitendinosus muscle in all-inside reconstruction ACL operations, and such a relationship is also applicable to allografts. Joseph *et al.* [64] also proposed that the graft diameter can be predicted by preoperative MRI measurement of semitendinosus length and cross-sectional area and found that there was a high correlation between cross-sectional area and graft diameter. The average diameter of the natural ACL is 11 mm, and regardless of the type of graft, small grafts can increase the risk of failure. Studies have found that a graft diameter smaller than 8 mm significantly increases the risk of failure [24,63,65–67]. Spragg *et al.* [68] also proposed that from 7 mm to 9 mm, every 0.5 mm increase in graft diameter reduced the likelihood of re-tear by 0.82 times.

6. Selection of Fixation Methods

The commonly used fixation methods of all-inside ACL reconstruction are interface screw fixation or aperture fixation (reverse interface screw fixation) and suspension fixation of an adjustable loop or a nonadjustable loop, including femoral end and tibial end fixation. A number of studies have reported the comparability of different femoral fixation methods in restoring the kinematics of the knee joint, and tibial fixation is the current research focus [69]. Studies have shown that the failure of ACLR and fixation most often occurs in the tibial socket, which may be because the tibial bone mineral density is lower than that of the femur and the angle between the tibial socket and the intra-articular graft is more collinear than that between the femoral socket and the graft, which makes the axial force of the tibia-graft interface greater [70]. The adjustable loop avoids the complications of interface screws, better

fills the bone socket, and reduces graft activity and synovial fluid leakage into the bone socket [29,30]. A recent meta-analysis comparing suspension fixation with aperture fixation found that suspension fixation had more advantages in lateral differences and postoperative graft re-tear [1]. Another biomechanical study showed that interface screw fixation had lower elongation and larger pullout stiffness, but suspension fixation can withstand higher ultimate loads [31]. Some studies suggest that the biomechanical effect of suspension fixation is worse than that of aperture fixation, and there may be a “wiper effect” [71]. Lubowitz *et al.* [32] conducted a clinical randomized controlled trial comparing all-inside reconstruction ACL suspension fixation with aperture fixation, and the results showed that there was no significant difference between the two methods in the stability of the knee joint before and after the operation. Aperture fixation is closer to the articular surface level than suspension fixation, which can reduce the “wiper effect” and “bungee effect”. However, suspension fixation also has theoretical advantages. For example, it can produce more ACL footprint coverage area, which is beneficial to the recovery of footprint anatomical structure [2,32]. The initial strength of any graft is determined by its weakest link, and the weakest link in the all-inside graft structure is the strength of the initial fixation, that is, the suture used for suspension fixation [61]. Carlos M. Barrera *et al.* [72] proposed that binding the medial bundle limb suture to the tibial suspension button in a single tendon 4-strand all-inside ACLR can prolong the 0-load failure time and reduce the graft elongation rate.

With regard to suspension fixation, the first-generation cortical suspension button is a fixed length graft loop, while the second-generation button has an adjustable length graft loop so that after the button is flipped and fixed to the cortex, the graft loop can be tightened to pull the graft into the bone socket in a way that completely fills the bone socket. In addition, the first-generation cortical suspension button is designed for femoral fixation, while the second-generation adjustable graft button is effective for tibial (and femoral) fixation. In this way, when the graft loop is tightened, the graft tension increases, so the surgeon can increase the graft tension after the graft is fixed [17]. In a recently published clinical study, 188 patients were randomly assigned to the femoral side to perform standard ACLR of 4-strand autologous hamstring tendon grafts using an adjustable loop or an adjustable loop device. During the two-year follow-up visits, there was no significant difference in KT-1000 results, graft failure rate or graft failure time between the two groups [73].

7. Construction of the Bone Socket

The common ways to construct the bone socket include creating the bone socket through the anterior medial entrance, creating the bone socket from the outside in, and creating the bone socket through the tibia. Whichever

technique is involved, the construction of the bone socket is based on the understanding of ACL footprints and the evaluation of ruptured ACL scar tissue by biological and anatomical methods under arthroscopy. The all-inside technique, which uses bone sockets to replace the total bone tunnel, retains bone mass and reduces graft movement and synovial fluid leakage [29], while a higher graft failure rate is observed in the total tibial tunnel [74]. Carlos Noronha *et al.* [29] proposed a tibial tunnel drilling technique. Even if the flexible ream is used to drill the tunnel from inside-out, an inverted drilling aiming device is not required, which reduces operation cost. However, it has limitations: the broken stump of the ACL cannot be retained, which may influence its proprioception and revascularization. Alcindo Silva *et al.* [30] described a surgical method in which 4-strand semitendinosus were used as grafts, cortical button was used instead of traditional interface screw fixation, and a complete tibial tunnel without cortical preservation was constructed, which was filled with bone dowel after operation to maintain the integrity of bone mass and prevent further expansion of the tunnel. This technique has the virtues of the all-inside technique and has a short learning curve. It is known that there are anatomical risk factors in the construction of the femoral socket through the tibia, and failure to return to normal knee joint kinematics may also lead to early-onset osteoarthritis [33]. Therefore, some scholars have proposed creating the femoral bone socket through the anterior medial entrance, but this technique also has potential defects. For example, when the knee joint is in the excessive flexion position, it is easy to cause the bone socket to rupture or it is difficult to see the position of the guide pin, and the length of the femoral socket created through the anterior medial entrance is shorter, which can shorten the graft in the bone socket. In addition, the technique of anterior medial entrance also has potential risks, such as peroneal nerve injury, iatrogenic cartilage injury or guide slips out and a long learning curve [34]. Researchers later proposed a technique that creates the femoral bone socket from outside-in, which makes up for the defect of the previous technique, and all surgical operations can be completed at the position of 90° flexion of the knee joint without additional medial entrance, and a longer anatomical femoral socket can be constructed [33,35]. However, some studies have found that with the increase in the flexion angle of the knee joint, the length of the femoral bone socket constructed through the anterior medial entrance increases, and the risk of neurovascular injury decreases [35,75]. In addition, some studies indicate that a larger flexion angle is not better when the femoral bone socket is constructed through the anterior medial entrance, and excessive flexion can increase the contact pressure between the bone socket and the graft [76]. The goal of anatomical ACLR is to place the graft in the natural ACL implantation site of the tibia and femur. As a result, the position of the femoral bone socket has evolved from a nonanatomical position at the height of

the incisure to a lower position towards a more horizontal position, and some researchers have suggested that more horizontally oriented grafts can optimize the rotation and translation stability of the knee joint [46,49,77,78]. A large sample control study based on the Danish knee ligament reconstruction register (DKRR) showed that the operation of constructing the femoral socket through the anterior medial entrance can lead to a higher rate of postoperative ligament revision than the operation of constructing the femoral socket through the tibia, which may be due to the greater strength of the grafts reconstructed by anatomical ACL; thus, it has a higher risk of graft failure [79]. More studies have shown that the construction of the femoral socket through the anteromedial entrance has better postoperative rotational stability and anterior and posterior stability than that through the tibia [36].

8. Surgical Effect of All-Inside ACL Reconstruction

A number of studies have shown that patients with all-inside reconstruction of the ACL have good knee joint stability and lower pain scores [37,50,80–82] in the early and middle stages after the operation, which may be because the all-inside technique retains the periosteum. A randomized controlled clinical trial of all-inside ACLR in comparison with traditional total tibial tunnel reconstruction showed that the VAS score of total cruciate ligament reconstruction was significantly lower than that of baseline in the early stage and 2 years postoperatively, which was statistically significant [80]. The all-inside technique also has a good surgical effect in the medium-term postoperative period, and it is more suitable for treating young patients due to its low invasiveness [81]. Another randomized controlled trial confirmed that there was no significant difference in postoperative effect and knee joint stability between all-inside 4-strand semitendinosus ACLR and autologous patellar tendon BTBP graft ACLR [50]. Chun-Wei Fu *et al.* [83] evaluated 5 randomized controlled trials and 4 cohort studies through meta-analysis and concluded that the ACLR method of all-inside cortical suspension fixation was not superior to the all-tibial tunnel technique in terms of clinical effect and knee joint stability. However, the all-inside technique also has the advantages of a larger graft diameter and less enlargement of the tibial socket [83]. A randomized controlled trial conducted by Raul Mayr *et al.* [84] also showed that the all-inside technique with button fixation had less enlargement of the tibial socket than the traditional technique with interface screw fixation, while enlargement of the bone socket may make it difficult to fix the graft during revision surgery or require a second operation, indicating that if revision surgery is to be performed, the need for phased revision of the all-inside technique is lower. Mark Schurz *et al.* [82] conducted a 24-month follow-up study on the postoperative function of patients with all-inside ACLR. The results showed that the function

of the operative side was significantly improved compared with the baseline, and there was no difference in the stability of the reconstructed ACL compared with the contralateral normal knee joint. Sam *et al.* [85] also conducted a 24-month follow-up study and concluded that lateral all-inside ACLR has good medium-term subjective and objective results, fewer complications and a lower failure rate. This technique can be used to construct a bone socket retrograde from inside-out by navigating around the lateral condyle of the femur using special instruments [80]. Many studies have shown that compared with the traditional ACLR technique, the clinical effect of all-inside ACLR has no significant difference in long-term follow-up, but the early VAS pain score is lower [41,80,86]. However, some studies suggest that all-inside reconstruction may lead to a higher graft failure rate [82], but its clinical significance is doubtful. Due to the closed bone socket design of the all-inside technique, the enlargement of the bone socket can be avoided to some extent, and tibial microfracture injury can be attenuated compared with the standard total tibial tunnel ACLR [16].

In addition, important factors for rehabilitation after ACLR include the strength of the graft, the healing rate of tendon bone, the change in mechanical properties of the graft over time and the strain imposed on the graft during rehabilitation [2]; ACLR reduces the possibility of OA, but the development of OA may be aggravated if patients return to exercise after operation [21].

9. Limitations of the All-Inside Technique

9.1 Tendon

The all-inside technique using autologous semitendinosus and gracilis grafts can reduce the internal rotation strength of the tibia of the operated limb to a certain extent, thus affecting the patient's motor ability [30]. Compared with the BTB graft, there is a lack of interosseous healing between the autologous semitendinosus and the bone socket, which makes it impossible to form a similar stable osseous connection [3]. In addition, in some cases, the length of the graft may not be enough to require additional tendon harvest, although it has been reported that the semitendinosus length of most people is more than 28 cm, while the length of the femoral tunnel and tibial tunnel is 10–15 mm and 15–20 mm, respectively, which meets the conditions for graft healing [29]. However, some have also suggested that the minimum length of the graft in the bone socket should be greater than 15 mm to achieve satisfactory tendon-bone healing in the early stage [63]. When the semitendinosus muscle is not long enough or ruptured, the ipsilateral gracilis muscle can be harvested and made into a graft to achieve the required length and diameter [57], which avoids graft instability and graft failure caused by touching the bottom [63]. The small diameter of the graft is also a risk factor for postoperative retear. Grawe *et al.* [23] found that when the total cross-sectional area of the com-

bined graft (semitendinosus plus gracilis) is larger than 22 mm², it can provide a graft effective diameter larger than 8 mm during surgery. They also found that young age, short stature, young age and female sex are risk factors for developing high-risk grafts with a diameter smaller than 8 mm [87]. A recent systematic review showed that the risk of failure corresponding to a diameter of autologous tendon grafts less than 8 mm was 6.8 times higher than that of the control group [23].

9.2 Fixing Mode

The use of a titanium plate can lead to the “bungee effect” (graft axial expansion along the bone socket) and the “windshield wiper effect” (graft perpendicular to the tunnel swinging like wipers), which affect bone tendon healing and are also the primary mechanical factors leading to bone socket enlargement [21]. Bressy G *et al.* [88] reported that all-inside reconstruction grafts with adjustable loop fixators at both ends have poor stability in the early stages of healing. Due to the characteristics of the adjustable loop of the suspension fixation device, the loop ring may lengthen, and the graft may loosen after the tension and cyclic load of the graft [89,90]. Yavuz Kocabey *et al.* [1] proposed a technique to change the femoral end fixation device from an adjustable loop to a fixed loop, which can prevent the graft from loosening to a certain extent.

9.3 Construction of the Bone Tunnel

When an adjustable loop is used in the all-inside technique, the bone socket is made larger to facilitate tendon implantation; when a flip cutter is used for drilling the bone socket, inevitable damage can be caused to the stump of the tendon, and the proprioceptive sensation in that area can be destroyed to some extent, so it is not recommended to use this technique when retaining the stump for reconstruction.

10. Discussion

Although it is difficult to anticipate the future, historically, sports medicine and arthroscopy are developing to be increasingly less invasive. With the advantages of less trauma (only semitendinosus muscle or allogeneic tendon), less early pain (preservation of bone cortex and periosteum), and reliable fixation effect, the All-inside technique has become an increasingly popular approach of ACLR, but it also has limitations such as a long learning curve and affects proprioception and vascularization since it is unfit for reconstruction through stump preservation, and titanium plates may lead to bone tunnel enlargement and graft loosening.

Compared with traditional manoeuvres, the author becomes increasingly likely to use the all-inside technique for the reconstruction of the ACL, which causes less damage to the epiphysis, and taking a single tendon has less influence on flexion muscle strength. This is especially true for teenagers or athletes. For tendons, the all-inside technique

combined with the Graftlink technique allows a graft of sufficient diameter from only a single semitendinosus tendon, and it is very advantageous to use hamstring tendon autografts for economic cost and postoperative recovery. The key to the operation is the creation of a bone socket. From the perspective of learning curves, the creation of the femoral bone socket from the inside out through the antero-medial entrance requires maintaining an extreme flexion position of the knee joint, which has specific requirements for the operation depending on the surgeon, while the operation of creating the femoral bone socket from the outside in is relatively convenient and can avoid damage to the ACL stump. Therefore, the author recommends more outside-in access to create the femoral bone socket under ambiguous conditions. In terms of fixation, the all-inside technique uses adjustable loops, which can retain the bone cortex and reduce postoperative pain while ensuring the strength of the fixation, so it has more advantages than traditional aperture fixation.

11. Conclusions

The all-inside technique excels both anatomically and clinically but still requires further development. It has some limitations, and high-quality randomized controlled trials are still required to compare the long-term effects of the all-inside technique and other ACLR techniques.

Author Contributions

YTY drafted the manuscript. YSL and WFX designed the study. ZJC and MH critically revised the manuscript. DL and WQX drew the figures and tables, All authors commented on and approved the manuscript.

Ethics Approval and Consent to Participate

Not applicable.

Acknowledgment

Not applicable.

Funding

This work was supported by National Natural Science Foundation of China (No.81874030, 82072506), National Key R&D Program of China (2019YFA0111900), National Clinical Research Center for Geriatric Disorders (Xiangya Hospital, Grant No. 2021KFJJ02), National Clinical Research Center for Orthopedics, Sports Medicine and Rehabilitation (2021-NCRC-CXJJ-PY-40), Science and Technology Innovation Program of Hunan Province (No.2021RC3025), Provincial Natural Science Foundation of Hunan (No.2020JJ3060), Provincial Clinical Medical Technology Innovation Project of Hunan (No.2020SK53709), the Administration of Traditional Chinese Medicine of Hunan Province (No.2021075), Innovation-Driven Project of Central South university

(No.2020CX045), Wu Jieping Medical Foundation (320.6750.2020-03-14), CMA - Young and Middle-aged Doctors Outstanding Development Program-Osteoporosis Specialized Scientific Research Fund Project (G-X-2019-1107-12) and the Independent Exploration and Innovation Project for Postgraduate Students of Central South University (No.2021zzts1024, 2021zzts1030, 2021zzts1037).

Conflict of Interest

The authors declare no conflict of interest. YSL is serving as the guest editor of this journal. We declare that YSL had no involvement in the peer review of this article and has no access to information regarding its peer review. Full responsibility for the editorial process for this article was delegated to Emerito Carlos Rodriguez-Merchan and Viviana di Giacomo.

References

- [1] Kocabay Y, Yalçın S, Erdil M, Polat G. An Alternative Femoral Fixation in all-inside Anterior Cruciate Ligament Reconstruction: A Solution for Preventing Possible Graft Loosening. *Arthroscopy Techniques*. 2019; 8: e861–e865.
- [2] Bradley JP, Tejwani SG. All-inside patellar tendon anterior cruciate ligament reconstruction. *Sports Medicine and Arthroscopy Review*. 2009; 17: 252–258.
- [3] Kouloumentas P, Kavroudakis E, Charalampidis E, Kavroudakis D, Triantafyllopoulos GK. Superior knee flexor strength at 2 years with all-inside short-graft anterior cruciate ligament reconstruction vs a conventional hamstring technique. *Knee Surgery, Sports Traumatology, Arthroscopy*. 2019; 27: 3592–3598.
- [4] de Sa D, Shanmugaraj A, Weidman M, Peterson DC, Simunovic N, Musahl V, *et al.* All-inside Anterior Cruciate Ligament Reconstruction-A Systematic Review of Techniques, Outcomes, and Complications. *The Journal of Knee Surgery*. 2018; 31: 895–904.
- [5] Gwinn DE, Wilckens JH, McDevitt ER, Ross G, Kao TC. The relative incidence of anterior cruciate ligament injury in men and women at the United States Naval Academy. *American Journal of Sports Medicine*. 2000; 28: 98–102.
- [6] Lubowitz JH. No-tunnel anterior cruciate ligament reconstruction: the transtibial all-inside technique. *Arthroscopy*. 2006; 22: 900.e1–900.e11.
- [7] Dallo I, Chahla J, Mitchell JJ, Pascual-Garrido C, Feagin JA, LaPrade RF. Biologic Approaches for the Treatment of Partial Tears of the Anterior Cruciate Ligament: A Current Concepts Review. *Orthopaedic Journal of Sports Medicine*. 2017; 5: 2325967116681724.
- [8] Strand T, Mølster A, Hordvik M, Krukhaug Y. Long-term follow-up after primary repair of the anterior cruciate ligament: clinical and radiological evaluation 15–23 years postoperatively. *Archives of Orthopaedic and Trauma Surgery*. 2005; 125: 217–221.
- [9] Monaco E, Mazza D, Daggett M, Marzilli F, Annibaldi A, Carrozzo A, *et al.* Acute Primary Repair of the Anterior Cruciate Ligament With Anterolateral Ligament Augmentation. *Arthroscopy Techniques*. 2021; 10: e1633–e1639.
- [10] Hopper GP, Aithie JMS, Jenkins JM, Wilson WT, Mackay GM. Combined Anterior Cruciate Ligament Repair and Anterolateral Ligament Internal Brace Augmentation: Minimum 2-Year Patient-Reported Outcome Measures. *Orthopaedic Journal of Sports Medicine*. 2020; 8: 2325967120968557.

- [11] Bartolin PB, Boixadera R, Hudetz D. Experimental testing and finite element method analysis of the anterior cruciate ligament primary repair with internal brace augmentation. *Medical Engineering and Physics*. 2021; 95: 76–83.
- [12] Szwedowski D, Paczesny L, Zabrzynski J, Gagat M, Domzalski M, Huri G, *et al*. The Comparison of Clinical Result between Primary Repair of the Anterior Cruciate Ligament with Additional Internal Bracing and Anatomic Single Bundle Reconstruction- A Retrospective Study. *Journal of Clinical Medicine*. 2021; 10: 3948.
- [13] Heusdens CHW. ACL Repair: A Game Changer or Will History Repeat Itself? A Critical Appraisal. *Journal of Clinical Medicine*. 2021; 10: 912.
- [14] Morgan CD, Kalmam VR, Grawl DM. Isometry testing for anterior cruciate ligament reconstruction revisited. *Arthroscopy*. 1995; 11: 647–659.
- [15] Stähelin AC, Weiler A. All-inside anterior cruciate ligament reconstruction using semitendinosus tendon and soft threaded biodegradable interference screw fixation. *Arthroscopy*. 1997; 13: 773–779.
- [16] McAdams TR, Biswal S, Stevens KJ, Beaulieu CF, Mandelbaum BR. Tibial aperture bone disruption after retrograde versus antegrade tibial tunnel drilling: a cadaveric study. *Knee Surgery, Sports Traumatology, Arthroscopy*. 2008; 16: 818–822.
- [17] Lubowitz JH, Ahmad CS, Amhad CH, Anderson K. All-inside anterior cruciate ligament graft-link technique: second-generation, no-incision anterior cruciate ligament reconstruction. *Arthroscopy*. 2011; 27: 717–727.
- [18] Mohtadi NG, Chan DS, Dainty KN, Whelan DB. Patellar tendon versus hamstring tendon autograft for anterior cruciate ligament rupture in adults. *Cochrane Database of Systematic Reviews*. 2011; 2011: CD005960.
- [19] Romanini E, D'Angelo F, De Masi S, Adriani E, Magaletti M, Lacorte E, *et al*. Graft selection in arthroscopic anterior cruciate ligament reconstruction. *Journal of Orthopaedics and Traumatology*. 2010; 11: 211–219.
- [20] Goetz G, de Villiers C, Sadoghi P, Geiger-Gritsch S. Allograft for Anterior Cruciate Ligament Reconstruction (ACLR): A Systematic Review and Meta-Analysis of Long-Term Comparative Effectiveness and Safety. Results of a Health Technology Assessment. *Arthroscopy, Sports Medicine, and Rehabilitation*. 2020; 2: e873–e891.
- [21] Vaishya R, Agarwal AK, Ingole S, Vijay V. Current Trends in Anterior Cruciate Ligament Reconstruction: A Review. *Cureus*. 2015; 7: e378.
- [22] Kartus J, Movin T, Karlsson J. Donor-site morbidity and anterior knee problems after anterior cruciate ligament reconstruction using autografts. *Arthroscopy*. 2001; 17: 971–980.
- [23] Conte EJ, Hyatt AE, Gatt CJ, Dhawan A. Hamstring Autograft Size can be Predicted and is a Potential Risk Factor for Anterior Cruciate Ligament Reconstruction Failure. *Arthroscopy*. 2014; 30: 882–890.
- [24] Magnussen RA, Lawrence JTR, West RL, Toth AP, Taylor DC, Garrett WE. Graft size and patient age are predictors of early revision after anterior cruciate ligament reconstruction with hamstring autograft. *Arthroscopy*. 2012; 28: 526–531.
- [25] Galan H, Escalante M, Della Vedova F, Slullitel D. All inside full thickness quadriceps tendon ACL reconstruction: Long term follow up results. *Journal of Experimental Orthopaedics*. 2020; 7: 13.
- [26] Sprowls GR, Robin BN. The Quad Link Technique for an All-Soft-Tissue Quadriceps Graft in Minimally Invasive, All-Inside Anterior Cruciate Ligament Reconstruction. *Arthroscopy Techniques*. 2018; 7: e845–e852.
- [27] Park MJ, Lee MC, Seong SC. A comparative study of the healing of tendon autograft and tendon-bone autograft using patellar tendon in rabbits. *International Orthopaedics*. 2001; 25: 35–39.
- [28] Claes S, Verdonk P, Forsyth R, Bellemans J. The “ligamentization” process in anterior cruciate ligament reconstruction: what happens to the human graft? A systematic review of the literature. *American Journal of Sports Medicine*. 2011; 39: 2476–2483.
- [29] Noronha JC, Oliveira JP. Inside-out Tibial Tunnel Drilling Technique for all-inside Anterior Cruciate Ligament Reconstruction. *Arthroscopy Techniques*. 2018; 7: e373–e377.
- [30] Silva A, Sampaio R. Quadruple Semitendinosus Graft Construct and Suspensory Button Fixation for Anterior Cruciate Ligament Reconstruction. *Arthroscopy Techniques*. 2015; 4: e801–e806.
- [31] Mayr R, Heinrichs CH, Eichinger M, Coppola C, Schmoelz W, Attal R. Biomechanical comparison of 2 anterior cruciate ligament graft preparation techniques for tibial fixation: adjustable-length loop cortical button or interference screw. *American Journal of Sports Medicine*. 2015; 43: 1380–1385.
- [32] Lubowitz JH, Schwartzberg R, Smith P. Cortical Suspensory Button Versus Aperture Interference Screw Fixation for Knee Anterior Cruciate Ligament Soft-Tissue Allograft: A Prospective, Randomized Controlled Trial. *Arthroscopy*. 2015; 31: 1733–1739.
- [33] Wilson AJ, Yasen SK, Nancoo T, Stannard R, Smith JO, Logan JS. Anatomic all-inside anterior cruciate ligament reconstruction using the translateral technique. *Arthroscopy Techniques*. 2013; 2: e99–e104.
- [34] Lubowitz JH. Anteromedial portal technique for the anterior cruciate ligament femoral socket: pitfalls and solutions. *Arthroscopy*. 2009; 25: 95–101.
- [35] Lubowitz JH, Konicek J. Anterior cruciate ligament femoral tunnel length: cadaveric analysis comparing anteromedial portal versus outside-in technique. *Arthroscopy*. 2010; 26: 1357–1362.
- [36] Franceschi F, Papalia R, Rizzello G, Del Buono A, Maffulli N, Denaro V. Anteromedial portal versus transtibial drilling techniques in anterior cruciate ligament reconstruction: any clinical relevance? A retrospective comparative study. *Arthroscopy*. 2013; 29: 1330–1337.
- [37] Shah R, Srinivasan S, Hamed Y, Menon DK. Clinico-radiological outcomes following anatomical anterior cruciate ligament reconstruction using the TransLateral, all-inside technique. *Journal of Clinical Orthopaedics and Trauma*. 2020; 11: S326–S331.
- [38] Yosmaoglu HB, Baltaci G, Ozer H, Atay A. Effects of additional gracilis tendon harvest on muscle torque, motor coordination, and knee laxity in ACL reconstruction. *Knee Surgery, Sports Traumatology, Arthroscopy*. 2011; 19: 1287–1292.
- [39] Cordasco FA, Mayer SW, Green DW. All-Inside, All-Epiphyseal Anterior Cruciate Ligament Reconstruction in Skeletally Immature Athletes: Return to Sport, Incidence of Second Surgery, and 2-Year Clinical Outcomes. *American Journal of Sports Medicine*. 2017; 45: 856–863.
- [40] Placella G, Bartoli M, Peruzzi M, Speziali A, Pace V, Cerulli G. Return to sport activity after anterior cruciate ligament reconstruction in skeletally immature athletes with manual drilling original all inside reconstruction at 8 years follow-up. *Acta Orthopaedica et Traumatologica Turcica*. 2016; 50: 635–638.
- [41] Volpi P, Bait C, Cervellin M, Denti M, Prospero E, Morengi E, *et al*. No difference at two years between all inside transtibial technique and traditional transtibial technique in anterior cruciate ligament reconstruction. *Muscles, Ligaments and Tendons Journal*. 2014; 4: 95–99.
- [42] Lubowitz JH. All-inside anterior cruciate ligament graft link: graft preparation technique. *Arthroscopy Techniques*. 2012; 1: e165–e168.
- [43] Tiefenboeck TM, Hirtler L, Winnisch M, Binder H, Koch T, Komjati M, *et al*. The buried knot technique for all inside graft

link preparation leads to superior biomechanical graft link stability. *Scientific Reports*. 2019; 9: 1488.

- [44] Bowes J, Mohamed N, Baptiste JJ, Westover L, Hui C, Sommerfeldt M. Biomechanical Comparison of Graft Preparation Techniques for All-Inside Anterior Cruciate Ligament Reconstruction. *Orthopaedic Journal of Sports Medicine*. 2020; 8: 2325967120938039.
- [45] Lubowitz JH, Akhavan S, Waterman BR, Aalami-Harandi A, Konicek J. Technique for creating the anterior cruciate ligament femoral socket: optimizing femoral footprint anatomic restoration using outside-in drilling. *Arthroscopy*. 2013; 29: 522–528.
- [46] Loh JC, Fukuda Y, Tsuda E, Steadman RJ, Fu FH, Woo SL. Knee stability and graft function following anterior cruciate ligament reconstruction: Comparison between 11 o'clock and 10 o'clock femoral tunnel placement. *Arthroscopy*. 2003; 19: 297–304.
- [47] Yamamoto Y, Hsu W, Woo SL, Van Scyoc AH, Takakura Y, Debski RE. Knee stability and graft function after anterior cruciate ligament reconstruction: a comparison of a lateral and an anatomical femoral tunnel placement. *American Journal of Sports Medicine*. 2004; 32: 1825–1832.
- [48] Zaffagnini S, Bruni D, Martelli S, Imakiire N, Marcacci M, Russo A. Double-bundle ACL reconstruction: influence of femoral tunnel orientation in knee laxity analysed with a navigation system – an in-vitro biomechanical study. *BMC Musculoskeletal Disorders*. 2008; 9: 25.
- [49] Seon JK, Park SJ, Lee KB, Seo HY, Kim MS, Song EK. In vivo stability and clinical comparison of anterior cruciate ligament reconstruction using low or high femoral tunnel positions. *American Journal of Sports Medicine*. 2011; 39: 127–133.
- [50] Smith PA, Cook CS, Bley JA. All-inside Quadrupled Semitendinosus Autograft Shows Stability Equivalent to Patellar Tendon Autograft Anterior Cruciate Ligament Reconstruction: Randomized Controlled Trial in Athletes 24 Years or Younger. *Arthroscopy*. 2020; 36: 1629–1646.
- [51] Ciccotti MC, Secrist E, Tjoumakaris F, Ciccotti MG, Freedman KB. Anatomic Anterior Cruciate Ligament Reconstruction via Independent Tunnel Drilling: A Systematic Review of Randomized Controlled Trials Comparing Patellar Tendon and Hamstring Autografts. *Arthroscopy*. 2017; 33: 1062–1071.e5.
- [52] Goldblatt JP, Fitzsimmons SE, Balk E, Richmond JC. Reconstruction of the anterior cruciate ligament: meta-analysis of patellar tendon versus hamstring tendon autograft. *Arthroscopy*. 2005; 21: 791–803.
- [53] Prodromos CC, Joyce BT, Shi K, Keller BL. A meta-analysis of stability after anterior cruciate ligament reconstruction as a function of hamstring versus patellar tendon graft and fixation type. *Arthroscopy*. 2005; 21: 1202.
- [54] Spindler KP, Kuhn JE, Freedman KB, Matthews CE, Dittus RS, Harrell FE. Anterior cruciate ligament reconstruction autograft choice: bone-tendon-bone versus hamstring: does it really matter? A systematic review. *American Journal of Sports Medicine*. 2004; 32: 1986–1995.
- [55] Dauty M, Tortellier L, Rochcongar P. Isokinetic and anterior cruciate ligament reconstruction with hamstrings or patella tendon graft: analysis of literature. *International Journal of Sports Medicine*. 2005; 26: 599–606.
- [56] Biau DJ, Tournoux C, Katsahian S, Schranz PJ, Nizard RS. Bone-patellar tendon-bone autografts versus hamstring autografts for reconstruction of anterior cruciate ligament: meta-analysis. *British Medical Journal*. 2006; 332: 995–1001.
- [57] Jones PE, Schuett DJ. All-Inside Anterior Cruciate Ligament Reconstruction as a Salvage for Small or Attenuated Hamstring Grafts. *Arthroscopy Techniques*. 2018; 7: e453–e457.
- [58] Smith PA, Bley JA. Allograft Anterior Cruciate Ligament Reconstruction Utilizing Internal Brace Augmentation. *Arthroscopy Techniques*. 2016; 5: e1143–e1147.
- [59] Maletis GB, Inacio MCS, Desmond JL, Funahashi TT. Reconstruction of the anterior cruciate ligament: association of graft choice with increased risk of early revision. *Bone and Joint Journal*. 2013; 95-B: 623–628.
- [60] Richardson MW, Tsouris ND, Hassan CR, Elbayer JH, Qin YX, Komatsu DE, *et al.* A Biomechanical Comparison of Alternative Graft Preparations for all-inside Anterior Cruciate Ligament Reconstruction. *Arthroscopy*. 2019; 35: 1547–1554.
- [61] Wichern CR, Skoglund KC, O'Sullivan JG, Burwell AK, Nguyen JT, Herzka A, *et al.* A biomechanical comparison of all-inside cruciate ligament graft preparation techniques. *Journal of Experimental Orthopaedics*. 2018; 5: 42.
- [62] Fabbri M, Monaco E, Lanzetti RM, Perugia D, Guzzini M, Labianca L, *et al.* Single harvesting in the all-inside graft-link technique: is the graft length crucial for success? A biomechanical study. *Journal of Orthopaedics and Traumatology*. 2017; 18: 17–22.
- [63] Haber DB, Brook EM, Whitlock K, Matzkin EG. Predicting Quadrupled Graft Length and Diameter Using Single-Strand Tendon Dimensions in All-Inside Anterior Cruciate Ligament Reconstruction. *Arthroscopy*. 2018; 34: 243–250.
- [64] Serino J, Murray R, Argintar EH. Use of Magnetic Resonance Imaging to Predict Quadrupled Semitendinosus Graft Diameter in All-Inside Anterior Cruciate Ligament Reconstruction. *Orthopedics*. 2017; 40: e617–e622.
- [65] Mariscalco MW, Flanigan DC, Mitchell J, Pedroza AD, Jones MH, Andrich JT, *et al.* The influence of hamstring autograft size on patient-reported outcomes and risk of revision after anterior cruciate ligament reconstruction: a Multicenter Orthopaedic Outcomes Network (MOON) Cohort Study. *Arthroscopy*. 2013; 29: 1948–1953.
- [66] Park SY, Oh H, Park S, Lee JH, Lee SH, Yoon KH. Factors predicting hamstring tendon autograft diameters and resulting failure rates after anterior cruciate ligament reconstruction. *Knee Surgery, Sports Traumatology, Arthroscopy*. 2013; 21: 1111–1118.
- [67] Goyal S, Matias N, Pandey V, Acharya K. Are pre-operative anthropometric parameters helpful in predicting length and thickness of quadrupled hamstring graft for ACL reconstruction in adults? A prospective study and literature review. *International Orthopaedics*. 2016; 40: 173–181.
- [68] Spragg L, Chen J, Mirzayan R, Love R, Maletis G. The Effect of Autologous Hamstring Graft Diameter on the Likelihood for Revision of Anterior Cruciate Ligament Reconstruction. *American Journal of Sports Medicine*. 2016; 44: 1475–1481.
- [69] Smith PA, DeBerardino TM. Tibial Fixation Properties of a Continuous-Loop ACL Hamstring Graft Construct with Suspensory Fixation in Porcine Bone. *Journal of Knee Surgery*. 2015; 28: 506–512.
- [70] Brand J, Weiler A, Caborn DNM, Brown CH, Johnson DL. Graft fixation in cruciate ligament reconstruction. *American Journal of Sports Medicine*. 2000; 28: 761–774.
- [71] Blackman AJ, Stuart MJ. All-inside anterior cruciate ligament reconstruction. *Journal of Knee Surgery*. 2014; 27: 347–352.
- [72] Barrera CM, Ennis H, Delcroix GJ, Kaimrajh D, Milne E, Latta L, *et al.* Supplemental Fixation of Inner Graft Limbs in All-Inside, Quadrupled, Single-Tendon Anterior Cruciate Ligament Reconstruction Graft Construct Yields Improved Biomechanical Properties. *Arthroscopy*. 2019; 35: 909–918.
- [73] Boyle MJ, Vovos TJ, Walker CG, Stabile KJ, Roth JM, Garrett WE. Does adjustable-loop femoral cortical suspension loosen after anterior cruciate ligament reconstruction? A retrospective comparative study. *Knee*. 2015; 22: 304–308.
- [74] Desai VS, Anderson GR, Wu IT, Levy BA, Dahm DL, Camp CL, *et al.* Anterior Cruciate Ligament Reconstruction With Hamstring Autograft: A Matched Cohort Comparison of the All-

Inside and Complete Tibial Tunnel Techniques. *Orthopaedic Journal of Sports Medicine*. 2019; 7: 2325967118820297.

- [75] Lubowitz JH. All-inside ACL: retroconstruction controversies. *Sports Medicine and Arthroscopy Review*. 2010; 18: 20–26.
- [76] Basdekis G, Abisafi C, Christel P. Influence of knee flexion angle on femoral tunnel characteristics when drilled through the anteromedial portal during anterior cruciate ligament reconstruction. *Arthroscopy*. 2008; 24: 459–464.
- [77] Miller CD, Gerdeman AC, Hart JM, Bennett CG, Golish SR, Gaskin C, *et al.* A comparison of 2 drilling techniques on the femoral tunnel for anterior cruciate ligament reconstruction. *Arthroscopy*. 2011; 27: 372–379.
- [78] Steiner ME, Battaglia TC, Heming JF, Rand JD, Festa A, Baria M. Independent drilling outperforms conventional transtibial drilling in anterior cruciate ligament reconstruction. *American Journal of Sports Medicine*. 2009; 37: 1912–1919.
- [79] Rahr-Wagner L, Thillemann TM, Pedersen AB, Lind MC. Increased risk of revision after anteromedial compared with transtibial drilling of the femoral tunnel during primary anterior cruciate ligament reconstruction: results from the Danish Knee Ligament Reconstruction Register. *Arthroscopy*. 2013; 29: 98–105.
- [80] Lubowitz JH, Schwartzberg R, Smith P. Randomized controlled trial comparing all-inside anterior cruciate ligament reconstruction technique with anterior cruciate ligament reconstruction with a full tibial tunnel. *Arthroscopy*. 2013; 29: 1195–1200.
- [81] Pautasso A, Capella M, Barberis L, Drocco L, Giai Via R, Bistolfi A, *et al.* All-inside technique in ACL reconstruction: mid-term clinical outcomes and comparison with AM technique (Hamstrings and BpTB grafts). *European Journal of Orthopaedic Surgery and Traumatology*. 2021; 31: 465–472.
- [82] Schurz M, Tiefenboeck TM, Winnisch M, Syre S, Plachel F, Steiner G, *et al.* Clinical and Functional Outcome of All-Inside Anterior Cruciate Ligament Reconstruction at a Minimum of 2 Years' Follow-up. *Arthroscopy*. 2016; 32: 332–337.
- [83] Fu CW, Chen WC, Lu YC. Is all-inside with suspensory cortical button fixation a superior technique for anterior cruciate ligament reconstruction surgery? A systematic review and meta-analysis. *BMC Musculoskeletal Disorders*. 2020; 21: 445.
- [84] Mayr R, Smekal V, Koidl C, Coppola C, Eichinger M, Rudisch A, *et al.* ACL reconstruction with adjustable-length loop cortical button fixation results in less tibial tunnel widening compared with interference screw fixation. *Knee Surgery, Sports Traumatology, Arthroscopy*. 2020; 28: 1036–1044.
- [85] Yaseen SK, Borton ZM, Eyre-Brook AI, Palmer HC, Cotterill ST, Risebury MJ, *et al.* Clinical outcomes of anatomic, all-inside, anterior cruciate ligament (ACL) reconstruction. *Knee*. 2017; 24: 55–62.
- [86] Benea H, d'Astorg H, Klouche S, Bauer T, Tomoaia G, Hardy P. Pain evaluation after all-inside anterior cruciate ligament reconstruction and short term functional results of a prospective randomized study. *Knee*. 2014; 21: 102–106.
- [87] Grawe BM, Williams PN, Burge A, Voigt M, Altchek DW, Hannafin JA, *et al.* Anterior Cruciate Ligament Reconstruction with Autologous Hamstring: Can Preoperative Magnetic Resonance Imaging Accurately Predict Graft Diameter? *Orthopaedic Journal of Sports Medicine*. 2016; 4: 2325967116646360.
- [88] Bressy G, Brun V, Ferrier A, Dujardin D, Oubaya N, Morel N, *et al.* Lack of stability at more than 12 months of follow-up after anterior cruciate ligament reconstruction using all-inside quadruple-stranded semitendinosus graft with adjustable cortical button fixation in both femoral and tibial sides. *Orthopaedics and Traumatology: Surgery and Research*. 2016; 102: 867–872.
- [89] Barrow AE, Pilia M, Guda T, Kadrmaz WR, Burns TC. Femoral suspension devices for anterior cruciate ligament reconstruction: do adjustable loops lengthen? *American Journal of Sports Medicine*. 2014; 42: 343–349.
- [90] Browning WM 3rd, Kluczynski MA, Curatolo C, Marzo JM. Suspensory Versus Aperture Fixation of a Quadrupled Hamstring Tendon Autograft in Anterior Cruciate Ligament Reconstruction: a Meta-analysis. *American Journal of Sports Medicine*. 2017; 45: 2418–2427.