

Chlamydia Trachomatis diagnosis: a correlative study of pap smear and direct immunofluorescence

G. GAROZZO - E. LOMEIO - M. LA GRECA - M. G. CASTIGLIONE
M. CARUSO - M. SORRENTI - S. GRILLO

Summary: From June 1989 to September 1990, 255 women with recurrent vaginitis, were evaluated, at the "Service of Precocious Diagnosis and Therapy of Gynecological Tumor" of the 1st Department of Obstetrics and Gynecology. They were compared with a control group of 255 women selected in the same time. All patients between the ages of 18-40 years, with normal sexual behaviour, had a negative colposcopy for HPV and HSV2 infections.

The cervical smear with Papanicolaou technique and direct immunofluorescence (DIF) was performed in all patients. The specimens were examined with a fluorescence microscope (Leitz). Positive determinations were confined by examination at a magnification of 600 X. Slides were scored as positive if at least 5 distinct apple-green fluorescence-stained elementary body per field was observed.

The two groups were entirely comparable in age, parity, method of contraception, and number of sexual contacts over the preceding three months. Our data confirmed a higher incidence of Chlamydial infections in women with recurrent vaginitis (34.1%) than in control group (8.23%). In symptomatic women, more cases of metaplastic cells with cytoplasmic vacuolation, less inflammatory alteration and a lack of specific agents like CA and TV, were found than in the control group. The DIF positivity, in both groups, was connected with a cytological findings of metaplastic cells with cytoplasmic vacuolation in 72.3% and 50% respectively.

Key words: Chlamydia Trachomatis; Immunofluorescence.

INTRODUCTION

Chlamydia Trachomatis infection is reported to be one of the most frequent sexually transmitted diseases (¹⁻²).

In the United States an annual increase of 7 million of STD, 4 million of these are CT infections, 2 million gonococ-

cal and 1 million virus infections (HPV and HSV2) is reported (³). About one third of the entire population of many European countries will have had one or more genital CT infection during their life-time (⁴).

Infection is more often asymptomatic than symptomatic, so infected persons can effectively spread the infection to others: the epidemic character of such disease can thus be understood (⁵⁻⁶).

In symptomatic women common form is a mucopurulent cervicitis (⁷⁻⁸) with leukorrhea, pain, burning and itching, sometimes acute and chronic salpingitis with

1st Department of Obstetrics and Gynecology
Gynecological Oncology II, University of Catania

All rights reserved — No part of this publication may be reproduced or transmitted in any form or by any means, electronic or mechanical, including photocopy, recording, nor any information storage and retrieval system without written permission from the copyright owner.

an increased risk of infertility (a hypothetical role on tubal mucosa or on the immune system)⁽⁹⁾. Some authors have found a correlation between CT infection and cervical dysplasia⁽¹⁰⁻¹¹⁾.

Many Authors, in the last years, have been interested in the methodological investigation, therapeutical protocols and individuation of the population at risk for STD (particularly for CA)⁽¹²⁻¹³⁾.

Detection of CT has been difficult and expensive. The aim of our study, is to recognize the CT infection by a simple methodological investigation for an effective population screening.

Therefore, cytological findings and direct IF test with monoclonal antibody in patients with recurrent vaginitis and a control group were compared, to establish the value of pap smear in the diagnosis of Chlamydial infection.

MATERIALS AND METHODS

From June 1989 to September 1990, 255 women with recurrent vaginitis, were evaluated, (12 of them were pregnant before 12th week). This occurrence (7.9%) was noted from a screening pool of 3,215 women presenting for routine gynecologic smears, at the "Service of Precocious Diagnosis and Therapy of Gynecological Tumors" of the Department of Obstetrics and Gynecology, 1st Clinic. These women were symptomatic for vaginitis and had had three consecutive negative pap smears in the past 6 months (no microbial agents were evidenced). They were compared with 255 women selected at the same time, with the last pap smear negative for STD within the past twelve months/without an abnormal papanicolaou smear within the past twelve months.

All patients between the ages of 18-40 years, with normal sexual behaviour, had a negative colposcopy for HPV and HSV 2 infections.

The cervical smear, carefully by Aire spatula to ensure a good sampling of cells; slides were then stained by the Papanicolaou technique. Afterwards the cervix was wiped to remove excess mucus and a sterile cotton-tipped swab was inserted into the endocervical canal and rotated 360°; direct immunofluorescence staining of smears with fluorescein-conjugated monoclonal antibody (Microtrak) was performed. The specimens were examined with a fluorescence

microscope (Leitz). Positive determinations were confirmed by examination at a magnification of 600 X. Slides were scored as positive if at least 5 distinct apple-green fluorescein-stained elementary body per field was observed.

RESULTS

The two groups were entirely comparable in age, parity, method of contraception, and number of sexual contacts over the preceding three months.

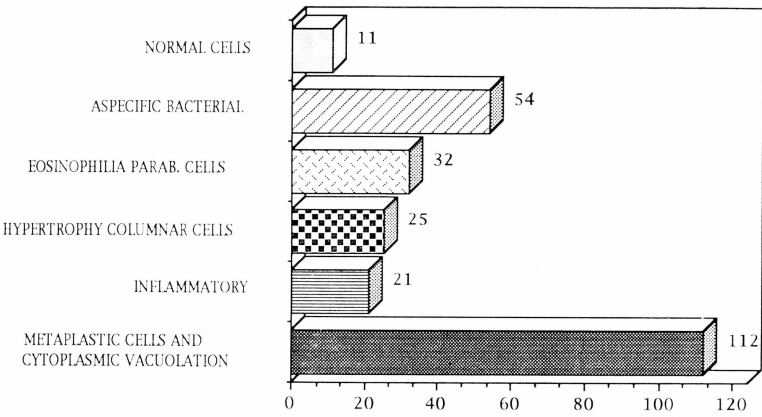
Cytologic diagnosis in women with recurrent vaginitis are shown in Table 1: normal cells in 11 cases (4.1%), aspecific microbial flora in 54 (21.1%), eosinophilic parabasal cells in 32 (12.6%), hypertrophic nuclei in columnar cells in 25 (9.8%), superficial and intermediate cells with inflammatory alteration in 21 (8.4%), metaplastic cells with cytoplasmic vacuolation in 112 (43%).

In the same group the direct immunofluorescence with fluorescein-conjugated monoclonal antibody (Microtrak) was positive in 87 cases, (34.1%). as reported before, slides were scored as positive if ≥ 5 distinct green elementary bodies was observed.

In table 2 we compare cytological findings with DIF: in normal cells we found 2 cases with DIF positive (18%), in aspecific microbial flora (3.70%), in eosinophilic parabasal cells and hypertrophic nuclei in columnar cells, none in superficial and intermediate cells with inflammatory alteration 2 (9.5%), in metaplastic cells with cytoplasmic vacuolation the higher incidence 81 cases (72.7%).

Cytological findings in control group are shown in table 3: normal cells in 45 cases (17.6%), candida albicans in 14 (5.5%), trichomonas vaginalis in 18 (7.04%), aspecific microbial flora in 43 (16.9%), superficial and intermediate cells with inflammatory alteration in 97 (38.03%), metaplastic cells with cytoplasmic vacuolation in 38 (14.9%).

Table 1. — *Cytological findings in women with recurrent vaginitis.*



The direct IF test was positive in 21 cases, (8.23%).

In table 4 we report cytological finding compared with DIF: in normal cells, aspecific microbial flora, candida albicans and trichomonas vaginalis. We did not find any DIF positive cases, in superficial and intermediate cells with inflammatory alteration 2 cases (2.02%), in metapla-

stic cells with cytoplasmic vacuolation the higher incidence with 19 cases (50%).

Our data confirmed higher incidence of Chlamydial infections in women with recurrent vaginitis (34.1%) than in control group (8.23%). In symptomatic women, more cases of metaplastic cells with cytoplasmic vacuolation, less inflammatory alteration and a lack of specific agents like

Table 2. — *Correlation between cytology and D.I.F. in women with recurrent vaginitis.* (Cytological findings).

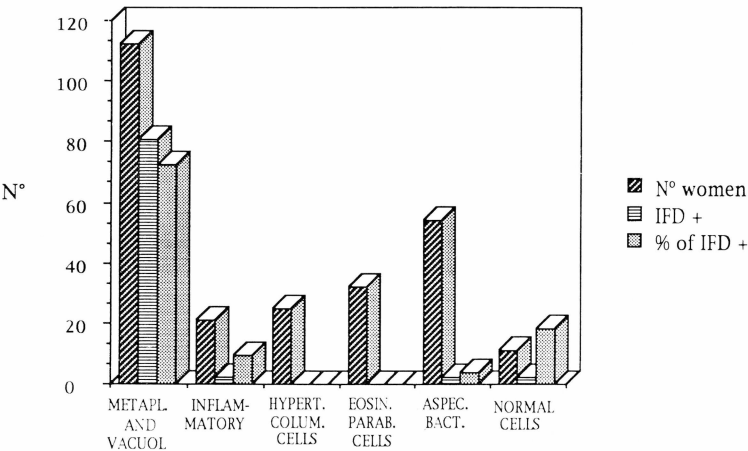
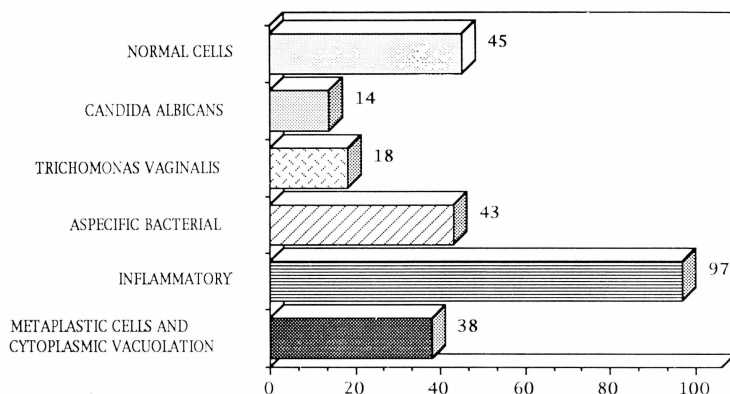


Table 3. — *Cytological findings in control group.*



CA and TV, found than in the control group.

The DIF positivity, in both groups, was connected with a cytological finding of metaplastic cells with cytoplasmic vacuolation in 72.3% and 50% respectively.

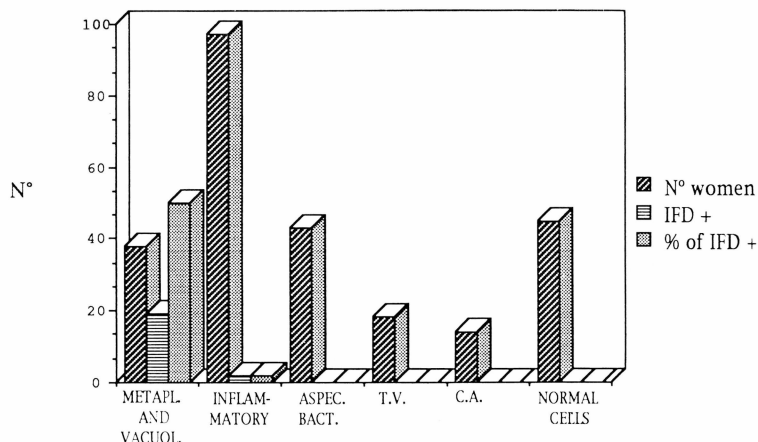
CONCLUSIONS

Many authors have been very interested in recognizing a simple methodological in-

vestigation for an effective population screening.

Literature reports cytological signs of CT infection: enlarged metaplastic squamous cell, with multinucleation; they occur singly or in small groups, the cytoplasm is basophilic, finely granular "coc-coid bodies"; afterwards multiple cyto-plasmic vacuolization occurred randomly or in the perinuclear areas, enlarging and deforming cells.

Table 4. — *Correlation between cytology and D.I.F. in control group. (Cytological findings).*



Chlamydia Trachomatic infections is often asymptomatic, but recurrent vaginitis and abortion, sterility are reasons for suspecting the infection.

Our data showed a higher incidence of Chlamydial infection in women with recurrent vaginitis (34.1%) than in the control group (8.23%), and confirmed that cytological presence of metaplastic cells with cytoplasmic vacuolation was predictive for CT infection (72.3% and 50% respectively). Thus pap smears could become the main screening test for population at risk to be followed for a correct diagnosis by DIF with monoclonal antibody.

REFERENCES

- 1) Dorman S.A.: "Detection of chlamydial cervicitis by Papanicolau and culture". *Am. J. Clin. Pathol.*, 1983, 79, 421.
- 2) Kent G.P., Harrison H.R., Berman S.M., Keenlyside R.A.: "Screening for Chlamydia Trachomatis infection in a sexually transmitted disease clinical and historical risk factors". *Sex. Transmitted Disease*, 1988, 15, 51.
- 3) Gupta P.K., Lee E.F., Erozan Y.S., Frost J.K., Geddes S.T., Donovan P.A.: "Cytologic investigation in Chlamydia infection". *Acta Cytol.*, 1970, 23, 315.
- 4) Ladany S., Sarov I.: "Recent advances in Chlamydia Trachomatis". *Eur. J. Epidemiol.*, 1985, 1, 235.
- 5) Baselski V.S., McNeeley S.G., Ryan G., Robinson M.: "A comparison of nonculture-dependent methods for detection of Chlamydia Trachomatis infections in pregnant women". *Obst. Gyn.*, 1987, 70, 47.
- 6) Spence M.R., Adler J.F.: "Chlamydia Trachomatis". *Adv. Exp. Med. Biol.*, 1987, 224, 79.
- 7) Stamm W.E.: "Diagnosis of Chlamydia Trachomatis genitourinary infections". *Annals of Intern. Medic.*, 1988, 180, 710.
- 8) Spence M.R., Barbacci M., Kappus E., Quinn T.: "A correlative study of Papanicolau smear, fluorescent antibody, and culture for the diagnosis of Chlamydia Trachomatis". *Obst. Gyn.*, 1986, 68, 691.
- 9) Meriwether C.D., Evans and Sokol R.J.: "Chlamydia Trachomatis: a practical obstetric gynecologic management approach". *Int. J. Gyn. Obst.*, 1986, 24, 407.
- 10) Nagashima Tetsuo: "A high prevalence of chlamydial cervicitis in postmenopausal women". *Am. J. Obst. Gyn.*, 1987, 156, 31.
- 11) Shacter J.: "Chlamydial infection in women with cervical dysplasia". *Am. J. Obst. Gyn.*, 1975, 123, 753.
- 12) Henrion R.: "Reflexion sur la prevention des infections a Chlamydia Trachomatis chez la femme". *Rev. Fr. Gyn. Obst.*, 1984, 79, 10.
- 13) Catalan F., Khoury B., Quizman E., Mimic V., Doulé D., Margeray M.: "Nouvelles methodes de diagnostic des infections à Chlamydia". *Rev. Fr. Gyn. Obst.*, 1984, 79, 617.

Address reprints requests to:

G. GAROZZO

Ist. di I Clinica Ostetrica Ginecologica

Università Studi Catania

Via Plebiscito, 632

Catania (Italy)