

# The role of laparoscopy in the treatment of endometriosis

V. MAIS - S. AJOSSA - S. GUERRIERO - A. M. PAOLETTI  
M. PALMAS - M. MASCIA - G. B. MELIS

**Summary:** The aim of the present study was to evaluate the role of laparoscopy not only in the diagnosis but also in the therapy of pelvic endometriosis. Ninety-four patients underwent laparoscopy between May 1991 and May 1993. The patients were divided into 2 groups, according to the indication for laparoscopy: group I (benign ovarian cysts  $n = 47$ ); group II (chronic pelvic pain,  $n = 47$ ). All laparoscopies were performed by 2 surgeons only. When present, endometriosis was scored according to the American Fertility Society revised classification 1985 (AFS 1985). Endometriosis was present in 37 (39.4%) of the 94 patients included in the study: 19 out of 47 (40.4%) in group I, 18 out of 47 (38.3%) in group II. In 29 patients with endometriosis (78.3%), the score was reduced surgically during the diagnostic procedure. In 24 cases (82.8%) by laparoscopy and in 5 cases (17.2%) only, by laparotomy. Therefore, the careful selection of cases, the use of appropriate instruments and the experience in endoscopic surgery, combined with a good knowledge of pelvic anatomy, may allow the treatment of endometriosis immediately after diagnosis by laparoscopy, resulting in shorter hospitalization, less physical trauma, and a lower number of post-operative adhesions.

**Key words:** Laparoscopy; Endometriosis; Benign ovarian masses; Chronic pelvic pain.

## INTRODUCTION

Endometriosis is a gynecologic disease, characterized by the presence of endometriotic implants in ectopic sites. This pathology is often associated with infertility, chronic pelvic pain, dysmenorrhea, dyspareunia and the presence of ovarian masses <sup>(1)</sup>.

The therapy of endometriosis has undergone changes over the last 20 years.

---

Department of Obstetrics and Gynecology  
University of Cagliari  
Cagliari (Italy)

*All rights reserved* — No part of this publication may be reproduced or transmitted in any form or by any means, electronic or mechanical, including photocopy, recording, nor any information storage and retrieval system without written permission from the copyright owner.

First, the combination of an estrogen and a progestogen has been used to induce "pseudopregnancy" <sup>(2)</sup>. Thereafter, induction of "pseudomenopause" has also been used, following the first clinical study with danazol published by Greenblatt *et al.* <sup>(3)</sup>. Finally, "medical oophorectomy" induced by GnRH-agonists has been proposed <sup>(4)</sup>.

Recently, following the improvement of endoscopic techniques, many gynecologists have started treating endometriosis by operative laparoscopy alone or in combination with medical treatment <sup>(5)</sup>.

Therefore, the aim of the present study was to evaluate the role of laparoscopy not only in the diagnosis but also in the treatment of pelvic endometriosis.

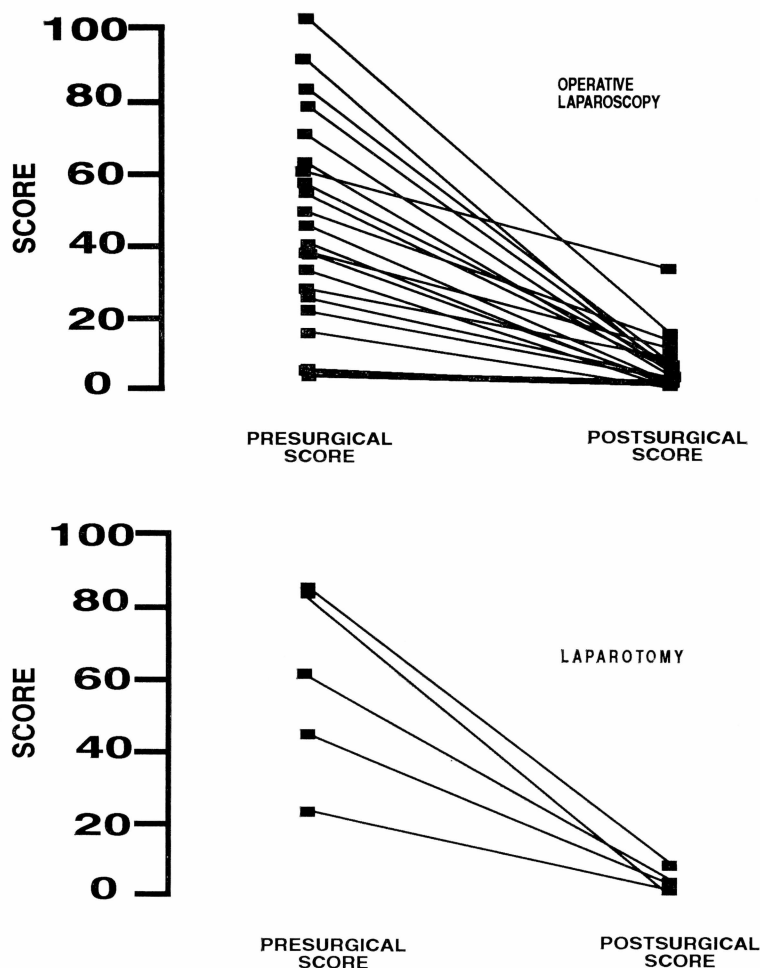


Fig. 1. — Reduction of the score of endometriosis by laparoscopy and laparotomy.

## MATERIALS AND METHODS

Ninety-four premenopausal patients underwent laparoscopy between May 1991 and May 1993 at the Department of Obstetrics and Gynecology of the University of Cagliari. The patients were divided into 2 groups, according to the indication for laparoscopy: group I (benign ovarian cysts,  $n=47$ ); group II (chronic pelvic pain,  $n=47$ ).

All laparoscopies were carried out by 2 surgeons who recorded their findings on preprinted sheets. During laparoscopies all the pelvis was

systematically inspected. The diagnosis of endometriosis was based on the characteristic visual presentation of the disease and biopsies were taken when possible. Endometriosis was scored using the Revised American Fertility Society Classification (<sup>6</sup>).

When endometriosis was present, the surgeons always tried to treat the disease by laparoscopy, shifting to laparotomy only when mandatory.

Postoperative residual endometriosis was also scored using the Revised American Fertility Society Classification (<sup>6</sup>).

## RESULTS

Thirty-seven (39.4%) of the 94 patients included in the study had endometriosis: 19 out of 47 (40.4%) in group I, 18 out of 47 (38.3%) in group II. In group 1 endometriosis was scored Stage I in 3 patients (15.8%), Stage III in 8 patients (42.1%) and Stage IV in 8 patients (42.1%).

In group 2, the stage of endometriosis was I in 12 patients (66.7%), II in 2 patients (11.1%), III in 2 patients (11.1%) and IV in 2 patients (11.1%).

The visual diagnosis was confirmed by histopathological examination in 34 out of 37 patients (sensitivity 92%). In 3 cases biopsies identified endometriotic lesions that were not visualized by laparoscopy (specificity 94%).

In 29 of the 37 patients with endometriosis (78.3%) the score was reduced by surgery immediately after diagnosis: in 24 cases (82.8%) by laparoscopy and in 5 cases (17.2%) only, by laparotomy (Figure 1).

In 1 out of the 5 patients having the score reduced by laparotomy a uterine myoma was also present.

## DISCUSSION

This study demonstrates the effectiveness of laparoscopy not only in the diagnosis, but also in the treatment of pelvic endometriosis. In fact, this technique showed a sensitivity of 92% and a specificity of 94% in the visual diagnosis of endometriosis, confirming the results previously reported by other authors (7).

Moreover, laparoscopy appeared to be the only technique capable of identifying not only endometriomas, but also small endometriotic implants.

As for treatment, in 24 patients out of 29 (82.8%) operative laparoscopy resulted to be highly effective in reducing the score or completely eradicating the disease.

Only in 5 patients (17.2%) had the surgeons to shift to laparotomy. The resolution of endometriosis by laparoscopy in these patients is the main result of the present study since laparoscopic surgery determines minimal damage to the surrounding tissues and reproductive capacity is better preserved (5). Moreover, laparoscopy causes minimal discomfort and allows the treatment of the disease during the diagnostic procedure, resulting in shorter hospitalization, less physical trauma, and a lower number of post-operative adhesions.

## REFERENCES

- 1) Mahmood T. A., Templeton A.: "Prevalence and genesis of endometriosis". *Human Reprod.*, 1991, 6, 544.
- 2) Kistner R. W.: "Management of endometriosis in the infertile patients". *Fertil. Steril.*, 1975, 26, 1151.
- 3) Greenblatt R. B., Dmowski L. P., Mohesh U., Scholer H. F. C.: "Clinical studies with an antigonadotrophin-danazol". *Fertil. Steril.*, 1971, 22, 102.
- 4) Lemay A., Maheux R., Faure R., Jean N., Fazekas C.: "Reversible hypogonadism induced by luteinizing hormone-releasing hormone (LH-RH) agonist (Buserelin) as a new therapeutic approach for endometriosis". *Fertil. Steril.*, 1984, 41, 863.
- 5) Favez J. A., Vogel M. F.: "Comparison of different treatment methods of endometriomas by laparoscopy". *Obst. Gyn.*, 1991, 78, 660.
- 6) The American Fertility Society: "Revised American Fertility Society Classification of Endometriosis". *Fertil. Steril.*, 1985, 43, 351.
- 7) Vercellini P., Vendola N., Bocciarelli L., Rognoni M. T., Carinelli S. G., Candiani G. B.: "Reliability of the visual diagnosis of ovarian endometriosis". *Fertil. Steril.*, 1991, 56, 1198.

---

Address reprints requests to:

G. B. MELIS

Department of Obstetrics and Gynecology

University of Cagliari

Ospedale S. Giovanni di Dio

Via Ospedale, 46

09124 Cagliari (Italy)