

Juvenile Laryngeal Papillomatosis from an HPV-positive mother

A case report

S. ALBERICO - R. PINZANO - M. COMAR - E. ZOCCONI - S. GUASCHINO

INTRODUCTION

In 1956 Hajek noticed the possibility for the Human-Papilloma-Virus (HPV) to be transmitted by the maternal-foetus route.

The infection contracted at birth may lead to Laryngeal or Respiratory papillomatosis (RP) during infancy as well as in older age⁽¹⁾. In the first year of life, RP may cause a respiratory obstruction, since the larynx of small dimensions. Moreover, even if it is a histologically benign tumor, it can disseminate at pulmonary-bronchial level, it relapse, frequently and the possibility of its occasional malignant conversion is proved.

The great increase of HPV infection in the maternal lower genital tract in recent years can either be accounted for by wider viral diffusion or by the use of more

sophisticated techniques of HPV-DNA identification such as PCR.

The frequency of HPV infection among reproductive women varies between 10% and 60% of cases^(2, 3, 4). Increased infection rates during pregnancy were noticed by Fife⁽⁵⁾, Schneider⁽⁶⁾ e Rando⁽⁷⁾ and increased incidence from the first to the third trimester were also described. Such courses are not unanimous⁽⁸⁾, but according to the Literature, the frequency varies between 23.5% and 28%^(6, 7, 8).

Epidemiological studies carried out by Kashima have identified some risk factors leading to maternal-foetal transmission and consequent laryngeal papillomatosis. These are: vaginal birth, firstborn with associated prolonged labour and the mother being of teen-age⁽⁹⁾.

The transmission of HPV infection through the birth canal does not seem to be the only way of the viral transmission. Tseng *et al.*⁽¹⁰⁾ have hypothesized the transplacental transmission before delivery leading to identification of HPV-DNA in the cord-blood of neonates born to women with HPV infection. This positivity showed a closer correlation with the HPV-DNA status in maternal peripheral blood mononuclear cells than in the cervicovaginal cells.

Received 19-8-1994 from the
Obstetrical and Gynaecological Clinic
(University of Trieste)
and Oto-Rhino-laryngoiatric Division Childhood
Institute "Burlo Barofolo", Trieste, Italy

Revised manuscript accepted for publication
20-2-1995.

All rights reserved — No part of this publication may be reproduced or transmitted in any form or by any means, electronic or mechanical, including photocopy, recording, nor any information storage and retrieval system without written permission from the copyright owner.

CASE REPORT

D.B., one year old, born by spontaneous delivery was examined in the ORL Division of the Childhood Institute because of an aphonia together with breathing difficulties after a minimum effort, which had appeared two months earlier during an episode of high fever following routine vaccination. Direct laryngoscopy with total anaesthesia showed an extended papillomatosis of the anterior commissure of the larynx and anterior third of the vocal chords. The papillomatosis was surgically removed by micro-laryngoscopy. The biopsy was also sent for the HPV-DNA test by means of PCR.

The mother, M.D.C., a twenty-nine year old, secundigravida, native of Santo Domingo, previously treated with electrocoagulation diathermy for cervical intraepithelial neoplasia (CIN I, was subjected to colposcopic, cytologic and histologic evaluations. The colposcopic investigation was condyloma acuminatum of the vaginal fornix and abnormal colposcopic finding of minor change (International Terminology of Colposcopy) (11). Cytologic examination revealed dyskeratosis and cervical histologic diagnosis was squamous metaplasia. A sample for HPV-DNA detection and typing was obtained by means of PCR cyto-brush.

MATERIALS AND METHODS

1) Cell Culture

CAS KI, HELA cell lines were cultured in RPMI 1640 medium supplemented with 10% fetal calf serum. CAS KI, containing HPV 16 and HELA HPV 18 sequences, were used as positive controls.

2) Tissues

Surgical specimens were washed in saline solution after removal and conserved in a formaline aqueous solution (4%). Cervix biopsy was washed twice in PBS buffer and immediately frozen at -20°C .

3) Amplification and characterization of HPV sequences

Genomic DNA was extracted from tissues with Phenol/Chloroform/Isoamylalcohol method. PCR was performed using 1 ng of total DNA.

Primers specific for a segment of the E6 gene of either HPV 6 and HPV 11, and a couple of primers encompassing the E6-E7 transforming genes, specific for HPV 16-18-31-51-52 detection, were used during amplification.

Ten microliters of each reaction products were analyzed on 8% non-denaturing polyacrylamide gel after staining with ethidiumbromide.

HPV characterization was performed by liquid hybridization assay using ^{32}P -labelled oligomer probe specific for each HPV's subtype.

The positive PCR products were also cloned into a bluescript vector, and DNA sequences were determined by the dideoxy chain termination procedure of Sanger with the Sequenase version 2.0 kit according to the supplier's recommendations.

RESULTS

In the DNA of the laryngeal and cervical tissues the same HPV type 6 was sequenced; the maternal DNA resulted positive for HPV type 16 (Fig. 1).

The peripheric blood resulted negative in both. The childhood blood was positive for CMV-DNA.

The child was also subjected to the immune function study which evidenced an N.K., T cytotoxic and suppressor cell reduction; such a situation evidencing a recent viral infection.

After the surgical treatment the aphonia and the breathing obstruction were resolved. In the check-ups made after two, four and twelve weeks from the operation there were no signs of relapse. The immunological check-ups made after a medical therapy with thymic calf extract evidenced a normalization after 20 days from the operation.

DISCUSSION

The juvenile onset of respiratory papillomatosis is a rare pathology but the existing literature does not describe an exact evaluation of the disease-risk breaking out in children born of HPV positive mothers. Shah (9) estimates this risk as one in several hundred cases, but the percentage is much higher when the infection, rather than the disease itself, is being considered. The development of the disease requires other conditions; in our child we observed that the concurrent infection from CMV could be responsible for the altered response of the cell mediated immunity

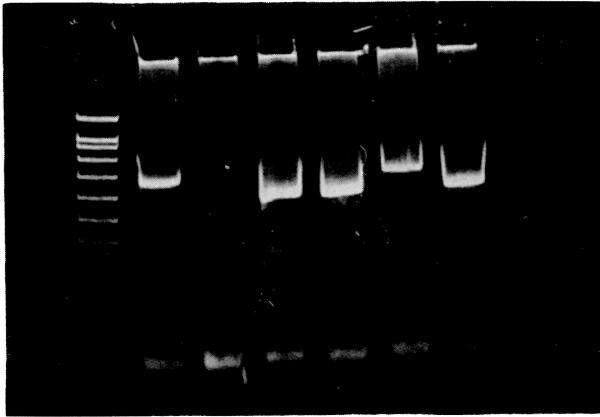


Fig. 1.

Legend – PCR products: Lane 1: molecular weight; Lane 2: HPV 16 positive control; Lane 3: children's PCR negative for HPV 16; Lane 4: HPV 6 positive control; Lane 5: children's PCR positive for HPV 6; Lane 6: mother's PCR positive for HPV 16; Lane 7: mother's PCR positive for HPV 6; Lane 8: H₂O.

towards the type of virus and the relative deficit of the local immune system.

The lack of HPV-DNA positivity in the child's and mother's peripheric blood, in the case described confirms the hypothesis of the viral transmission through the cervical-vaginal smears, since the HPV epitheliotropism is high, making the transplacental passage hypothesis less probable.

Nevertheless, in certain circumstances, a transitory viraemia can occur, as was described by Tseng, which later clears up without any consequences.

PCR has played a very important role in diagnostics and prognostics; while the maternal cytohistologic screening proved negative for HPV, PCR permitted the identification of a malignant type, HPV 16, which calls for a careful follow-up of the mother, as well as of HPV 6, which is responsible for the child's infection at the laryngeal level. Nevertheless, because of its high cost and complexity, this technique cannot be proposed as a screening for genital tract neoplasias, and it should be used only in isolated cases in order to

modulate the most suitable follow-up and the treatment when this is necessary.

It would also be advisable to take a laryngeal sample with a tampon from children born of HPV positive mothers for HPV-DNA study with PCR, to identify the RP cases and to prevent malignant conversion to squamous papilloma of the respiratory tract.

Finally, the discordant data on maternal foetal transmission of the HPV infection and the fact that the disease rarely occurs in children leads us to believe that caesaren delivery in case of HPV positive mothers is not necessary.

REFERENCES

- 1) Wright T.C., Richart R.M.: "Role of human papillomavirus in the pathogenesis of genital tract warts and cancer". *Gyn. Oncol.*, 1990, 37, 151.
- 2) Shah K., Kashima H., Polk F. *et al.*: "Rarity of cesarean in Cases of Juvenile-onset respiratory papillomatosis". *Obst. Gyn.*, 1986, 68 (6), 795.
- 3) Young L.S., Bevan I.S., Johanson M.A. *et al.*: "The polymerase chain reaction: a new epidemiological tool for investigating

- cervical human papillomavirus infection". *BMJ*, 1989, 14, 298.
- 4) Tidy J. A., Parry G. C. N., Ward P. *et al.*: "High rate of human papillomavirus type 16 infection in cytologically normal cervixes". *Lancet*, 1989, 1, 434.
 - 5) Fife K. H., Rogers R. E., Zwickl B. W.: "Symptomatic and asymptomatic cervical infections with human papillomavirus during pregnancy". *J. Infect. Dis.*, 1987, 156, 904.
 - 6) Schneider A., Hotz M., Gissmann L.: "Increased prevalence of human papillomavirus in the lower genital tract of pregnant women". *Int. J. Cancer.*, 1987, 40, 198.
 - 7) Rando R. F., Lindheim S., Hasty L. *et al.*: "Increased frequency of detection of human papillomavirus deoxyribonucleic acid in exfoliated cervical cells during pregnancy". *Am. J. Obst. Gyn.*, 1989, 161, 50.
 - 8) Kemp E. A., Hakenwerth A. M., Laurent S. L. *et al.*: "Human papillomavirus prevalence in pregnancy". *Obst. Gyn.*, 1992, 79, 649.
 - 9) Kashima H. K., Shah K., Lyles A. *et al.*: "A comparison of risk factors in juvenile-onset and adult-onset recurrent respiratory papillomatosis". *Laryngoscope*, 1992, 102, 9.
 - 10) Tseng C. J., Lin C. Y., Wang R. L.: "Possible transplacental transmission of human papillomaviruses". *Am. J. Obst. Gyn.*, 1992, 166, 35.
 - 11) Stalf A., Wilbanks G. D.: "International terminology of colposcopy". *Cervix*, 1991, 9, 91.

Address reprint requests to:

S. ALBERICO

Obstetrical and Gynaecological Clinic

Childhood Institute "B. Garofolo"

Via dell'Istria, 65/1

34100 Trieste (Italy)