

Hematocolpos by imperforated hymen.

Case report

D. A. Maffeo¹, P. Santagata², M. Santagata³

¹*Oncologist gynecologist surgeon at "Istituto dei tumori", Fondazione Pascale, Naples*

²*Director of endocrinological surgery at "Cardarelli", Naples (Italy)*

Imperforation of the hymen is a rare congenital deformity, characterized by chronic retention of vaginal secretions and menstrual blood [4].

The incidence is reported at a frequency of 1:2,000 gynecological patients [8] and with an adolescent incidence oscillating between 0.014% and 0.024% [1]. Sometimes there is a familial predisposition, although it is not frequent.

Since the first description of vaginal embryogenesis given by Koff in 1933 [3] it has been possible to perform a primary caudal fusion of the Muellerian ductus, followed by unification at the level of the urogenital sinus with a central epithelial proliferation and consequent canalization of the Muellerian ductus to form a definitive vagina.

A variety of canalization defects with various forms of complete vaginal obstruction due to septal persistence localized at various levels of the vaginal canal have been described.

The imperforated hymen represents a low subline of transversalis vaginal septum [6]. This deformity is only sometimes associated with urogenital congenital anomalies, while vaginal agenesis (Mayer-Rokitansky-Kuster-Hauser syndrome) is more often reported in association with uterine (absent or anomalous uterus), renal (34% of cases) or deformities in 12%-50% of the cases [2].

The symptomatology, generally appearing between age 9-15, is essentially represented by abdominal pain, urinary tract involvement, dysuria, pollakiuria, urine retention, low back pain and, naturally, primary amenorrhea.

The painful abdominal symptomatology is referred for 3-4 months before and is cyclic due to hematocolpos and sometimes even to hematometra with reproductive tract involvement. This marginal distention is responsible, with a low frequency, for the compression of the sacral plexus and consequently pain in the lower back as well.

It is the same for the urinary tract: dysuria and the eventual retention of urine are responsible for compression of the urethra and the cervical vesicle.

A rare case has been reported by Lopez Lopez *et al.* [1] who treated a young girl operated on during adolescence for bilateral ureterohydronephrosis with reconstruction and bilateral reimplantation of the ureters.

It is remarkable that this was not a case of imperforated hymen, but rather a high vaginal septum.

Many instrumental and laboratory tests have been reported in the literature [5] as diagnostic tools for hematocolpos; these tests are necessary for the frequent pathologies associated to the deformity (endoscopic and ultrasonographic tests, TAC, RMN).

Therapy is only surgical with a crucial incision of the hymen and evacuation of the vaginal content in variable quantities (400-1300 ml).

Case report

We observed a 13-year-old girl with low abdominal pain; the pain also involved the postero-lumbosacral area. She had vulvo-vaginal tension and urine retention.

Upon examination the patient presented an imperforated hymen and a large protusion of the hymen produced by great internal pressure. This tension was due to an hematocolpos due to menarche. The hymen's structure was dense; edematous and turgid.

Rectal exploration was negative for evaluation of the internal genital globe and at the same time there was swelling with indistinguishable limits of elastic spastic consistency along the vaginal canal axis.

A central semilunar incision was made on the hymen and, consequently, about 400 cc of blood, one part liquid and another part thrombosed, was drained.

Next an "orlatura" suture of the refreshed margins from hymenectomy was done with vicryl material with low resorption in order to avoid the junction of the above margins.

After the operation the symptoms were alleviated, especially the urinary ones.

Discussion

The observed case follows the characteristics reported in the literature about the imperforation of the hymen.

Because of the age of the patient (13-years-old), the primary amenorrhea and the retention of urine, we first proceeded with a clinical inspection of the vulvo-vaginal region.

The protrusion and the extreme distention of the imperforated hymen avoided having to do other tests.

Incision of the hymen and releasing about 400 cc of blood (part thrombosed), resolved the case.

Revised manuscript accepted for publication February 3, 1999

Fig. a

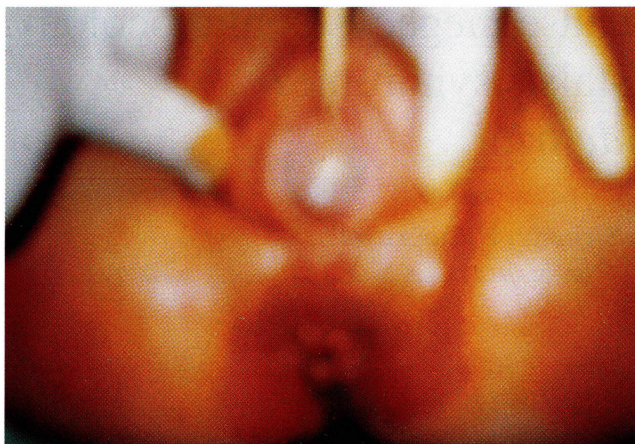


Fig. b

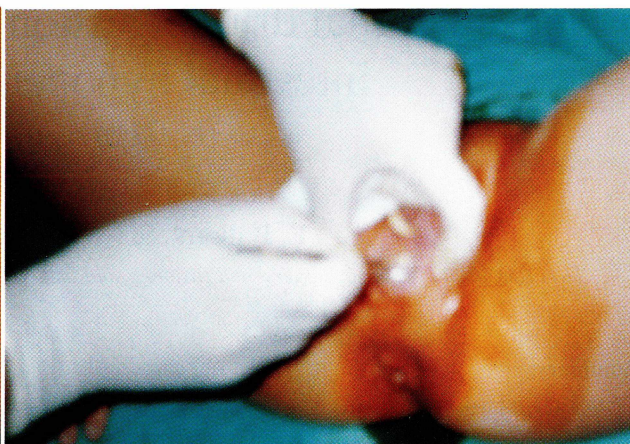

Fig. c

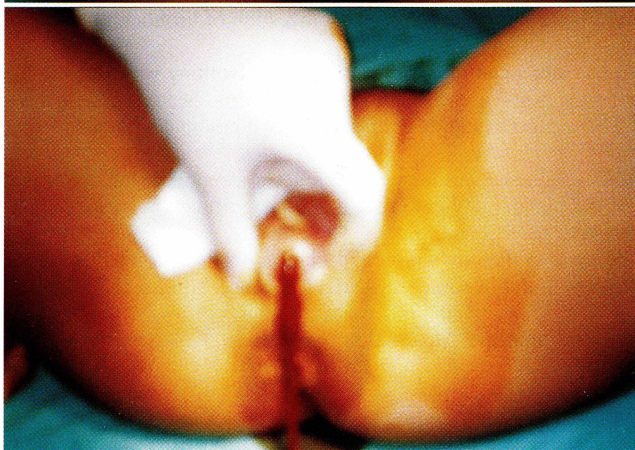

Fig. d

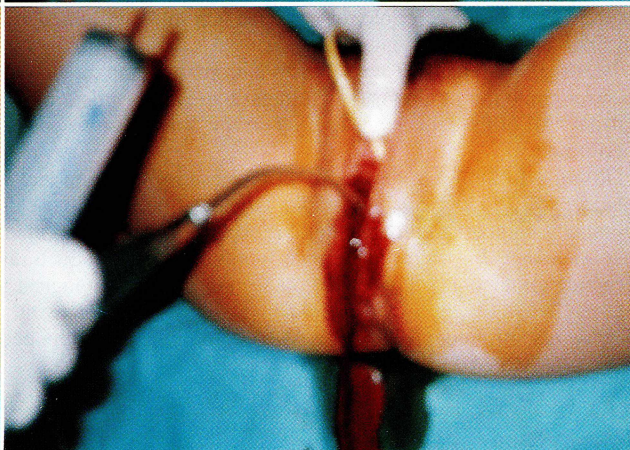


Figure a) Hematocolpos before surgery; b) incision of hymen; c) Aspiration of blood collected in vaginal canal; d) mechanical aspiration of residual blood.

References

- [1] Dickson C. A., Saad S., Tesar J. D.: "Imperforated hymen with hematocolpos". *Ann. Emerg. Med.*, 142, 467, 1985.
- [2] Griffin J. E., Edwards C., Madden J. D., Harrod M. J.: "Congenital absence of the vagina. The M.R.K.H. syndrome". *Ann. Intern. Med.*, 85, 224, 1976.
- [3] Koff A. K.: "Development of the vagina in the human fetus". *Contrib. Embryol.*, 140, 61, 1933.
- [4] Lopez Lopez J. A., Murillo Perez C., Rosa Arias J., Abril Baquero G.: "Urinary retention caused by hematocolpos secondary to imperforated hymen". *Arch. Esp. Urol.*, 46(8), 732, 1993.
- [5] Robberecht E., Smets A., Winckel M. V., Delens F.: "Radiological case of the month. Hematometocolpos due to imperforated hymen". *Arch. Pediatr. Adolesc. Med.*, 150(9), 993, 1996.
- [6] Roxanne M., Sanders B. S., Steven T., Nakajima M. D.: "An unusual late presentation of imperforated hymen". *Obstet. Gynecol.*, 83(5), 896, 1994.
- [7] Van Bommel P. J., Abdullo O.: "Imperforated hymen as a cause of urinary obstruction". *Trop. Doct.*, 26(3), 133, 1996.
- [8] Ward A., Maher P.: "Haematocolpos. An unusual presentation". *Br. J. Clin. Pract.*, 33, 83, 1979.

Address reprint requests to:
SANTAGATA MARCO, M.D.
Via Posillipo, 302
Napoli (Italy)