

# Pseudoxanthoma elasticum and pregnancy: a case report

M. Valenzano, M.D.; A. Corticelli, M.D.; M. Podestà, M.D.; L. Nicoletti, M.D.;  
S. Saffioti<sup>1</sup>, M.D.; L. Derchi<sup>2</sup>, M.D.

Department of Obstetrics and Gynecology, Genova University, S. Martino Hospital

<sup>1</sup>Department of Internal Medicine Nephrology Institute, Genova University, S. Martino Hospital

<sup>2</sup>Institute of Radiology, Genova University, S. Martino Hospital, Genova (Italy)

## Summary

**Background:** Pseudoxanthoma elasticum (PXE) is a rare hereditary disease characterised by systemic degeneration of elastic tissue. Calcification of elastic fibres seen histologically is pathognomonic for the disorder.

Most pseudoxanthoma elasticum patients show no serious complications during pregnancy.

**Case:** We report a case of a 29-year-old white woman with pseudoxanthoma elasticum, who delivered a healthy infant at the 35th week by cesarean section after an uneventful pregnancy. Sonographic and histological placental findings are described.

**Conclusion:** Pregnancy in a patient with pseudoxanthoma elasticum presents some problems such as the evolution of the disease in the soon to be mother and the influence of the disease on the pregnancy. In our case there were no fetal-maternal complications related to the disease except skin lesion aggravation.

**Key words:** Pseudoxanthoma; Elastic tissue.

## Introduction

Pseudoxanthoma elasticum (PXE) is a rare form of inherited dystrophy of the elastic tissue first described in 1896 [1] and reported in most countries and racial groups. Its incidence varies from 1/70,000 to 1/160,000 [2].

There are four different genetic types (I or II, dominant or recessive), which correspond to four clinical forms [3], as shown in Table 1.

Multiple body systems are involved but principally skin, small and medium-sized arteries and Bruch's membrane of the retina [4]. Characteristic fragmentation and calcification of elastic fibres seen histologically is pathognomonic for the disorder.

The cutaneous features are yellow macules and papules ("plucked chicken-skin", "cobblestones") predominantly affecting the flexural areas and skin laxity [5].

Arterial degeneration leads to cerebral, coronary and peripheral vascular disease, the weakness of the splanchnic arteries predisposes the patient to gastrointestinal bleeding. Arterial calcification, hypertension and myocardial infections have been reported [2-5].

The vascular damage caused by the illness generally limits the obstetric prognosis, due to elastic tissue degeneration in the internal lamina of the arteries which causes luminal obstruction.

There are some reports of complications occurring in patients with pseudoxanthoma elasticum during pregnancy. Serious gastrointestinal bleeding, ruptured aneurysm, hypertension and intrauterine growth retardation are most often described [2-6].

Despite these reports there are many women with PXE who have uneventful pregnancies and normal deliveries.

In this case report we describe an uneventful pregnancy in a patient with pseudoxanthoma elasticum and hypertension.

## Case

A 29-year-old white woman recalled skin lesions on her neck beginning at the age of nine.

At age 15, a skin biopsy was performed and a diagnosis of pseudoxanthoma elasticum was established. At this time mild ocular involvement was detected. Abdominal pain was recurrent and she had proteinuria with microhematuria on one occasion.

At age 20 she developed hypertension treated with ACE-I.

Three years later angioid streaks in the retina and venous congestion were seen.

Thus sonography of the kidneys was performed: both organs had normal volume and presented many diffuse hyperechoic spots at the level of the interlobar and arcuate arteries. Pulsed Doppler evaluation of the renal blood flow showed normal waveforms both at the renal hilum and in the interlobar arteries.

At age 29 she was admitted to our hospital for a clinical evaluation and she was found to be at the beginning of a pregnancy. She had had two pregnancies voluntarily interrupted in the first trimester.

She was followed throughout her pregnancy with the usual laboratory values and physical evaluations; several fetal ultrasonographic examinations demonstrated a normal symmetrical pattern of intrauterine growth of the fetus (Table 2).

The pulsatility index value of the umbilical and uterine arteries during the course of pregnancy are shown in Table 2.

Table 1. — Fetal growth and Doppler parameters during pregnancy.

Week	21st+1d	27th+1d	29th+ d	32nd+5d
BPD	53	72	77	82
CC	19.2	25	27.4	28
CA	17.5	23	24	27
FE	41	54	60	65
PI Umb. Artery	1.7	0.86	1.09	0.948
PI Ut. Artery (dx)	0.865	0.714	0.566	0.544

Revised manuscript accepted for publication August 18, 2000

Table 2. — Genetic and clinical forms of pseudoxanthoma elasticum (Lapière, 1990).

Type	Hereditry	Clinic
D1	AD*	Marked orange skin Frequent vascular alterations Occasional angiod streaks
D2	AD*	Occasional orange skin and hyperelasticity Frequent angiod streaks Myopia Frequent sclerotic bruises
R1	AR+	Marked orange skin Frequent angiod streaks and choroiditis
R2	AR+	Diffuse orange skin

AD\* = Autosomic dominant; AR+ = Autosomic recessive.

The patient had good hypertensive control on a regimen of 40 mg of nifedipina daily up to the 22nd week, 20 mg daily for the next two weeks, and then without any treatment.

At the 26th week the patient demonstrated an aggravation of the skin symptoms, which also involved the abdominal area.

At the 27th week the ultrasonographic appearance of the pla-

centa was abnormal showing diffuse hyperechogenic areas similar to those in the maternal kidneys (Figures 1, 2).

Then the patient was checked clinically and by ultrasonography (Figures 3, 4) at regular intervals and the pregnancy seemed uncomplicated until the programmed delivery at the 35th week, resulting in the birth of a male infant, weighing 2,600 g with Apgar scores of 9 and 7. There was no intrapartum fetus distress nor complications associated with prematurity. The placental plate was oval (18.7 x 16.2 cm), weighed 480 g with a funiculus of 34 cm in length, eccentrically inserted.

The placenta, processed following the general pathologic criteria, was macroscopically examined; it was then cut in parallel sections at 2 cm intervals showing marginal sclerosis and marked calcifications in the marginal zone and the apical portions of the fetal cotyledons. At the microscopic examination villi were increased in density and immature with no significant alterations in the trophoblastic component. Furthermore some small fibrinoid deposition in the intervillous spaces and around the stem and intermediate villi were found, sometimes with microcalcifications. Arteries of rami chorii of the second to fourth order showed subendothelial thickness, in some instances calcified. Weigherstain showed a marked decrease in elastic fibers in all small and large caliber vessels.

Today the child is healthy with a normal growth.

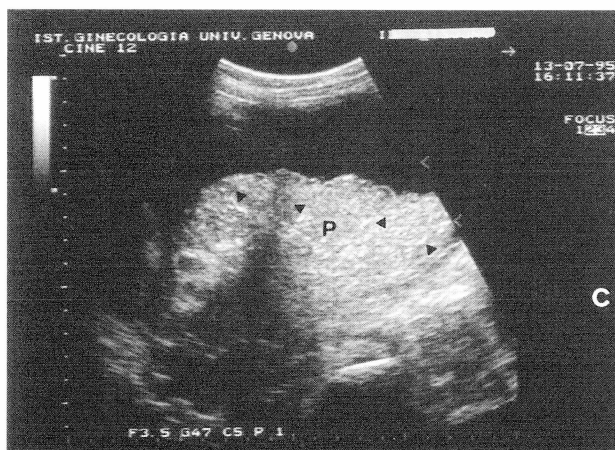


Figure 1. — Ultrasonographic appearance of the placenta at the 26th week showing diffuse hyperechogenic areas (P: Placenta).

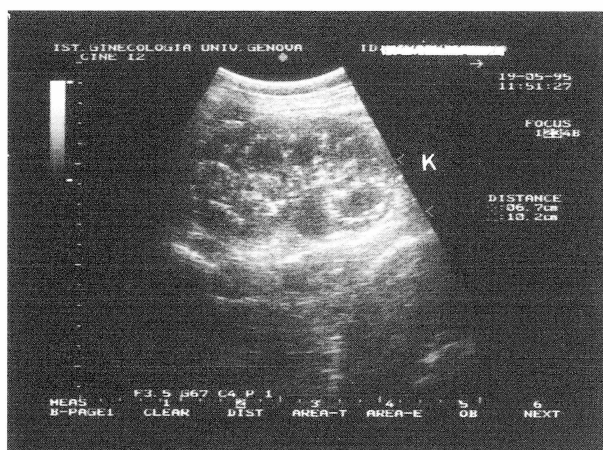


Figure 2. — Ultrasonographic appearance of maternal kidney showing fine hyperechogenic spots suggesting small calcifications (K: Kidney).

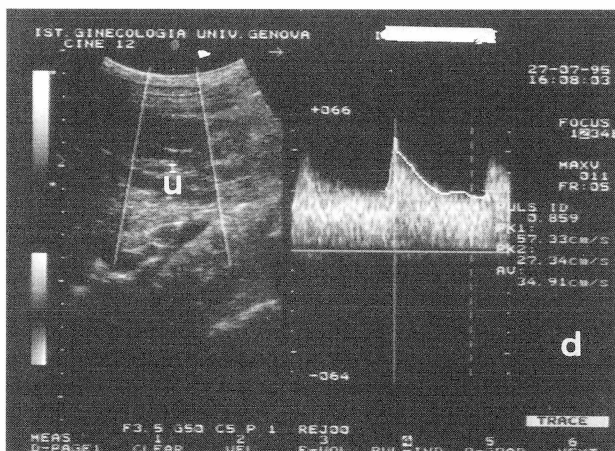


Figure 3. — Doppler evaluation of uterine artery at the 28th week showing normal velocimetry pattern.

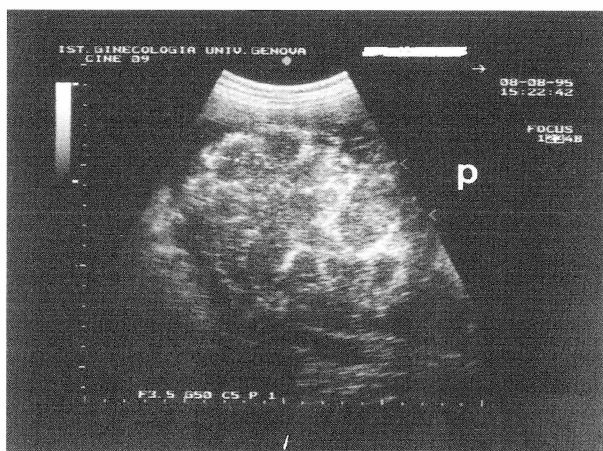


Figure 4. — Ultrasonographic appearance of the placenta at the 29th week showing numerous calcifications (P: Placenta).

## Discussion

The relationship between pseudoxanthoma elasticum and pregnancy is difficult to define especially because of the scanty available data in the literature.

Pregnancy in a patient with PXE presents some problems. Evolution of the disease can influence the pregnancy and there is a risk of fetal transmission.

However, in some studies pregnancy was positively correlated with many complications of pseudoxanthoma elasticum, including percentage of body area affected, severity of retinopathy, hypertension, cardiovascular disease and, for the fetus, intrauterine growth retardation [1, 7].

Other studies have affirmed that there were no significant adverse intrauterine effects caused by the disease [8, 9].

In our case there was only an aggravation of skin lesions involving typically the abdominal area; the spreading of cutaneous lesions in the abdominal area has often been observed during pregnancy [2, 5, 10, 11].

There were no other maternal complications related to the disease. Particularly also the pre-existing hypertension showed no significant changes in our patient, being well controlled by nifedipina, and this data seems to disagree with the physiopathology of the disease [12].

It is interesting to point out that there was no indication of abnormal maternal uterine or gastrointestinal bleeding, suggesting that these might be over-reported in the literature when compared with normal pregnancy [5].

On the other hand placental calcifications are considered by many authors as a typical expression of the disease during pregnancy, probably due to disintegration into fragments and calcification of elastic tissue in the tunica media of the greater arteries; also hypothetic dysregulation of calcium metabolism can occur.

Our patient's placenta was heavily calcified but during pregnancy there was no alteration of uterine-placental flow and she delivered a healthy infant.

In a previous work [2] placental alterations in pseudoxanthoma elasticum were described but no significant or specific findings were found. The finding of a marked calcification increase seems only to be nonspecific.

The relative immaturity of the villi on the contrary seems to be relevant in relation to dystrophic alterations and mainly to calcification and degenerative vascular lesions.

Therefore we agree with Yoles *et al.* [5] who affirm that calcification of the placenta is common and is not a specific sign of pseudoxanthoma elasticum, although the degree of calcium is striking.

A possible association between pseudoxanthoma elasticum and intrauterine growth retardation has been already reported in the literature [1, 13] and has been explained by vascular alterations caused by the pseudoxanthoma elasticum. In our report the fetal growth was regular and symmetric showing good adaptation of the uterine-placental system with a progressive reduction of the RI index, but always limited to the standards used in our hospital.

However, further investigations are needed to demonstrate that the disease does not interfere with fetal growth and birth weight.

The risk of fetal transmission of pseudoxanthoma elasticum is real and must be established, when possible, by careful genetic counselling aimed at identifying the genetic type.

It is unclear from the existing data what kind of autosomal inheritance is more common and this fact could be explained by simple differences in the description of skin lesions [5, 14, 15]. Our patient was the holder of recessive type I and in this case the risk of transmission is negligible.

The recent introduction of an Internet register (<http://pxe.org/research.html>), designed to better understand PXE and how it progresses, will be very helpful in obtaining new knowledge, especially in the obstetric field.

## References

- [1] Broekhuizen F. F., Hamilton P. R.: "Pseudoxanthoma elasticum and intrauterine growth retardation". *Am J Obstet Gynecol* Jan, 1984, 1, 112.
- [2] Mansat-Krzyzanowska E., Sagot P., Le Neel N., Stalder J. F.: "Pseudoxanthome élastique et grossesse". *Ann Dermatol Venerol*, 1993, 120, 391.
- [3] Pope F. M.: "Historical evidence for the genetic heterogeneity of pseudoxanthoma elasticum". *Br J Dermatol*, 1975, 92, 493.
- [4] Mallette L. E., Mechanick J. I.: "Heritable syndrome of pseudoxanthoma elasticum with abnormal phosphorus and vitamin D metabolism". *Am J Med*, 1987, Review, 83 (6), 1157.
- [5] Yoles A., Phelps R., Lebwohl M.: "Pseudoxanthoma elasticum and pregnancy". *Cutis*, 1996, 161.
- [6] Berde C., Willis D. C., Sandberg E. C.: "Pregnancy in women with pseudoxanthoma elasticum". *Obstet Gynecol Surv*, 1983, 38 (6), 339.
- [7] Nelder K. H.: "Pseudoxanthoma elasticum". *Int J Dermatol*, 1988, 27 (2), 98.
- [8] Baratte I., Schaal J. P., Laurent R.: "Association pseudoxanthome élastique et grossesse". *Rev fr Gynécob Obstét*, 1991, 86 (3), 243.
- [9] Bork K.: "Pseudoxanthoma elasticum in pregnancy: effects on mother and child". *Hautarzt*, 1983, 34 (2), 77.
- [10] Barriere H., Berger M., Stalder J. F., Le Monnier J. Y., Lammens J.: "Pseudoxanthome élastique et grossesse". *Ann Dermatol Venerol*, (Paris) 1980, 107, 817.
- [11] Viljoen D. L., Beatty S., Beighton P.: "The obstetric and gynaecological implications of pseudoxanthoma elasticum". *Br J Obstet Gynaecol*, 1987, 94 (9), 884.
- [12] Crespi M. G., Derchi L. E., Saffioti S.: "Sonographic detection of renal changes in pseudoxanthoma elasticum". *Urol Radiol*, 1992, 13, 223.
- [13] Elejalde B. R., Elejalde M. M., Samter T., Burgess J., Lombardi J., Gilbert E. F.: "Manifestations of pseudoxanthoma elasticum during pregnancy: a case report and review of literature". *Am J Med Genet*, 1984, 18 (4), 755.
- [14] McKusick V. A.: "Heritable disorders of connective tissue". 4th ed, St Louis, CV Mosby, 1972, 475.
- [15] Lao T. T., Walters B. N. J., DeSwiet M.: "Pseudoxanthoma elasticum and pregnancy. Two case reports". *Br J Obstet Gynaecol*, 1984, 91, 1049.

Address reprint requests to:  
M. VALENZANO, M.D.  
Department of Obstetrics and Gynecology  
Genova University  
S. Martino Hospital  
Largo R. Benzi, 10  
16132 Genova (Italy)