

# Neonatal magnetocardiography

**P. G. Anastasiadis<sup>1</sup>, Prof.; P. Anninos<sup>2</sup>, Prof.; A. Kotini<sup>2</sup>, Lecturer; N. Koutlaki<sup>1</sup>, M.D.;  
A. Garas<sup>1</sup>, M.D.; G. Galazios<sup>1</sup>, Ass. Prof.**

<sup>1</sup>Department of Obstetrics and Gynaecology and <sup>2</sup>Laboratory of Medical Physics, Medical School,  
Democritus University of Thrace, Alexandroupolis (Greece)

## Summary

**Purpose:** The aim of the present study was to test the validity of magnetocardiography (MCG) in the estimation of neonatal cardiac rhythm using a single channel superconductive quantum interference device (SQUID).

**Materials and Methods:** Our study population consisted of 50 neonates who were delivered normally between 37-41 weeks of gestation from clinically uncomplicated pregnancies. There was also a neonate included in the study in which the diagnosis of "hypoplastic left heart syndrome" was demonstrated by U/S Doppler examination. Maternal age ranged from 18 to 39 years (mean=29.15, SD=6.13).

**Results:** Our study results revealed 44 neonates with normal cardiac rhythm, four with ventricular tachycardia (VT), one with ventricular tachycardia (VT) and extrasystolic beats and one with bradycardia. The neonate with the hypoplastic left heart syndrome presented frequent episodes of ventricular bigeminy in the magnetocardiographic trace. M-mode echocardiography confirmed the diagnosis of the seven cases of arrhythmia in our study group.

**Conclusion:** Results gained from the study lead us to believe that MCG could provide clinical practice with a non-invasive, rapid and easy to perform method, which could be used as an adjunct to conventional methods for the evaluation of neonatal cardiac rhythm.

**Key words:** Magnetocardiography; Neonates; Arrhythmia; Normal cardiac rhythm.

## Introduction

Cardiobiomagnetism is the study of magnetic signals originating from the human heartbeat. As these signals are extremely weak, high sensitivity instruments, the superconducting quantum interference devices (SQUIDs) are used for detection. The whole detector system operates in a magnetically-shielded room. Magnetocardiography (MCG) is a promising, completely noninvasive method to obtain functional information about electrical activation in the human heart. The electrophysiological activity is associated with a magnetic field detectable without contact to the body surface. In 1986 Roth and Wikswo [1] presented calculations of a theoretical example of electrically silent magnetic fields. They showed that for tissues with an assumed complex conductivity, some information was lost in the electric potential, but was detectable with a biomagnetic sensor. Van Oosterom and co-workers [2] concluded from measurements and simulations of MCG and ECG that, for the ventricular depolarization, the contribution of electrically silent magnetic fields is only marginal. In contrast MacAuley *et al.* [3] suggested that MCG signals of the QRS offer information that is not available with the ECG.

Although MCG has been known for almost 30 years [4, 5] its clinical use has been limited to localize myocardial conditions such as Wolff-Parkinson-White (WPW) syndrome [6], ventricular tachycardia (VT) [7] and myocar-

dial ischaemia in adults [8, 9]. It has also been reported as a useful method for determining an accessory pathway in children with a congenital heart defect [10]. The magnetocardiographic investigation of patients with WPW syndrome, ventricular extrasystoles, VT and paced ventricular arrhythmias demonstrated that MCG permits a non-invasive localization of arrhythmogenic tissue with high spatial accuracy [6, 7, 9, 11].

To our knowledge there are no reports in the literature concerning the efficacy of MCG in the estimation of neonatal cardiac rhythm, thus the goal of this study was to investigate the validity of MCG in the estimation of neonatal normal and pathological heart rate.

## Materials and Methods

Our study population consisted of 54 neonates who were delivered normally between 37-41 weeks of gestation from clinically uncomplicated pregnancies. Maternal age ranged from 18 to 39 years (mean=29.15, SD=6.13). In three of the 54 neonates it was not possible to measure the MCG signals due to technical reasons.

The MCG was recorded digitally for 10 min by a single channel biomagnetometer (DC-SQUID model 601, USA) [12]. The SQUID gradiometer operates at a low liquid helium temperature of 4° K on the basis of the Josephson effect of superconductivity [13]. In order to minimize the incidence of stray electromagnetic variations, recordings were taken in an electrically-shielded room of low magnetic noise. We digitized the signals using a 12-bit precision analog to digital converter with a sampling frequency of 256 Hz. The MCG signals were band-

pass filtered with cut-off frequencies of 0.1-100 Hz. The associated Nyquist frequency limit with the above-mentioned sampling frequency is 128 Hz, which is well above the constituent frequency components of interest in MCG recordings and avoids artifacts. The tip of the single channel biomagnetometer was placed 2-3 cm above the infants' heart at the position where the QRS signal was found to be at its maximum.

The rules of the Helsinki Declaration were followed: parents were fully informed and a written consent was obtained for each newborn. The local ethics committee was notified and approved of this study. Throughout the entire period of measurement, a sleep state analysis was carried out, focusing on quiet sleep. Closed eyes, absence of body and eye movements and a prevailing muscle tone defined quiet sleep states.

Biomagnetic recordings were obtained on the second day after birth to avoid the influence of the pharmacological treatment of the pregnant women during gestation. All infants breathed spontaneously during the measurements. The measurements began at 11:00 am~1 h after the last feeding. The biomagnetometer allows on-line determination of the R-R intervals. After the R-R interval is determined, the segment of the digitally recorded MCG signal is compressed and stored together with the R-R interval for later off-line analysis. The individual R-R intervals that deviated > 60% from the time series mean were removed and the segments from the beginning or end of the tracing where nonstationarity was existence, were cut out. These criteria were chosen so that the respiratory rate of the free breathing infants would be as regular as possible.

## Results

Our study results revealed 44 neonates with normal cardiac rhythm, four with VT, one with VT and extrasystolic beats and one with bradycardia. The neonate with the hypoplastic left heart syndrome presented frequent episodes of ventricular bigeminy in the magnetocardiographic trace. M-mode echocardiography confirmed the diagnosis of the seven cases of arrhythmia in our study group. The neonates who presented pathologic cardiac rhythms were under close cardiologic examination with M-mode echocardiography for a period of two months.

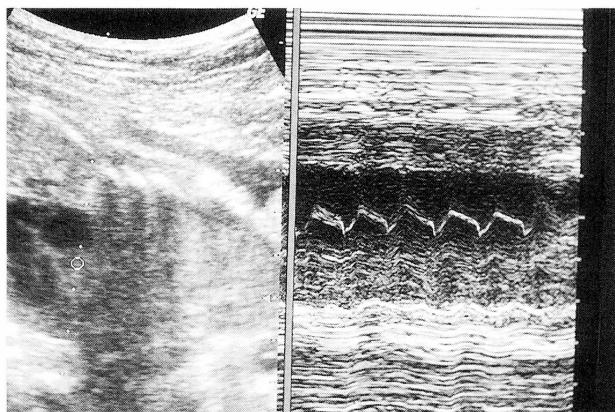


Figure 1. — Two-dimensional images: M-mode tracing of a neonate. The rhythm is normal. The right hand picture shows the orientation of the M-mode axis.

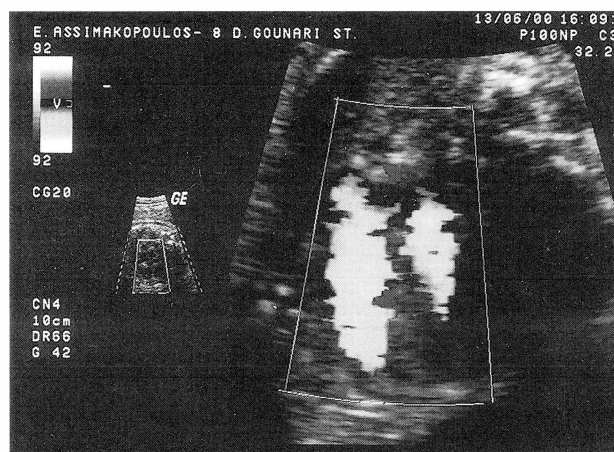


Figure 2. — Hypoplastic left ventricle in color Doppler appearance.

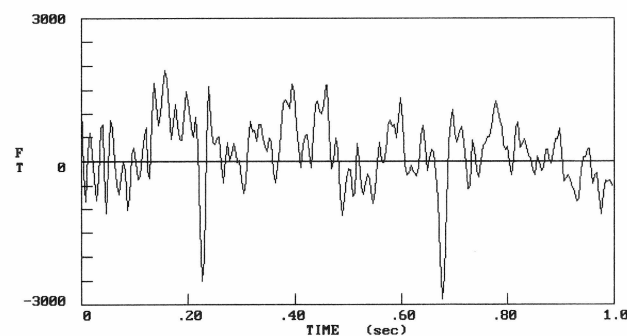


Figure 3. — A normal neonatal MCG recording. Ventricular rate: 120/min (2 QRS complexes per sec).

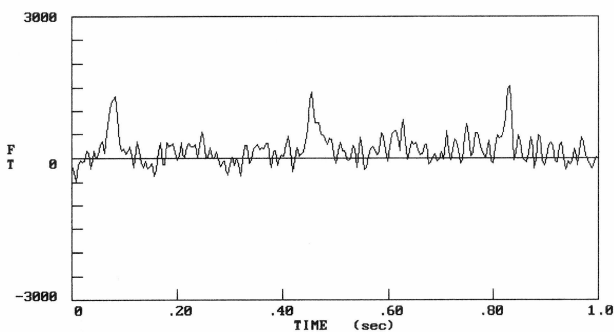


Figure 4. — MCG recording presenting neonatal VT. Ventricular rate: 180/min (3 QRS complexes per sec).

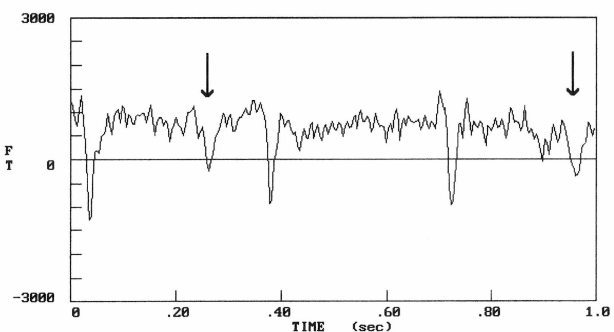


Figure 5. — A neonatal MCG recording presenting VT with extrasystoles. The arrows show the extrasystoles. Ventricular rate: 180/min (3 QRS complexes per sec).

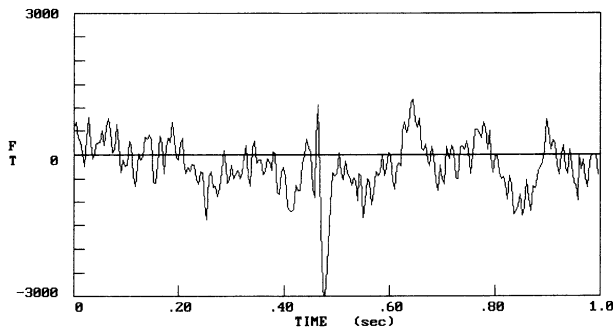


Figure 6. — MCG recording presenting neonatal bradycardia. In a one-second period there is only one QRS complex (60/min).

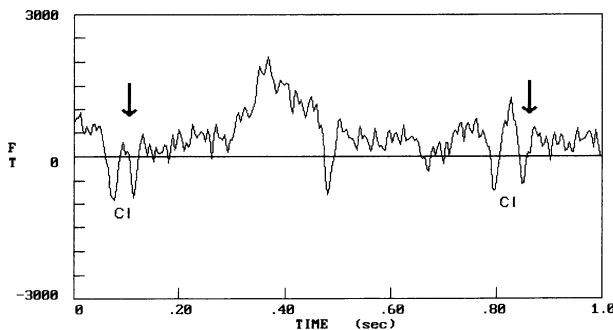


Figure 7. — MCG recording presenting episodes of ventricular bigeminy in the neonate with the hypoplastic left heart syndrome. Stable coupling interval (CI) for the same rate.

The arrhythmia disappeared 7-10 days after delivery whereas the neonate with the hypoplastic left heart syndrome died on his 10<sup>th</sup> day of life. M-mode echocardiographic recordings of the cardiac motion with time were obtained using a single M-mode sampling line (Figure 1). Figure 2 shows the hypoplastic left ventricle in color Doppler appearance. Figure 3 presents a recording obtained from a newborn with a normal heart rate (120/min). Figure 4 shows the magnetic recordings from a neonate with VT (180/min), whereas Figure 5 presents a magnetocardiogram with VT and extrasystolic beats (180/min). Figure 6 shows the magnetic recordings from the neonate with bradycardia where in 1-sec duration intervals there is only one QRS complex (60/min). The neonate with the hypoplastic left heart syndrome presented frequent episodes of ventricular bigeminy in the magnetocardiographic trace (Figure 7).

## Discussion

A number of studies reported in the past refer to certain advantages which MCG offers compared to other diagnostic techniques such as M-mode echocardiography, two dimensional imaging, pulsed Doppler and color flow Doppler [11, 12, 14-18]. All the above-mentioned studies confirm the diagnostic accuracy of MCG, especially regarding functional heart disorders like cardiac arrhythmias.

Fenici *et al.* [19] were the first to report successful MCG localization of a sustained VT. Several authors have demonstrated that MCG is useful for the non-invasive investigation of clinical arrhythmias and for the identification of patients at risk for sudden death through the detection of magnetic fields. The detection of serious arrhythmias is of a great importance, especially in patients at risk for sudden death. Thus any new reliable non-invasive method with predictive accuracy has potential importance. MCG provides a method of investigating normal and abnormal cardiac rhythms with high temporal and spatial resolution, applicable in the last decade. Its accuracy and reliability has been established with electrophysiology and cardiac pacing [14]. Fujino *et al.* [20] have reported a higher sensitivity of the MCG as compared to the ECG in the detection of left ventricular hypertrophy. Makijarvi *et al.* [21] concluded that MCG mapping provides accurate localization of overt atrioventricular accessory pathways and some atrial arrhythmias, as focal atrial tachycardia, can probably be localized by MCG mapping.

Ventricular arrhythmias in the neonate may be simple or complex, ranging from isolated premature ventricular contractions (PVCs) to VT. Due to the very low incidence of sudden cardiac death in the neonate, ventricular arrhythmias have received limited attention. Since these arrhythmias may be the presenting feature of either structural heart disease or ventricular dysfunction in very young children more attention is required by the pediatric specialist. In neonates with PVCs or VT the QRS complex may not be particularly "wide" (0.06-0.11 s) as the small heart size allows relatively synchronous ventricular activation in spite of abnormal depolarization [22]. Except for the QRS duration, the following have been proposed as ECG criteria for ventricular ectopic beats or tachycardia in neonates: a) the QRS complex appears before the next expected normal ventricular complex; b) the premature QRS complex is different in morphology from normal sinus rhythm; c) the QRS complex is not preceded by a premature atrial depolarization; and d) there are repolarization abnormalities with T waves opposite in polarity to the QRS complex [23]. Ventricular bigeminy is characterized by a pattern in which PVC alternates with each normal QRS complex. VT is defined by the occurrence of at least three consecutive abnormal QRS complex beats with different morphology from the normal sinus rhythm and is sustained if it lasts more than 30 sec with a rate at least 20% greater than the average sinus rate [22]. Sinus bradycardia is a rhythm originating from the sinus node, with a rate that is slower than expected for age. Studies of the heart rate in healthy full term neonates report that the lower limits of normal heart rate in neonates are 60/min while asleep and 80/min while awake [24, 25]. The above criteria for all types of arrhythmias are followed in Figures 4-7.

Though our results cannot be compared to any other reports, we believe that MCG helps a lot in the detection of neonates whose cardiovascular system should be sub-

mitted to closer investigation. In conclusion we believe that MCG could provide a non-invasive, rapid and easy-to-perform method for detecting neonatal arrhythmias. Of course, more studies in large series of infants and further technological innovation of the equipment used need to be done before the method is established as a screening procedure in clinical practice.

## References

- [1] Roth B. J., Wikswo J. P. Jr.: "Electrically silent magnetic fields". *Biophys J.*, 1986, 50, 739.
- [2] Van Oosterom A., Oostendorp T. F., Huiskamp G. J., ter Brake H. J.: "The magnetocardiogram as derived from electrocardiographic data". *Circ. Res.*, 1990, 67, 1503.
- [3] MacAuley C. E., Stroink G., Horacek B. M.: "Signal analysis of magnetocardiograms to test their independence". In: Weinberg H., Stroink G., Katila T. eds: "Biomagnetism: Applications and Theory". Pergamon Press, New York, 1985, 115.
- [4] Baule G. M., McFee R.: "Detection of the magnetic field of the heart". *Am. Heart J.*, 1963, 66, 95.
- [5] Cohen D., Edelsack E. A., Zimmermann J. E.: "Magnetocardiograms taken inside a shielded room with a superconducting point-contact magnetometer". *Appl. Phys. Lett.*, 1970, 16, 278.
- [6] Weismüller P., Abraham-Fuchs K., Schneider S., Richter P., Kochs M., Edrich J., Hombach V.: "Biomagnetic noninvasive localization of accessory pathways in Wolff-Parkinson-White Syndrome". *PACE*, 1991, 14, 1961.
- [7] Müller H.-P., Godde P., Czerski K., Agrawal R., Feilcke G., Reither K. et al.: "Localization of a ventricular tachycardia-focus with multichannel magnetocardiography and three-dimensional current density reconstruction". *Journal of Medical Engineering and Technology*, 1999, 23, 108.
- [8] Saarinen M., Karp P. J., Katila T. E., Siltanen P.: "The magnetocardiogram in cardiac disorders". *Cardiovasc. Res.*, 1974, 8, 820.
- [9] Killmann R., Jaros G. G., Wach P., Graumann R., Moshage W., Renhardt M., Fleischmann P. H.: "Localization of myocardial ischaemia from the magnetocardiogram using current density reconstruction method: computer simulation study". *Medical & Biological Engineering & Computing*, 1995, 33, 643.
- [10] Nenonen J., Rovamo L., Toivonen L., Ilmoniemi R., Jarvinen A., Leinonen M. et al.: "Magnetocardiographic localization of ventricular pre-excitation in a child with a congenital heart defect". *Pediatr. Cardiol.*, 1995, 16, 33.
- [11] Moshage W., Achenbach S., Gohl K., Bachmann K.: "Evaluation of the non-invasive localization accuracy of cardiac arrhythmias attainable by multichannel magnetocardiography (MCG)". *International J. of Cardiac Imaging*, 1996, 12, 47.
- [12] Anastasiadis P., Anninos P., Lüdinghausen M., Kotini A., Galazios G., Liberis V.: "Fetal magnetocardiogram recordings and Fourier spectral analysis". *J. of Obstetrics and Gynecol.*, 1999, 19, 390.
- [13] Josephson B.: "Possible new effects in superconducting tunneling". *Physics Letters*, 1962, 1, 251.
- [14] Stroink G.: "Principles of cardiomagnetism". In: Williamson S. J., Hoke M., Stroink G., Kotani M. eds. "Advances in Biomagnetism". New York, Plenum Press, 1989, 47.
- [15] Fenici R. R., Melillo G.: "Biomagnetic study of cardiac arrhythmias". *Clin. Phys. Physiol. Meas.*, 1991, 12, Suppl A, 5.
- [16] Fenici R. R., Melillo G.: "Magnetocardiography: ventricular arrhythmias". *European Heart Journal*, 1993, 14 Suppl E, 53.
- [17] Mochage W., Achenbach S., Weikl A., Gohl K., Abraham-Fuchs K., Schneider S., Bachmann K.: "Progress in biomagnetic imaging of heart arrhythmias". In: Baert A. L., Heuck F. H. W. (Eds). "Frontiers in European Radiology". Springer Verlag, Berlin, Heidelberg, 1991, vol. 8, 1.
- [18] Wakai R. T., Leuthold A. C., Wilson A. D., Martin C. B.: "Association of fetal junctional rhythm and respiratory arrhythmia detected by magnetocardiography". *Pediatr. Cardiol.*, 1997, 18, 201.
- [19] Fenici R. R., Masselli M., Lopez L., Sabetta F.: "Simultaneous magnetocardiographic mapping and invasive electrophysiology to evaluate the accuracy of the equivalent current dipole inverse solution for the localization of human cardiac sources". *New trends in arrhythmias*, 1986, 2(2), 357.
- [20] Fujino K., Sumi M., Saito K., Murakami M., Higuchi T., Nakaya Y., Mori H.: "Magnetocardiograms of patients with left ventricular overloading recorded with a second-derivative SQUID gradiometer". *J. Electrocardiol.*, 1984, 17, 219.
- [21] Makijärvi M., Nenonen J., Toivonen L., Montonen J., Katila T., Siltanen P.: "Magnetocardiography: supraventricular arrhythmias and preexcitation syndromes". *European Heart Journal*, 1993, 14 Suppl. E, 46.
- [22] Yabek S. M.: "Ventricular arrhythmias in children with an apparently normal heart". *J. Pediatr.*, 1991, 119, 1.
- [23] Garson A. Jr., Smith R. T. Jr., Moak J. P., Kearney D. L., Hawkins E. P., Titus J. L. et al.: "Incessant ventricular tachycardia in infants: myocardial hamartomas and surgical care". *J. Am. Coll. Cardiol.*, 1987, 10, 619.
- [24] Southall D. P., Johnston F., Shinebourne E. A., Johnston P. G.: "24-hour electrocardiographic study of heart rate and rhythm patterns in population of healthy children". *Br. Heart J.*, 1981, 45, 281.
- [25] Montague T. J., Taylor P. G., Stockton R., Roy D. L., Smith E. R.: "The spectrum of cardiac rate and rhythm in normal new-borns". *Pediatr. Cardiol.*, 1982, 2, 33.

Address reprint requests to:  
P. G. ANASTASIADIS, Professor  
Department of Obstetrics and Gynaecology  
Democritus University of Thrace  
General Hospital of Alexandroupolis  
Dimitras 19  
Alexandroupolis 68100 (Greece)