

Liver and kidney ultrastructural changes caused by acetylsalicylic acid treatment during pregnancy in rats

S. Espiridião¹, M.D., Ph.D.; R. M. Oliveira-Filho², Ph.D.; M. J. Simões³, Ph.D.;
J.A.V. Mamede⁴, M.D., Ph.D.; L. Kulay Jr.³, M.D., Ph.D.

¹Fundação ABC School of Medicine; ²Dept. of Pharmacology, Institute of Biomedical Sciences, Univ. of Sao Paulo;
³Universidade Federal de Sao Paulo School of Medicine; ⁴Universidade de Mogi das Cruzes School of Medicine (Brazil)

Summary

The worldwide use of acetylsalicylic acid (ASA) as an analgesic-antipyretic drug, including during pregnancy, prompted us to investigate its potentially deleterious effects in that condition. Pregnant rats were treated with ASA (1, 10 or 100 mg/kg once a day) from the first day up to term pregnancy. No histological changes were noticed in maternal and fetal livers or kidneys when examined under light microscopy, but some definite dose-dependent effects of ASA were observed on electron microscopy examination. In livers and kidneys of pregnant rats treated with the highest doses of ASA we observed cytoplasmic derangement, mitochondrial cristolysis and abnormally shaped rough endoplasmic reticulum. Similarly, in foetal livers and kidneys from this group we observed degenerative cytoplasmic vacuoles and ballooned mitochondria with cristae derangement and myelin figures. Our data point out the fact that both maternal and foetal tissues can be importantly affected by ASA at the ultrastructural level, without overt signs of toxicity.

Key words: Rat pregnancy; Acetylsalicylic acid; Kidney; Liver

Introduction

Acetylsalicylic acid (ASA) shares with acetaminophen, dipyron and nonsteroidal antiinflammatory agents, efficacy for similar problems such as pain of musculoskeletal origin, fever, and mild to moderate headache. Since it is effective for such common complaints, and is available without prescription, ASA usage is widespread among pregnant women. Even though this drug has by far proven to be effective and relatively safe, its side-effects are still a matter of concern for the obstetrician. Besides common effects such as allergic-like symptoms in susceptible individuals, ASA can cause prolonged gestation and complicated deliveries [1] as well as antepartum and postpartum hemorrhages [2]. It can cross the placenta [3], thus causing deleterious effects on the neonate [4], although there is some dispute in this regard [5].

Morphological and functional alterations as those found in Reye's syndrome have been reported in human liver after high doses of ASA [6, 7]; severe alterations were also observed in the kidney [8-10].

Rat pregnancy is also affected by ASA. Rat embryos exposed *in utero* to ASA showed increased incidence of reabsorptions, malformations – especially of the skeleton and the central nervous system –, low weight and intrauterine deaths, besides low placental weights [11-13].

The consumption of 1% ASA in rat food was reported to cause hepatocyte alterations, including reduction of the rough and increase of the smooth endoplasmic reticulum, besides structural modifications of peroxysomes [14]. Similarly, the kidneys showed both ultrastructural [15] and functional [16] alterations.

Due to the over-the-counter availability and high consumption of ASA, in addition to the well-defined poten-

tial for deleterious effects of ASA on liver and kidney, we studied the effects of this drug administered in three dose levels during the entire period of rat pregnancy.

Materials and Methods

Female adult virgin, EPM-1 Wistar rats weighing about 200 g, under routine laboratory care, were mated in the proportion of two females for every male over 12 hr. Pregnancy was determined by the finding of spermatozoa in the vagina according to Hamilton and Wolfe [17]. Forty pregnant rats were then randomly divided into four groups and treated from the first up to the 20th day of gestation as follows: C, control group, treated with a 2% solution of carboxymethylcellulose in distilled water (ASA vehicle); A1, treated with ASA 1 mg/kg; A10, treated with ASA 10 mg/kg, and A100, treated with ASA 100 mg/kg. Drugs and drug vehicle were given once a day in a final volume of 1 ml.

At term (20th day) the animals were sacrificed by deep ether anesthesia. Maternal and fetal liver and kidney samples were taken upon laparotomy. Part of the material was immersed in Bouin's solution for further haematoxylin-eosin staining and light microscopy study. The remaining samples were immersed in a 2% glutaraldehyde solution and processed for electron transmission microscopy examination. An EM-900 model Zeiss electron microscope at 80 kV was used [see 18].

Results and discussion

Aspirin during gestation may be used for its antiplatelet activity in the management of hypertension induced by pregnancy [19, 20], but the matter of greater concern is its widespread and over-the-counter use as an analgesic and antipyretic agent [4].

Microscopic observations at both light and electronic levels showed that rat foetal or maternal livers and convoluted proximal tubules were not altered by ASA treatment in groups A1 and A10. This result may reflect, at least in part, the behaviour of the compartmental distri-

bution of ASA as an inverse function of its serum levels [21]. In fact, with the lowest dose employed herein (1 mg/kg) the peak serum concentration would be *ca.* 62 µg/ml, about 92.5% of which was bound to plasma proteins. With the 10 mg/kg dose the peak concentration would rise to 620 µg/ml, and the corresponding binding would fall to something around 63%. In both situations the amount of free drug available to tissue distribution might still be small enough in order to be non toxic in our experimental model.

However, when the highest dose is considered, not only would the amount of free drug be large enough to reach toxic levels, but also its plasma half-life would be markedly prolonged. In fact, in our A100 rats treated with an antiinflammatory dose of ASA [6], light microscopy revealed only minor structural changes, but at electron microscopy examination there were noticeable alterations. The hepatocytes showed irregular nuclei, most of them with euchromatin but several being heterochromatic; the rough endoplasmic reticulum (rER) was retracted and at a time dispersed, forming clusters in the cytoplasm. Lipid droplets could also be observed surrounding these clusters; mitochondria were somewhat faded (Figure 1). These morphological alterations could well be an expression of the metabolic actions of ASA, since uncoupling of oxidative phosphorylation has been shown in isolated liver mitochondria from rats treated with ASA (150 mg/kg) for seven days [22].

In the renal compartment, convoluted proximal tubules from A100 rats revealed highly disorganized lysosomes; a great number of rER and mitochondria were seen, most of them showing cristolysis (Figure 2).

With high ASA doses, elimination follows saturation kinetics, and small increases in the above doses that evoke first-order kinetics can result in disproportionate increases in plasma levels of salicylate [4, 23]. Even though during pregnancy there are increments of vole-

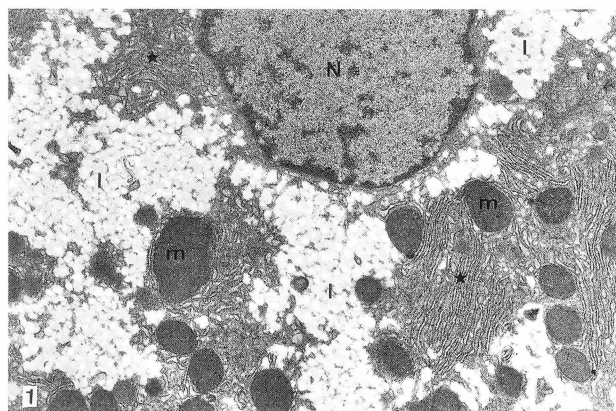


Figure 1. — Electronmicrography showing part of a hepatocyte of a term pregnant rat that had been treated with 100 mg/kg of acetylsalicylic acid during the entire period of pregnancy (group A100). The nucleus (N) is irregular containing euchromatin with some heterochromatic regions. The cytoplasm is somewhat disorganized with a retracted rough endoplasmic reticulum (*). A great number of lipid droplets are apparent (l). Many mitochondria (m) appear faded. (X 42,500).

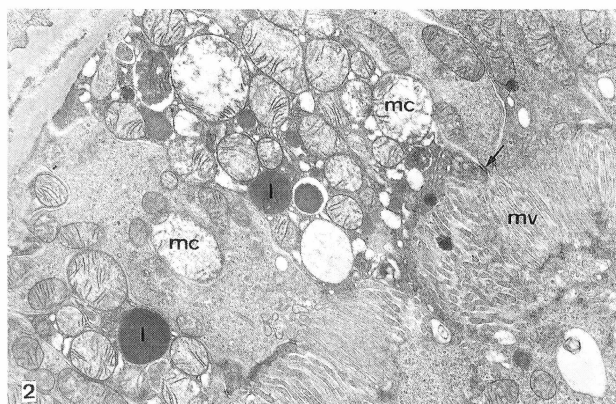


Figure 2. — Electronmicrography showing part of the proximal convoluted tubule of a pregnant rat of group A100 (see legend to Fig. 1). The lumen is filled with microvilli (mv). The arrow points to a cell-connecting desmosome. The lysosomes (l) appear in various sizes and densities. There are many mitochondria, most with cristolysis (mc). (X 42,500).

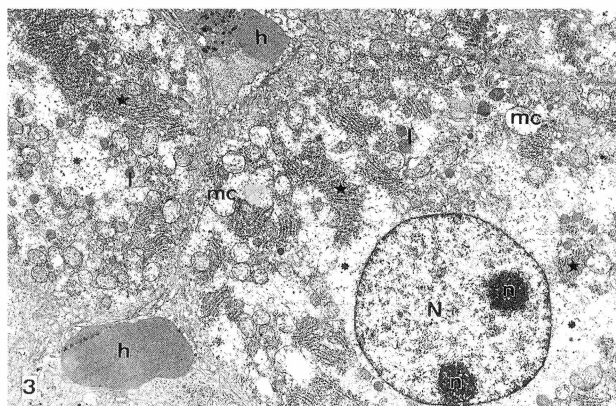


Figure 3. — Electronmicrographic aspect of a foetal hepatocyte from a rat in group A100. Erythrocytes (h) can be seen between contiguous hepatocyte cell membranes. The nucleus (N), bearing two nucleoli (n), appears predominantly euchromatic. Lysosomes (l) and a great number of mitochondria with few cristae, most of them cristolysed (mc), can be seen. The rough endoplasmic reticulum is retracted and clustered (*); many translucent areas (•) are also apparent. (X 42,500).

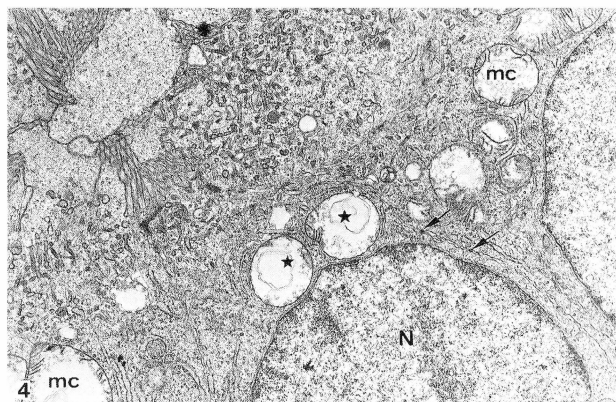


Figure 4. — Electronmicrographic aspect of an A100-group foetal proximal convoluted tubule showing two cells bound by desmosomes (arrows). The nucleus (N) is mostly euchromatic. Mitochondria can be seen with few and cristolysed cristae (mc), bearing figures of myelin (*). (X 42,500).

nia [24] and of the concentration of serum albumin [25], the amount of free salicylate would still be far too high to be counteracted.

Aspirin-induced nephrotoxicity is usually a result of its action on renal functions dependent on vasodilator prostaglandin biosynthesis. Also, by reducing prostacyclin (PGI₂) production, ASA can indirectly depress renin and aldosterone secretion, thus predisposing to hyperkalaemia [4].

Taken together, these facts can partially explain the ultrastructural effects observed on maternal livers and kidneys with high ASA doses.

ASA can cross the placental barrier [3]; foetal ASA levels are about 30% of maternal plasma levels, but its potent metabolite salicylic acid can reach as much as 90% [26]. Despite this, foetuses from A1 and A10 groups did not show hepatic or renal alterations.

Light microscopic pictures of foetuses from the A100 group were essentially normal, but at the ultrastructural level several alterations were seen. Hepatocyte cytoplasm was rich in mitochondria, most of them undergoing cristolysis, and a retracted, clustered rER surrounded by translucent areas (Figure 3). These areas could correspond to a dilated smooth endoplasmic reticulum (sER). Since this organelle bears cytochrome P-450, glucuronyl-transferase, epoxide-hydrolase and lipid-synthesizing enzymes [27], its dilated aspect in our material suggests a reduction in its metabolizing capacity. This triad (sER dilatation, mitochondrial cristolysis and retracted rER) demonstrates cell lesions similar to those found in aspirin-related Reye's syndrome intoxication [28].

Foetal kidneys of the A100 group revealed irregularly shaped lysosomes, raised concentration of mitochondria with cristolysis and myelin figures (Figure 4). It is likely that these alterations were consequent to the ASA-induced reduction of prostaglandin synthesis, which culminates in haemodynamic disturbances [29].

Our observations point out that the consumption of ASA in antiinflammatory dosages during rat pregnancy can be hazardous for mothers and foetuses at both the hepatic and renal levels, without overt signs of toxicity.

References

- [1] Collins E., Turner G.: "Maternal effects of regular salicylate ingestion in pregnancy". *Lancet*, 1975, II, 335.
- [2] Stuart M. J., Gross S. J., Elrad H., Graeber J. E.: "Effects of acetylsalicylic acid ingestion on maternal and neonate hemostasis". *N. Eng. J. Med.*, 1982, 307, 909.
- [3] Palmisano P. A., Cassidy G.: "Salicylate exposure in the perinate". *J. Am. Med. Assoc.*, 1969, 209, 556.
- [4] Insel P. A., "Analgesic-antipyretic and antiinflammatory agents and drugs employed in the treatment of gout" In: Hardman J. G., Limbird L. E. (eds.), Goodman & Gilman's The Pharmacological Basis of Therapeutics, 1996, 9th ed. McGraw-Hill, 617.
- [5] Shapiro S., Monson R. R., Kaufman D. W., Siskind V., Heinonen O. P., Slone D.: "Perinatal mortality and birth-weight in relation to aspirin taken during pregnancy". *Lancet*, 1976, 26, 1375.
- [6] Schaller J. G.: "Chronic salicylate administration in juvenile rheumatoid arthritis: aspirin "hepatitis" and its clinical significance". *Pediatrics*, 1978, 62, 916.
- [7] Martens M. E., Lee C. P.: "Reye's syndrome: salicylates and mitochondrial functions". *Biochem. Pharmacol.*, 1984, 33, 2869.
- [8] Stillman M. T., Napier J., Blackshear J. L.: "Adverse effects of non-steroidal antiinflammatory drugs on the kidney". *Med. Clin. North Am.*, 1984, 68, 371.
- [9] Whiting P. H., Tissocki K., Hawsworth G. M.: "Human renal medullary interstitial cells and analgesic nephropathy". *Ren. Fail.*, 1999, 21, 387.
- [10] Rocha G. M., Michea L. F., Peters E. M., Kirby M., Xu Y., Ferguson D. R., Burg M. B.: "Direct toxicity of nonsteroidal antiinflammatory drugs for renal medullary cells". *Proc. Natl. Acad. Sci. USA.*, 2001, 98, 5317.
- [11] Saito H., Sakai T., Ueno K., Kitagawa H.: "Influence of maternal drug metabolism on the fetal toxicity induced by acetylsalicylic acid". *J. Toxicol. Sci.*, 1982, 7, 177.
- [12] Saito H., Yokoyama A., Takeno S., Sakai T., Ueno K., Masumura H., Kitagawa H.: "Fetal toxicity and hypocalcemia induced by acetylsalicylic acid analogues". *Res. Commun. Chem. Pathol. Pharmacol.*, 1982, 38, 209.
- [13] Espiridião S., Ajeje R., Kopelman B. I., Simões M. J., Kulay Jr. L.: "Ação crônica do ácido acetil-salicílico na prenhez da rata". *Rev. Bras. Gin. Obstet.*, 1998, 20, 245.
- [14] Makita T., Hakoi K.: "Proliferation and alteration of hepatic peroxisomes and reproduction of ATP-ase activity on their limiting membrane after oral administration of acetylsalicylic acid (aspirin) for four weeks to male rats". *Ann. N. York. Acad. Sci.*, 1995, 748, 640.
- [15] Burrell J. H., Young J. L. C., McDonald G. J.: "Experimental analgesic nephropathy: changes in renal structure and urinary concentration ability in Fischer 344 rats given continuous low doses of aspirin and paracetamol". *Pathology*, 1990, 22, 33.
- [16] Angervall L., Bengtsson U.: "Impairment of renal concentrating capacity in albino rats induced by phenacetin and acetylsalicylic acid". *Acta Pharmacol. Toxicol.*, 1968, 26, 105.
- [17] Hamilton J. B., Wolfe J. M.: "The effect of male hormone substance upon birth and prenatal development in the rat". *Anat. Rec.*, 1938, 70, 433.
- [18] Mamede J. A. V., Oliveira-Filho R. M., Simões M. J., Mora O. A., Espiridião S., Kulay Jr. L.: "Hepatic and renal effects of azidothymidine and acyclovir on pregnant rats". *Clin. Exp. Obst. & Gyn.*, 2000, 27, 227.
- [19] Sibai B. M., Mirro R., Chesney C. M., Lefler C.: "Low-dose aspirin in pregnancy". *Obstet. Gynecol.*, 1989, 74, 551.
- [20] Sibai B. M.: "An aspirin a day to prevent prematurity". *Clin. Perinatol.*, 1992, 19, 305.
- [21] Furst D. E., Tozer T. N., Melmon K. L.: "Salicylate clearance, the resultant of protein binding and metabolism". *Clin. Pharmacol. Ther.*, 1979, 26, 380.
- [22] Tomoda T., Kurashige T., Hayashi Y., Enzan H.: "Primary changes in liver damage by aspirin in rats". *Acta Paediatr. Jpn.*, 1998, 40, 593.
- [23] Whitaker P. G., McPhail S., Lind T.: "Serial hematologic changes and pregnancy outcome". *Obstet. Gynecol.*, 1996, 88, 33.
- [24] Pritchard S. A.: "Changes in blood volume during the pregnancy and delivery". *Anesthesiology*, 1965, 26, 393.
- [25] Mendenhall H. W.: "Serum protein concentration in pregnancy. I. Concentration in maternal serum". *Am. J. Obstet. Gynaecol.*, 1970, 106, 388.
- [26] Wolf F., Berg R., Putter J.: "Pharmacokinetics studies on the placental transfer of acetylsalicylic acid intravenously administered in the prepartal period". *Arch. Gynecol.*, 1977, 224, 195.
- [27] Aranda J. V.: "Developmental pharmacology and pharmacokinetics". In Polin R. A., Fox W. W.: Fetal and Neonatal Physiology, 1992, Saunders, 107.
- [28] Starko K. M., Ray C. G., Domingues L. B., Stromberg W. L., Woodall D. F.: "Reye's syndrome and salicylate use". *Pediatrics*, 1980, 66, 859.
- [29] Matson J. R., Stokes J. B., Robillard J. E.: "Effects of inhibition of prostaglandin synthesis on fetal renal function". *Kidney Int.*, 1981, 20, 621.

Address reprint requests to:

S. ESPIRIDÃO, M.D.

Rua São Carlos do Pinhal, 79, apto. 22

CEP: 01333-001

São Paulo - SP (Brasil)