

General Section

Placental umbilical cord blood transfusion in transfusion-dependent beta thalassemic patients: A preliminary communication

N. Bhattacharya, D.Sc., MBBS, M.D., M.S., FACS

Bijoygarh State Hospital and Moore Avenue Specialist PolyClinic, Calcutta (India)

Summary

The term blood substitute is actually a misnomer because only a part of the total functions of the blood is replaced by any available so-called substitute, i.e., oxygen delivery and volume expansion only. Therefore, a more accurate term should be red cell substitute. Cord blood, because of its rich mix of fetal and adult hemoglobin, high platelet and WBC counts, and a plasma filled with cytokine and growth factors, as well as its hypoantigenic nature and altered metabolic profile, has all the potential of a real and safe alternative to adult blood during emergencies due to any etiology of blood loss and anemia.

Our experience of 92 units of cord blood transfusion in patients with beta thalassemia with severe anemia (hemoglobin concentration varying from 3.5 to 5.9 g/dl with mean hemoglobin 4.6 g/dl) proved to be extremely effective in 14 patients as an emergency substitute of adult conc RBC transfusion (male: female ratio 1:1, age varying from 6 months to 38 years).

In the present series, the collection of the blood varied from 57 ml-136 ml mean 84 ml \pm 7.2 ml SD, median 87 ml, mean packed cell volume 45 \pm 3.1 SD, mean hemoglobin concentration 16.4 g/dl \pm 1.6 g/dl SD. After collection the blood was immediately preserved in the refrigerator and transfused within 72 hours of collection from the consenting mother undergoing lower uterine cesarean section. We did not encounter a single case of immunological or non immunological reaction.

We suggest that the medical fraternity use this precious gift of nature, which is free from infection, hypoantigenic with an altered metabolic profile, filled with growth factor and cytokine filled plasma with potential higher oxygen carrying capacity than for adult blood, as an emergency source of blood for the management of transfusion-dependent beta thalassemics.

Key words: Transfusion; Safe cord blood; Beta thalassemia.

Introduction

Thalassemia, also known as Cooley's anemia, is an autosomal recessive genetic disorder affecting the hematopoietic system. It is characterised by anemia and compromised hemoglobin transport throughout the body. It has various clinical ramifications depending on the stage and grade of the disease. For the most part, the disease is due to decreased production of the beta component of hemoglobin, i.e., the primary carrier of O₂ in the blood. This disorder affects mainly people in the Mediterranean, the Middle East and South Asia. There are three different types of beta thalassemia: Type A is mainly asymptomatic (trait) and is also known as thalassemia minor, which can present as mild anemia. Type B presents with hepatosplenomegaly and anemia along with growth failure features. Type C is the major variety of beta thalassemia which presents as severe anemia and complications of excessive iron load in the body, gener-

ally within one year of birth. As a general estimate, about 300,000 victims of thalassemia major can be detected globally. Treatment of beta thalassemia is essentially symptomatic with RBC transfusion to maintain a sufficient level of haemoglobin along with treatment of side-effects of iron load by iron chelation therapy to remove excess iron. This life-long transfusion dependence can create many problems for the unfortunate thalassemic patient, though there are global attempts to make blood transfusions safer with stricter vigilance. There are also protocols for inactivation of microbes in platelet units, use of plasma with reduced viral activity and liberalization of the use of red cell substitutes [1]. However, the risk of transfusion is not on the wane. The newer identified potential risk factors include the possibility of transmission of Creutzfeldt-Jakob disease in its classical or variant form even after leucodepletion, as lymphocytes are a possible source of infection transmission [2]. The problem is compounded in under-resourced countries where the blood transfusion itself can invite problems like HIV (1&2) and hepatitis B/C, malaria, etc.

In the animal kingdom, swallowing of the afterbirth by the mother is a general norm; nature provides this precious wisdom to its creatures. Even herbivorous animals

There is no conflict of interest. The Dept. of Science and Technology provided a 3-year research grant to the present investigator 1st April 1999.

Revised manuscript accepted for publication January 31, 2005

swallow their own placenta after the birth of their babies, e.g., the cow. However, in the human system, we do not know how to use this precious afterbirth which protects and nurtures the baby in the womb for so long. Of late, since 1989, there is an increasing global consciousness on the use of umbilical cord blood stem cells as an easily available source of hematopoietic stem cells for use in cases of bone marrow transplantation because it is easily available. It has the potential to incite less graft vs host reaction due to its hypoantigenic nature. Many important laboratories in the world have been stimulated to collect cord blood for stem cell isolation and harvesting. However, stem cells in the cord blood constitute .01% of the nucleated cells only, while the rest (99.99%) of the cord blood is discarded because it is seen as having no apparent use. This wasted precious gift of mother nature to the fetus has a high hemoglobin, WBC and platelet count and has growth factor and cytokine rich plasma which has been protected in the sterile environment of the womb under the constant showering of maternal blessings (antibodies) against all potential maladies, i.e., infection. Whether this placental umbilical cord blood could be a readily available safe source of blood substitute against adult blood transfusion is the principal theme behind the present work, which received a grant from the Department of Science and Technology, Govt. of West Bengal, Bikash Bhavan, Salt Lake, Calcutta, India. The present paper deals with cases of thalassemics with severe anemia who needed immediate blood transfusion support but could not arrange for fresh concentrated RBCs from any source. They applied to our institute's ethical committee for placental umbilical cord blood transfusion as an emergency procedure to combat the crisis.

Materials and Methods

Ninety-two units of human placental umbilical cord blood were collected from consenting mothers aseptically after lower uterine cesarean section under general or regional anesthesia. If there was gross prematurity or dysmaturity or the projected weight of the fetus was less than 2 kg, or there was any specific disease of the mother like hepatitis or HIV, etc., the cord blood collection was abandoned. Cord blood was collected from only informed, healthy mothers with their consent. The collection process started only after the baby was safely removed from the operation field and the anesthetist verified a stable physical condition of the mother. It was only then that the obstetrician decided to proceed with the umbilical cord blood collection. Immediately the cord was disinfected by spirit/betadine solution at the site of the proposed puncture of the umbilical vein and a 16 g needle was attached to a standard pediatric collection bag (containing 14 ml anticoagulant citrate phosphate dextrose adenine solution), which was used for the purpose of collection. A second bag was used if the collection exceeded or neared 100 ml and a second prick was made at a proximal region after using a clamp at the first prick site. The blood flowed by gravity and generally within a minute, 90% of the collection was over and within 2 min, in most of the cases, the blood flow ceased completely due to clot formation. In case of any confusion about the condition of the baby, a decision was immediately taken to preserve the blood in consultation with the pediatrician for future

use by the baby, or stamped "unsafe for transfusion", and no risk or chance whatsoever was taken for the eventual recipient of the blood.

When the collection was complete, the blood bag tubing was closed, sealed, and stored at 1-4°C, after putting necessary identification markings. Another sample of the cord blood collected from the placenta was immediately tested for blood group (Rh and ABO), HIV(1 and 2), hepatitis B and C, VDRL, malaria, as per standard blood transfusion protocol which we have reported on earlier [3].

In case of any confusion/contamination, the culture was put aside for identification of the pathogen if any, through appropriate protocol, and the sample was stamped unfit for transfusion.

In the present series, the collection of the blood varied from 57 ml -136 ml; mean 84 ml \pm 7.2 ml SD, median 87 ml, mean packed cell volume 45 ± 3.1 SD, mean hemoglobin concentration 16.4 ± 1.6 g percent SD. After collection, the blood was immediately preserved in the refrigerator and transfused within 72 hours of collection. Donation of the cord blood to the recipient followed the strict guidelines of the human ethical committee of the hospital headed by an emeritus professor of medicine. As a rule, the volunteer who wishes to enroll in the cord blood transfusion program must have a hemoglobin count which is below 6 g percent. Before the umbilical cord blood transfusion, a thorough clinical examination of the recipient was done, including proper monitoring of the BP/pulse/respiration and other cardinal and presenting features. Then pre-transfusion, a little blood was drawn from the prospective recipient of cord blood for blood grouping, Hgb/TC/DC/ESR/platelet/Coombs test, C-reactive protein, urea, creatinine, bilirubin and other investigations as per the requirements of the case. Hgb electrophoresis was done before and after the transfusion to see the impact of transfusion. The actual transfusion procedure started after necessary grouping and cross-matching of the specimens and checking the identity of the patient. The cord blood was transfused by a blood transfusion set containing a filter (230 μ m). For the initial 15 minutes or so the patient was carefully observed to see if there was any transfusion-related reaction. Thereafter, if all went well, the transfusion rate was increased till it was completed.

Result and Analysis

Adult hemoglobin consists of two alpha and two beta polypeptide chains, each bound to a haeme group, capable of binding with one molecule of O₂. 1 g hemoglobin which binds with 1.39 ml of oxygen. Therefore, 14 g percent of adult hemoglobin can carry, on average, 19.46 ml of oxygen. Cord blood at term carries on an average 16.8 g percent hemoglobin [4] of which 20% belongs to the adult hemoglobin type (3.36 g) and 80% belongs to the fetal hemoglobin type (13.44 g). The concentration of fetal hemoglobin may increase further depending on fetal stress, maturity and several other fetomaternal factors. Fetal hemoglobin has the potential to carry up to 50% more oxygen than adult hemoglobin [5], i.e., 1 g of fetal hemoglobin may carry up to 2.08 ml of oxygen. If we simply calculate theoretically, the oxygen carrying potential of 100 ml of cord blood, taking into account its 80% fetal hemoglobin component (2.08 ml O₂ carrying capacity per gram of fetal hemoglobin), and 20% adult hemoglobin component (1.39 ml O₂ carrying

Table — List of the patients with beta thalassemia with hemoglobin below 6 g percent who received emergency umbilical cord blood (UCB) transfusions in the present series.

Serial No.	Name, Age & Sex	Hemoglobin	Other diseases in the background apart from hepatosplenomegaly	Transfusion of UCB: No. of units	Immediate reaction viz., fever, chill and rigor, flank pain, back pain, blood in urine, fainting or dizziness	Late reactions like mild or severe progression to kidney failure, shock or delayed anemia	Complications: like mild to moderate discomfort, anemia, shock, acute renal shutdown, lung dysfunction	Unexpected/ Unusual Complications	Unknown complications and rare autoimmune disease or scleroderma due to microchimerism etc. with follow-up to date
1	R.H. 21 yrs, M	5.9 g	Growth retardation with bleeding P/R	16	Nil	Nil	Nil	Nil	Nil
2	S.B. 6 yrs, M	3.8 g	Impaired liver function	6	Nil	Nil	Nil	Nil	Nil
3	K.A. 11 yrs, F	4 g	Started regular period after transfusion	23	Nil	Nil	Nil	Nil	Nil
4	G.S. 18 yrs, M	5.2 g	Osteodystrophy, bowing of the legs, deformed chest wall and growth retardation	8	Nil	Nil	Nil	Nil	Nil
5	T.R. 6 months, M	4.1 g	Impaired liver function	2	Nil	Nil	Nil	Nil	Nil
6	H.K. 11 months, M	5.2 g	Impaired liver function	4	Nil	Nil	Nil	Nil	Nil
7	U.C. 38 yrs F	4.2 g	Hypoplastic anemia & mitral stenosis and incompetence	4	Nil	Nil	Nil	Nil	Nil
8	T.M. 21 yrs, M	3.9 g	Hypoplasia of bone marrow + Elisa Tb+	6	Nil	Nil	Nil	Nil	Nil
9	P.K. 5 yrs, M	3.8 g	Growth retardation	4	Nil	Nil	Nil	Nil	Nil
10	S.S. 6 yrs, F	3.5 g	Growth retardation	5	Nil	Nil	Nil	Nil	Nil
11	R.B. 14 yrs, F	4 g	Hypoplasia of bone marrow + Elisa Tb+	3	Nil	Nil	Nil	Nil	Nil
12	C.S. 24 yrs, F	5.6 g	Marrow hypoplasia and amenorrhoea	4	Nil	Nil	Nil	Nil	Nil
13	A.C. 2 yrs, M	3.5 g	Impaired liver function	3	Nil	Nil	Nil	Nil	Nil
14	S.B. 7 yrs, F	4.4 g	Elisa Tb+ and hypothyroidism	4	Nil	Nil	Nil	Nil	Nil

capacity per gram of adult hemoglobin), it would have around 32.62 ml of O₂ carrying capacity, which is a 67.62% additional oxygen capacity compared to adult blood (19.46 ml oxygen/100 ml). There are several factors which modify the O₂ binding affinity, which include (a) concentration of a hydrogen ion, (b) carbon dioxide concentration in the blood, (c) body temperature, and (d) 2-3 diphosphoglycerate concentration, only to name a few. The blood volume of a term fetus is approximately 80-85 ml/kg [6]. The placental vessel at term contains approximately 150 ml of blood [7]. Cord blood contains three types of hemoglobin, HbF, HbA, HbA₂, of which HbF constitutes the major fraction (50-85%) [4]. HbA accounts for 15-40% of hemoglobin and HbA₂ is present only in trace amounts at birth [8]. HbF has a greater oxygen affinity than HbA [9]. The oxygen tension at which the hemoglobin of cord blood is 50% saturated is 19-20 mm of Hgb, 6-8 mm Hgb lower than that of normal adult blood. This shift to the left of the hemoglobin oxygen dissolution curve results from poor binding of the 2, 3-diphosphoglycerate by HbF [10, 11].

The potential complications of blood transfusion therapy can be broadly divided under two headings, immunological and non-immunological reactions [12]. The immunological reactions are related to the stimulation of antibody production by foreign alloantigens by the different components of transfusion, e.g, RBC, leucocytes, platelets and plasma proteins. All immunizations may lead to immunological reactions in case of future stimulation by a similar antigen. The commonly encountered immunological reactions are hemolytic reactions due to red cell incompatibility. Febrile or pulmonary reactions are related to leucocyte and platelet antigens. Allergic and anaphylactoid reactions are related to antibodies and it is only very rarely that we can see graft vs host reactions due to engraftment of the transfused lymphocytes in cases of immunosuppression. The commonly encountered non-immunological reactions are a result of the physical or chemical properties of the transfused blood/blood products due to bacterial or viral contamination or the circulatory load.

In the present series, 14 patients volunteered for the cord blood transfusion protocol after getting necessary

clearance from the hospital based ethical committee. The age of the patients varied from six months to 38 years with a male:female sex ratio of 1:1. One patient received 23 units of transfusion (6 units at a time) because she started to have sudden menarche. Another patient received 16 units of cord blood (8 units at a time) due to bleeding (hemorrhoid which was treated with ligation and interruption). All other patients received two to eight units of cord blood, receiving at least two units at a time. They had universal complications of malnutrition along with growth retardation (4 cases), impaired liver function (4 cases) and hypofunction of the marrow (3 cases); osteodystrophy, Elisa Tb positivity for IgA and IgM (2 cases), while mitral stenosis and incompetence, period irregularity and hypothyroidism were the other complications. Hemoglobin concentrations of the patients in the present series varied from 3.5 g/dl to 5.9 g/dl (mean 4.36 g/dl). All the patients tolerated the procedure and not a single episode of immunological or non immunological reaction was encountered. Yet another interesting finding was that there was a subjective definite sense of well-being in the recipients, much more than after their previous episodes of transfusions with concentrated RBCs from adult sources.

Fetal hemoglobin can carry more oxygen than the mother's blood and there is a potential advantage of the fetal hemoglobin (Bohr's effect) by which it can carry more oxygen at low PCO_2 than at high PCO_2 [5]. Another potent advantage of cord blood transfusion which has therapeutic implications is the rich cytokine and growth factor filled plasma in cord blood, which eventually has a positive effect on distressed and emaciated patients. On the basis of our experience, we can say that cord blood transfusion is safe and can be used in hours of crisis from pediatric to adult age groups in thalassemic patients as an alternative to adult whole blood transfusion, not as an inferior method of transfusion but as an effective supplementation of blood, which has had no transfusion-related hazards detected so far.

Discussion and Conclusion

An estimated 13 million units of blood worldwide are not tested against human immunodeficiency virus or hepatitis viruses. In some developing countries, 80% of the blood supply comes from paid donors or replacement donors (relatives, friends or acquaintances), where the degree of infection is high [13]. Out of 500,000 pregnancy-related maternal deaths globally, 25% of deaths take place due to poor replenishment and lack of timely replacement of blood loss, as per a report of the World Health Organization [14]. Continuous supply of donated blood is vital for the practice of modern medicine, but because of an ever increasing concern over blood borne diseases like HIV, hepatitis or bovine spongiform encephalitis in certain areas, the search for an alternative source for blood transfusions is going on. For the last 70 years since the publication of the report of Amberson *et al.*, [15] there have been global attempts to find a genuine blood substitute.

PATIENT A.C.	%	TIME	AREA
F	22.4	1.17	377664
P2	5.6	1.30	90681
P3	5.2	1.66	83506
A0	45.6	2.48	739332
A2	21.1	3.67	285690
TOTAL AREA			1576873
F	22.4%	A2	21.1%

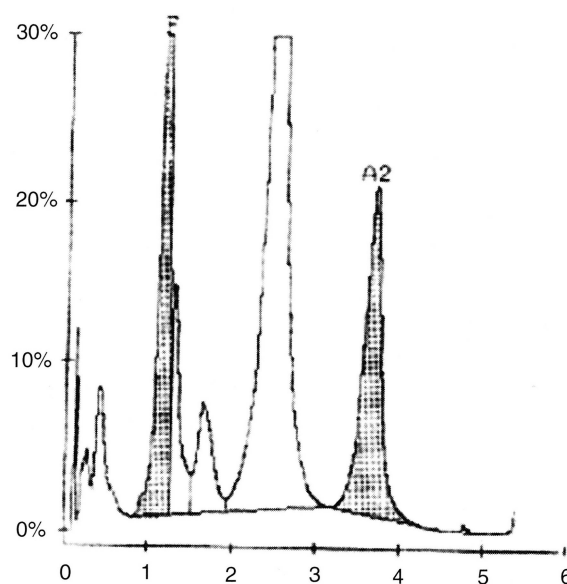


Figure — Hemoglobin electrophoresis results of a 2-year-old boy with thalassemia major who received a single unit of placental umbilical cord whole blood transfusion resulting in a rise of fetal hemoglobin from 10.4% to 22.4%.

Fetal hemoglobin is a natural stress response to hemoglobin synthesis which we try to preserve and augment in cases of thalassemia by providing hydroxyurea or other similar drug supports. Other conditions like pregnancy, diabetes, thyroid disease, or anti-epileptic drug therapy, can also increase the fetal hemoglobin concentration. This fetal hemoglobin, with its abundant source, i.e., the placenta (in India alone, there are more than 20 million placentas produced as afterbirth every year), is actually a cause of environmental pollution in many parts of the developing world because it attracts natural scavengers and spreads infection, unless aseptically treated, or incinerated.

The Western or the developed world has been working on the use of a tiny microscopic fraction of cord blood, i.e., CD 34 stem cells only (.01% of the nucleated cells of placental blood). My team of doctors has been successfully transfusing this blood as an alternative emergency source of blood transfusion in the background of anemia and emaciation of any etiology, i.e., from surgery to medicine for HIV, thalassemia, leprosy or for advanced cancer to patients with a crippling polyarthritis, etc.,

since 1999 [16-23]. We have applied for a global patent on the use of cord blood in these areas.

Recently, clinical scientists from the University of Liverpool [24, 25] in a collaborative work with Komfo Anokye Teaching Hospital at Kumashi, Ghana, published a report on the safe and life saving use of cord blood in pediatric anemia. They reported a substantial decrease in the mortality of children in sub-Saharan Africa suffering from severe anemia after falciparum infection, with the use of cord blood.

In conclusion, to combat the emergency requirement of blood in thalassemics, these precious hypimmune fetal cells [26-29] with an altered metabolic profile are a gift of nature, entrapped inside the placenta, which could be a readily available source of blood not only in the under-resourced countries of the world, but also for those in genuine need of adult blood or a safe substitute anywhere in the world. This is specially true for patients with thalassemia who need safe blood transfusions.

Acknowledgement

Dr. Surja Kanta Misra, MIC, Health and Family Welfare, Govt. of West Bengal, Mr. Ashim Burman, Principal Secretary, Dept. of Health and Family Welfare, Prof. C.R. Maity, DME and Dr. Prabhakar Chatterjee, DHS for constant encouragement.

References

- [1] Goodnough L.T. *et al.*: "Transfusion medicine: Second of two parts: Blood conservation". *New Engl. J. Med.*, 1999, 340, 525.
- [2] Mortimer P. P.: "Making blood safer", (Editorial). *Br. Med. J.*, 2002, 325, 400.
- [3] Bhattacharya N., Mukherjee K.L., Chettri M.K., Banerjee T., Mani U., Bhattacharya S.: "A study report of 174 units of placental umbilical cord whole blood transfusion in 62 patients as a rich source of fetal hemoglobin supply in different indications of blood transfusion". *Clin. Exp. Obstet. Gynecol.*, 2001, 28, 47.
- [4] Oski F.A., Naiman J.L.: *Haematologic Problems in the Newborn*. 3rd ed. Philadelphia: W.B. Saunders, 1992.
- [5] Guyton A.C., Hall J.E.: "Pregnancy and lactation". In: *Text book of Medical Physiology*. Bangalore, W.B. Saunders Company, 2001, 947.
- [6] Usher R., Shephard M., Lind J.: "The blood volume of the newborn infants and the placental transfusion". *Acta Paediatr.*, 1963, 52, 497.
- [7] Haselhorst G., Allmeling A.: "Die gewichtszunahme von neugeborenen infolge postnataler transfusion". *Z. Geburtshilfe Perinatol.*, 1930, 98, 103.
- [8] Karaklis A., Fessas P.: "The normal minor components of fetal hemoglobin". *Acta Haematol.*, 1963, 29, 267.
- [9] Davis J.A., Dobbing J.: *Scientific Foundation of Pediatrics*. Int. ed. London, William Heineman Medical Books, 1981, 514.
- [10] Killmartin J.V.: "Interaction of hemoglobin with protein, CO & 2-3 diphosphoglycerate". *Br. Med. Bul.*, 1976, 32, 209.
- [11] Delivoria Padopoulos M., Roncevic N.P., Oski F.A.: "Postnatal changes in the oxygen transfer of term premature and sick infants: The role of 2-3 diphosphoglycerate and the adult haemoglobin". *Pediatr. Res.*, 1971, 5, 235.
- [12] Schroeder M.L., Rayner H.L.: "Transfusion of blood and blood components". In: Bithell T.C., Foerster J., Athens J.W., Lukes J.N., (eds.), *Wintrob's Clinical Hematology*, Vol. 1, Philadelphia, Lea and Febiger, 1993, 675.
- [13] Sloand E.M., Pitt E., Klein H.G.: "Safety of blood supply". *JAMA*, 1995, 274, 1368.
- [14] World Health Organization International Federation of Red Cross and Red Crescent Societies: "Safe blood starts with me (report)". Geneva, World Health Organization, 2000, 12.
- [15] Amberson W.R., Mulder A.G., Steggerda F.R. *et al.*: "Mammalian life without red blood corpuscles". *Science*, 1933, 78, 106.
- [16] Bhattacharya N.: "Placental umbilical cord whole blood transfusion" (letter). *J. Am. Coll. Surg.*, 2004, 199, 347.
- [17] Bhattacharya N., Bandyopadhyay T., Bhattacharya M., Bhattacharya S.: "Do not discard 99.99% of the human placental umbilical cord blood for the sake of stem cells only". <http://bmj.com/cgi/eletters/323/7304/60#16874>. Accessed Oct. 5, 2001.
- [18] Bhattacharya N., Bandyopadhyay T., Bhattacharya M., Bhattacharya S.: "Immunization and fetal cell/tissue transplant: A new strategy for geriatric treatment". <http://bmj.com/cgi/eletters/323/7320/1025/b#21055>. Accessed April 6, 2002.
- [19] Bhattacharya N. *et al.*: "Umbilical cord whole blood transfusion: A suggested strategy to combat blood scarcity in Ireland". <http://bmj.com/cgi/eletters/324/7330/134/c#19096>. Accessed Jan. 27, 2002.
- [20] Bhattacharya N. *et al.*: "The safe use of placental umbilical cord whole blood transfusion in patients suffering with anemia and thalassemic in under-resourced regions of the world". <http://bmj.com/cgi/eletters/321/7269/1117#62372>. Accessed June 9, 2004.
- [21] Bhattacharya N. *et al.*: "Umbilical cord whole blood transfusion in HIV patients with anemia and emaciation". <http://bmj.com/cgi/eletters/327/7414/562-a#59738>. Accessed May 17, 2004.
- [22] Bhattacharya N. *et al.*: "Utilization of a genuine blood substitute: A suggestion to the medical fraternity in Iraqi Hospital". <http://bmj.com/cgi/eletters/326/7391/675#30850>. Accessed May 30, 2003.
- [23] Bhattacharya N. *et al.*: "A preliminary study report on placental umbilical cord blood transfusion in victims of anemia with leprosy in under-resourced regions of the world". <http://bmj.com/cgi/eletters/328/7454/1447/#63828>. Accessed June 22, 2004.
- [24] Clarke T.: "Newborns might help malaria kids-blood from umbilical cords could treat anemia caused by tropical disease". <http://www.nature.com/nsu/021111/021111-11.html>. Accessed Nov. 15, 2002.
- [25] Hassal-O., Bedu-Addo G., Adarkwa M., Danso K., Bates I.: "Umbilical cord blood for transfusion in children with severe anemia in under-resourced countries". *Lancet*, 2003, 361, 678.
- [26] Bhattacharya N., Chhetri M.K., Mukherjee K.L., Ghosh A.B., Samanta B.K., Mitra R. *et al.*: "Can human fetal cortical brain tissue transplant (up to 20 weeks) sustain its metabolic and oxygen requirements in a heterotrophic site outside brain? A study of 12 volunteers with Parkinsons disease". *Clin. Exp. Obstet. Gynecol.*, 2002, 29.
- [27] Bhattacharya N., Chhetri M.K., Mukherjee K.L., Das S.P., Mukherjee A., Bhattacharya M.: "Human fetal adrenal transplant: A possible role in relieving intractable pain in advanced rheumatoid arthritis". *Clin. Exp. Obstet. Gynecol.*, 2002, 29.
- [28] Bhattacharya N., Mukherjee K.L., Chhetri M.K., Banerjee T., Bhattacharya S., Ghosh A.B., Bhattacharya M.: "A unique experience with human pre-immune (12 weeks) and hypo-immune (16 weeks) fetal thymus transplant in a vascular subcutaneous axillary fold in patients with advanced cancer: A report of two cases". *Eur. J. Gynecol. Oncol.*, 2001, 22, 273.
- [29] Bhattacharya N.: "Fetal tissue/organ transplant in HLA randomized adult vascular subcutaneous axillary folds: A preliminary report of 14 patients". *Clin. Exp. Obstet. Gynecol.*, 2001, 28, 233.

Address reprint requests to:
N. BHATTACHARYA, DSc, MD, MS, FACS
55 Southend Park
Calcutta 700032 (India)