

Uterine arteriovenous malformation: A case report diagnosed by sonohysterography

A. Corticelli¹, M. Podestà², L. Pedretti³, A. Papadia³, E. Francescangeli³, M. Valenzano³

¹Obstetrics and Gynecology Department, Lavagna Hospital, Lavagna; ²Voltri Hospital, Genova

³Obstetrics and Gynecology Department, S. Martino Hospital, Genova (Italy)

Summary

Purpose of investigation: The aim of this report is to describe a case of uterine arteriovenous malformation that occurred in a 54-year-old postmenopausal woman referring recurrent postmenopausal bleeding, after two years of tamoxifen therapy.

Methods: Medical therapy with GnRh agonists was unsuccessful. Ultrasound and Doppler flow ultrasound scanning were normal and the following hysteroscopy was normal as well.

Results: Hysterosonography performed on the patient made us suspect the presence of an intracavitary vascular lesion which was confirmed histologically after hysterectomy.

Conclusion: In our case hysterosonography allowed us – by creating optimal contrast between the uterine wall and the uterine cavity – to suspect and identify the lesion and to recognize the typical ultrasound findings of this pathology not visualized with standard transvaginal ultrasound.

Key words: Uterine arteriovenous malformation; Hysterosonography.

Introduction

Vascular hemangiomas and vascular malformations of the uterus are very uncommon. Few reports of these lesions are found in the literature and are limited largely to single case histories and a few small series [1, 2]. Some of the articles describe dramatic clinical manifestations of the vascular tumors and malformations, including excessive bleeding [3]. Clinical findings are often not reliable and at times angiography and ultrasonography may prove helpful in obtaining a preoperative diagnosis [1].

Case Report

A 54-year-old postmenopausal woman, gravida 4, para 2, spontaneous abortion 2, presented with referring recurrent postmenopausal bleeding in July 1999.

In 1997 the patient had undergone quadrantectomy and radiation therapy for breast cancer and one month later she began hormonal therapy with tamoxifen. In 1998 she had an episode of vaginal bleeding; this initially consisted of two days of light bleeding followed by intermittent torrential bleeding. In the same year she had similar bleeding three subsequent times. In all cases she was treated at another institution with medical therapy including gonadotropin releasing hormone agonists with poor improvement. Coagulation studies were normal and dilatation and curettage (D&C) was proposed. In February and March 1999 she underwent B-mode and color Doppler ultrasound and hysteroscopy. The ultrasound was transabdominally and transvaginally performed and demonstrated a normal pelvis with fibromatous uterus. Doppler flow ultrasound scanning showed no pathological findings. The hysteroscopy showed normal atrophic postmenopausal findings.

Results

When the patient came under our care we proposed hysterosonography. The patient underwent the exam a few days later: easy distention of the uterine cavity was seen together with an irregular lesion extending from the uterine fundus (thickness 6 mm) to the cavity. In some scans the lesion revealed multiple tortuous anechoic areas indicating an arteriovenous malformation (Figure 1).

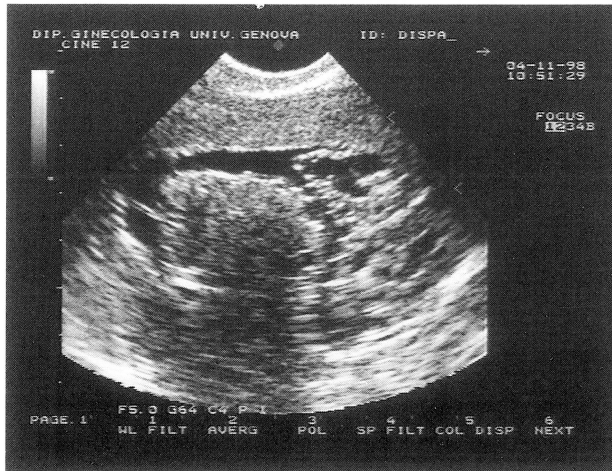
In November the patient underwent a hysterectomy with bilateral salpingo-oophorectomy. On pathologic examination the uterus weighed 65 g, the uterine posterior wall was 2 cm thick at its maximum thickness and the anterior wall was 1.2 cm. The endometrial cavity was 8 cm long. The endometrium showed sparse hemorrhagic areas. Cut sections of the posterior wall showed a lesion composed of an abnormal vascular network with tortuous and anastomosing vessels involving all the myometrial thickness. The lesion was comparable to a cavernous hemangioma. The diagnosis of an arteriovenous malformation was thus confirmed.

Discussion

Since the description of uterine arteriovenous malformation by Dubreuil and Loubat [4] in 1926, various terms have been used to describe this lesion, including cirroid aneurysm, pulsating angioma, arteriovenous aneurysm, racemose aneurysm, arteriovenous fistula and cavernous hemangioma [5].

Arteriovenous hemangioma has been described as partial persistence of the fetal capillary bed causing abnormal connections between the arteries and veins. It can be divided into two types – one which occurs in deep

Revised manuscript accepted for publication December 7, 2004



locations, also called arteriovenous malformation, and one which occurs superficially in the dermis [6].

Uterine arteriovenous malformations may be congenital or acquired.

Congenital types may represent arrested embryonic development of vascular structures [7]. They can be clinically silent and infrequently cause pain and bleed spontaneously, although cases with severe menorrhagia and hematuria have been reported [8].

Acquired etiologies include pelvic trauma, surgery (such as curettage, therapeutic abortion and cesarean section [9]), neoplasm (such as endometrial or cervical carcinoma and trophoblastic neoplasia [9, 10]), infection and exposure to diethylstilbestrol [1, 11-13]. Histologically, the lesion consists of arteries and veins of various sizes communicating directly to form fistulae. The vessels are ambiguous, with thickened intima and some elastin in the walls making the distinction between arteries and veins difficult [12].

Uterine arteriovenous malformations are potentially life threatening. Typically, patients with uterine arteriovenous malformations present with heavy abnormal bleeding that may be exacerbated by D&C [14]. The pattern of bleeding is intermittent and torrential and blood loss is often so marked as to cause hypovolemic shock and in 30% of reported cases the patients required blood transfusions [15]. However the clinical presentation is variable, ranging from asymptomatic patients to those with recurrent pregnancy loss and death following uterine instrumentation.

Other symptoms include throbbing discomfort in the lower abdomen, dyspareunia, urinary frequency, or incontinence. Strong pelvic pulsations after exercise have also been described [6].

Systemic hypotension caused by intratumoral blood pooling and even cardiac failure has been described [16].

The diagnosis of arteriovenous malformation of the uterus is difficult because the condition is very rare and the routinely used diagnostic methods, such as pelvic examination, curettage, gray scale ultrasonography or

hysteroscopy, usually fail to provide findings which are strongly suggestive of this malformation [5]. Angiography, used in the past to diagnose arteriovenous malformations [10, 11, 17, 18], is no longer performed for purely diagnostic purposes mainly because it is invasive.

Ultrasound examination has proved useful in providing diagnostic information in a number of cases [9, 18] Torres *et al.* [19] first described this anomaly as multiple anechoic structures with a serpentine contour within the pelvis. Classical features include tortuous vessels of greater than normal calibre with real time sonography showing a bounding pulse [9]. However, several entities, including fluid filled bowel loops, multilocular ovarian cysts, hemangiomas, hydrosalpinx, hydatiform and invasive moles, and choriocarcinomas may have a similar appearance on gray scale sonography [5, 11, 17].

Color Doppler sonography has also been employed to diagnose uterine arteriovenous malformations [18]. The characteristic flow pattern of arteriovenous malformations on color Doppler sonography will show a tangle of tortuous vessels with multidirectional, high velocity and turbulent flow [18].

Conclusions

Uterine arteriovenous malformations may have grey scale sonography appearing similar to several other entities. Color Doppler sonography often, but not in our case, may help in diagnosing this rare lesion. Hysterosonography allowed us – by creating optimal contrast between the uterine wall and the uterine cavity – to suspect and identify the lesion and to recognize the typical ultrasound findings of this pathology not visualized with standard transvaginal ultrasound.

References

- [1] Fleming H., Ostor A.G., Pickel H., Fortune D.W.: "Arteriovenous malformations of the uterus". *Obstet. Gynecol.*, 1989, 73, 209.
- [2] Salm R.: "Diffuse cavernous haemangioma of the uterus". *J. Pathol. Bacteriol.*, 1959, 77, 111.
- [3] Kasznica J., Nisar N.: "Congenital vascular malformation of the uterus in a stillborn: a case report". *Hum. Pathol.*, 1995, 26, 240.
- [4] Dubreuil G., Loubat E.: "Aneurysme cricoide de l'utérus". *Ann. Anat. Pathol.*, 1926, 3, 697.
- [5] Mungen E., Yergok Y.Z., Ertekin A.A., Ergur A.R., Ucmakli E., Aytaclar S.: "Color Doppler sonographic features of uterine arteriovenous malformations: report of two cases". *Ultrasound Obstet. Gynecol.*, 1997, 10, 215.
- [6] Majmudar B., Ghanee N., Horowitz I.R., Graham D.: "Uterine arteriovenous malformation necessitating hysterectomy with bilateral salpingo-oophorectomy in a young pregnant patient". *Arch. Pathol. Lab. Med.*, 1998, 122, 842.
- [7] Natali J., Jue-Denis P., Kieffer E.: "Arteriovenous fistulae of the internal iliac vessels". *J. Cardiovasc. Surg.*, 1984, 25, 165.
- [8] Beller U., Rosen R.J., Beckman E.M., Markoff G., Bernstein A.: "Congenital arteriovenous malformation of the female pelvis: a gynecologic perspective". *Am. J. Obstet. Gynecol.*, 1988, 159, 1153.
- [9] Diwan R.V., Brennan J.N., Selim A.M.: "Sonographic diagnosis of arteriovenous malformation of the uterus and pelvis". *J. Clin. Ultrasound.*, 1983, 11, 295.

- [10] Ghosh T.K.: "Arteriovenous malformation of the uterus and pelvis". *Obstet. Gynecol.*, 1986, 68, 40S.
- [11] Meilstrup J.W., Kasales C.J., Van Hook D.M.: "Women's health case of the day". *Am. J. Roentgenol.*, 1994, 162, 1457.
- [12] El-Torky M., Giltman L., Maijeb A.: "Uterine arteriovenous fistula. A case report". *J. Reprod. Med.*, 1986, 31, 283.
- [13] Follen M.M., Fox H.E., Levine R.U.: "Cervical vascular malformation as a cause of antepartum and intrapartum bleeding in three diethylstilbestrol exposed progeny". *Am. J. Obstet. Gynecol.*, 1985, 153, 890.
- [14] Flynn M.K., Levine D.: "The noninvasive diagnosis of uterine arteriovenous malformation". *Obstet. Gynecol.*, 1996, 178, 650.
- [15] Monolitsas T., Hurley V., Gilford E.: "Uterine arteriovenous malformations – a rare cause of uterine haemorrhage". *Aust. NZ J. Obstet. Gynaecol.*, 1994, 34, 197.
- [16] Arredondo-Soberson F., Loret de Mola J.R., Shlansky-Goldberg R., Tureck R.W.: "Uterine arteriovenous malformations in a patient with recurrent pregnancy loss and a bicornuate uterus: a case report". *J. Reprod. Med.*, 1997, 42, 239.
- [17] Jain K.A., Jeffrey R.B., Sommer G.F.: "Gynecologic vascular abnormalities: diagnosis with Doppler". *Radiology*, 1991, 178, 549.
- [18] Musa A., Hata T., Hata K., Kitao M.: "Pelvic arteriovenous malformation diagnosed by color flow Doppler imaging". *Am. J. Roentgenol.*, 1989, 152, 1311.
- [19] Torres W.E., Sones P.J., Thames F.M.: "Ultrasound appearance of a pelvic arteriovenous malformation". *J. Clin. Ultrasound.*, 1989, 7, 383.

Address reprint requests to:
A. CORTICELLI, M.D.
Via Ravaschieri, 101/5
16043 Chiavari - Genova (Italy)

International forum on BIRTH

Rome, 8-11 June 2005 • Auditorium Parco della Musica

Organization

Congress Presidents:

GIAN CARLO DI RENZO (Italy), ROBERTO ROMERO (USA)

Scientific Secretariat:

PAOLA GERACE - Centre of Perinatal and Reproductive Medicine - University Hospital "Montelucre"
Via Brunamonti, 51 - 06121 Perugia, Italy - Ph. +39 075 5720563/74 - Fax +39 075 5729271
E-mail: direnzo@unipg.it

Organizing Secretariat:

TRIUMPH CONGRESSI SRL - Via Lucilio, 60 - Rome, Italy - Ph. +39 06 35530301 - Fax +39 06 35530262
E-mail: birth@gruppotriumph.it