

Prenatal diagnosis of Wolf-Hirschhorn syndrome (4p-) in association with congenital diaphragmatic hernia, cystic hygroma and IUGR

A. Basgul¹, Fellow M.D.; Z.N. Kavak¹, Prof.; I. Akman², Assoc. Prof.; A. Basgul³, Consultant M.D.; H. Gokaslan¹, Assoc. Prof.; N. Elcioglu⁴, Prof., M.D.

¹Department of Obstetrics and Gynecology, Marmara University School of Medicine

²Department of Pediatrics, Marmara University School of Medicine

³Department of Anesthesiology, Sisli Etfal Training and Education Hospital

⁴Department of Genetics, Marmara University School of Medicine, Istanbul (Turkey)

Summary

Wolf-Hirschhorn syndrome (WHS) is a rare distinct clinical entity caused by a deletion of the short arm of chromosome 4. We report a case in which intrauterine growth restriction (IUGR), severe oligohydramnios, left-sided congenital diaphragmatic hernia (CDH), and cystic hygroma were detected by prenatal ultrasound examination at 27 weeks of gestation. A 29-year-old gravida 3, para 2, woman was referred at 26 weeks' gestation with suspicion of IUGR and cystic hygroma. Sonographic examination revealed IUGR with severe oligohydramnios, increased nuchal fold with cystic hygroma (left-sided diaphragmatic defect of Bochdalek type), and congenital diaphragmatic hernia. Chromosome analysis revealed a 46, XX, del(4)(p15.2) karyotype. Autopsy confirmed the ultrasound findings. Congenital diaphragmatic hernia (CDH) has rarely been described to be associated with WHS. CDH and cystic hygroma can lead to a diagnosis of this syndrome very early in life. We recommend genetic evaluation of a fetus with cystic hygroma, IUGR and CDH taking into consideration 4p deletion syndrome.

Key words: Prenatal diagnosis; Wolf-Hirschhorn syndrome.

Introduction

Wolf-Hirschhorn syndrome (WHS) is caused by distal deletion of the short arm of chromosome 4 (4p-) which was first described by Cooper and Hirschhorn in 1961 [1]. It is a rare condition, the incidence of which has been estimated to be around 1/50,000 to 1/95,896 births [2]. WHS is usually diagnosed postnatally; only little information is available on WHS in fetuses and prenatal sonographic features have rarely been described in the literature [3].

The majority of WHS cases (87%) are de novo deletions preferentially of paternal origin [4].

The typical presentation of WHS is characterized by the association of intrauterine growth retardation (IUGR), profound psychomotor handicap, skeletal abnormalities, facial dysmorphism with Greek warrior helmet appearance of the nose which is a broad bridge of the nose continuing to the high forehead, hypertelorism, microcephaly, micrognathia, midline fusion defects like cleft lip or palate or agenesis of the corpus callosum, bilateral renal hypoplasia, cardiac septal defects and hypospadias [5]. Congenital diaphragmatic hernia (CDH) has rarely been described in WHS [6].

In this report we present a case in which IUGR, CDH and facial dysmorphism were detected by prenatal ultrasound at 27 weeks of gestation. Chromosome analysis revealed a 46, XX, del(4)(p12) by standard karyotyping.

Our purpose is to contribute to the recognition of WHS in prenatal ultrasound and to obtain better information of this syndrome to answer parents' questions in a clinical setting.

Case

A 29-year-old, gravida 3, para 2 (1 living), woman was referred at 27 weeks of gestation (WG) for severe IUGR. The parents were healthy, nonconsanguineous and the family history was unremarkable. There were no reports of alcohol, tobacco or illicit drug use nor any intrauterine teratogenic or infectious exposure. There was no family history of congenital defects. The patient had had a stillbirth due to perinatal asphyxia three years before. The physical examination of that baby was normal. She had a healthy baby after that pregnancy.

She underwent triple screening for biochemical markers of aneuploidy at 16 weeks of gestation. Alfa-feto protein (AFP) was elevated (2.08 MOM), uE3 was 0.66 MoM and hCG was 1.90 MoM at that time. Except for HbsAg positivity, other infectious markers like toxoplasma and rubella and cytomegalovirus (CMV) were negative.

Sonographic examination revealed a single live fetus. Fetal biparietal diameter, abdominal circumference and femur length measurements were compatible with 21-22 weeks' gestation. Fetal hypotonia with decreased movements on ultrasound was remarkable. Oligohydramnios was also noted. Examination of the fetal anatomy revealed left-sided CDH, cystic dilatation at the nuchal region like cystic hygroma, and increased nuchal fold.

Umbilical artery Doppler flow measurements showed an increased pulsatility index. The uterine artery Doppler flow was normal and there were no early diastolic notches at bilateral

uterine arterial flow. There was bradycardia which was around 122-130 bpm. The placenta looked small and had lakes.

She was counseled regarding the possible association of chromosome abnormalities with the above features and was offered genetic amniocentesis. Amniocentesis was performed without any complications.

Chromosome analysis by standard G Banding (GTG/500) revealed deletion of the short arm of chromosome 4 in all the metaphases. It was reported as 46, XX, del(4)(p15.2).

As parental chromosome studies showed the mother and father had a normal karyotype, the fetus developed this syndrome "de novo". After genetic counseling the couple elected to terminate the pregnancy.

A stillborn female fetus weighing 620 g with an occipitofrontal circumference of 21 cm and a height of 33 cm was delivered after induction of labor. The baby had hypertelorism, low-set ears, and a scaphoid abdomen. At autopsy there was a hypoplastic left lung. The large and small bowels were inside the left thorax due to a Bochdalek type of congenital diaphragmatic hernia.

Placental pathological examination showed villous fibrosis, perivillous fibrinoid necrosis, a small placenta for 27 weeks of gestation, intracytoplasmic vacuolization at the syncytiotrophoblastic structures all of which described fetoplacental insufficiency.

Discussion

Knowledge on fetuses with WHS is still limited due to the small number of published cases. Since the first clinical description around 130 cases have been reported, most of them occurring in childhood [1, 2, 7]. A female predilection of 2:1 has been reported [1, 7].

Prenatal diagnosis of Wolf-Hirschhorn syndrome has only occasionally been reported in fetuses karyotyped because of routine indications of chromosomal analysis or intrauterine growth restriction with or without associated anomalies [8]. Our case was detected by standard karyotyping because of IUGR with fetal abnormality. Standard karyotyping on regular banding can miss almost half of the cases [9]. The associated sonographic signs of facial dysmorphism (Greek helmet facies) and midline fusion defects (cleft lip or palate, cardiac septal defects, etc.) may help to refine specific indications for FISH analysis taking into consideration 4p-del syndrome [10]. Before the time of prenatal diagnosis, all individuals with WHS were born at term and were small for gestational age. In about one third of cases, perinatal distress indicating a cesarean section was observed [11]. Mostly the placenta was found to be small with vascular lesions and multiple infarcts as in our case. However normal placental development has been noted as well [1].

Actually a combination of this syndrome with CDH and cystic hygroma has rarely been described. CDH can present either as an isolated defect at birth, or with multiple congenital abnormalities, or as part of a defined syndrome or chromosomal disorder [6]. Cystic hygroma (CH) is a well known lymphatic malformation occurring most commonly in the cervical region. It is believed to be the result of failure of communication between lymphatic sacs and the venous system [12]. Associated chromosomal abnormalities and a variety of other congenital malformations occur in the vast majority of cases [13].

Verloes *et al.* first described a case of WHS in association with cystic hygroma in 1991 [14]. Thus CDH and cystic hygroma although not common in WHS can lead to its diagnosis relatively early in life.

The prenatal detection of intrauterine growth restriction, CDH, and cystic hygroma should lead doctors to suspect the presence of Wolf-Hirschhorn syndrome, and each patient with these findings can be offered clinical genetic evaluation.

As more cases are reported we may be able to establish discrete or modified phenotypes in hopes of providing better counselling and management of our patients. The importance of karyotyping fetuses with severe IUGR is also emphasized.

References

- [1] Boog G., Le Vaillant C., Collet M., Dupre P.F., Parent P., Bongain A. *et al.*: "Prenatal sonographic patterns in six cases of Wolf-Hirschhorn (4p-) syndrome". *Fetal. Diagn. Ther.*, 2004, 19, 421.
- [2] Battaglia A., Carey J.C., Wright T.J.: "Wolf-Hirschhorn (4p-) syndrome" (Review). *Adv. Pediatr.*, 2001, 48, 75.
- [3] Dietze I., Fritz B., Huhle D., Simoons W., Piecha E., Rehder H.: "Clinical, cytogenetic and molecular investigation in a fetus with Wolf-Hirschhorn syndrome with paternally derived 4p deletion. Case report and review of the literature" (Review). *Fetal. Diagn. Ther.*, 2004, 19, 251.
- [4] Dallapiccola B., Mandich P., Bellone E., Selicorni A., Mokin V., Ajmar F., Novelli G.: "Parental origin of chromosome 4p deletion in Wolf-Hirschhorn syndrome". *Am. J. Med. Genet.*, 1993, 47, 921.
- [5] Battaglia A., Carey J.C., Cederholm P., Viskochil D.H., Brothman A.R., Galasso C.: "Natural history of Wolf-Hirschhorn syndrome: experience with 15 cases". *Pediatrics.*, 1999, 103 (4 Pt 1), 830.
- [6] Van Dooren M.F., Brooks A.S., Hoogeboom A.J., Van den Hoonaard T.L., de Klein J.E., Wouters C.H., Tibboel D.: "Early diagnosis of Wolf-Hirschhorn syndrome triggered by a life-threatening event: congenital diaphragmatic hernia". *Am. J. Med. Genet.*, 2004, 127, 194.
- [7] Quarrell O.W., Snell R.G., Curtis M.A., Roberts S.H., Harper P.S., Shaw D.J.: "Paternal origin of the chromosomal deletion resulting in Wolf-Hirschhorn syndrome". *J. Med. Genet.*, 1991, 28, 256.
- [8] Vamos E., Pratola D., Van Regemortel N., Freund M., Flament-Durand J., Rodesch F.: "Prenatal diagnosis and fetal pathology of partial trisomy 20p-monozygosity 4P resulting from paternal translocation". *Prenat. Diagn.*, 1985, 5, 209.
- [9] Reid E., Morrison N., Barron L., Boyd E., Cooke A., Fielding D., Tolmie J.L.: "Familial Wolf-Hirschhorn syndrome resulting from a cryptic translocation: a clinical and molecular study". *J. Med. Genet.*, 1996, 33, 197.
- [10] Aslan H., Karaca N., Basaran S., Ermis H., Ceylan Y.: "Prenatal diagnosis of Wolf-Hirschhorn syndrome (4p-) in association with congenital hypospadias and foot deformity". *BMC Pregnancy Childbirth.*, 2003, 3, 1.
- [11] Tachdjian G., Fondacci C., Tapia S., Hutten Y., Blot P., Nessmann C.: "The Wolf-Hirschhorn syndrome in fetuses". *Clin. Genet.*, 1992, 42, 281.
- [12] Suwanrath-Kengpol C., Suntharasaj T., Patrapinyokul S., Chanvit P.: "Prenatal diagnosis of a huge cystic hygroma colli". *Ultrasound Obstet. Gynecol.*, 2003, 22, 323.
- [13] Musone R., Bonafiglia R., Menditto A., Paccone M., Cassese E., Russo G., Balbi C.: "Fetuses with cystic hygroma. A retrospective study". *Panminerva Med.*, 2000, 42, 39.
- [14] Verloes A., Schaaps J.P., Herens C., Soyeur D., Hustin J., Dodinval P.: "Prenatal diagnosis of cystic hygroma and chorioangioma in the Wolf-Hirschhorn syndrome". *Prenat. Diagn.*, 1991, 11, 129.

Address reprint requests to:

A. BASGUL, M.D.

Ergenekon Caddesi, Feza Apartmani, Kat: 4 Daire 9
80240 Pangalti, Istanbul (Turkey)

Vaginal and uterine pressure response to semen deposition into the vagina and uterus: human study

A. Shafik¹, M.D., Ph.D.; I.A. Shafik¹, M.Ch., M.D.; O. El Sibai², M.D., Ph.D.

¹Department of Surgery and Experimental Research, Faculty of Medicine, Cairo University, Cairo

²Department of Surgery, Faculty of Medicine, Menoufia University, Shebin El-Kom (Egypt)

Summary

Purpose of investigation: The effect of semen deposition in the vagina or uterine cavity on both uterine and vaginal pressure has scarcely been reported in the literature. We investigated the hypothesis that semen deposition in the vagina or uterus effects changes in their pressure.

Methods: The study comprised 27 healthy women volunteers (mean age 36.4 ± 11.6 years). Both uterine and vaginal pressure were measured under basal conditions and on semen or saline deposition in the vagina and uterus.

Results: Upon semen deposition in the vagina, the vaginal pressure showed no significant changes ($p > 0.05$) while the uterine pressure exhibited a significant intermittent rise ($p < 0.05$). Semen deposition into the uterine cavity caused no vaginal pressure changes ($p > 0.05$) while the uterine pressure exhibited an intermittent increase ($p < 0.01$). Saline injection into the vagina or uterus showed no significant pressure changes ($p > 0.05$).

Conclusion: Semen deposition into the vagina or uterine cavity was associated with uterine pressure elevation that might eventually help transport the sperm to the oviduct. Further studies are required to define the substances responsible for this effect.

Key words: Uterus; Vagina; Semen; Coitus; Sexual intercourse.

Introduction

The semen consists of spermatozoa and seminal plasma which serves as a vehicle for sperm during ejaculation. Sperm are transported through various luminal fluids of different physiologic and biochemical characteristics such as testicular, epididymal, vasal, seminal, vaginal, uterine, oviductal and peritoneal fluids [1, 2]. The seminal plasma is derived from the vas deferens, the seminal vesicles and the prostatic gland, and the mucus from bulbourethral glands [3]. In addition it contains scant fluid from the testes and epididymis [4]. Fructose, phosphorylcholine, ergothioneine, ascorbic acid, flavins and prostaglandins are produced from the seminal vesicles, whereas spermine, citric acid, cholesterol, fibrinolysin, zinc and acid phosphatase are secreted from the prostate [4-6]. Other substances in the seminal plasma are phosphate and bicarbonate which act as buffers, as well as hyaluronidase [4, 5, 7]. The sperm find their way up to the oviduct and fertilizes the ovum. As the survival time of ova and spermatozoa is relatively short (20-48 hours), fertilization depends primarily on the synchronous transport of the gametes in the female reproductive tract [1]. Gamete transport is the result of the inherent contractility of the female tract as modified by central nervous system reflexes and hormonal activity [8-12].

The semen is deposited in the vagina during coitus. What could be the direct effect of the semen on the vagina and the uterus? We hypothesized that semen deposition in the vagina or uterine cavity would increase both vaginal and uterine pressure. This hypothesis was investigated in the current study.

Material and Methods

Subjects. Twenty-seven healthy women volunteered for the study after signing an informed consent. Their mean age was 36.4 ± 11.6 SD years (range 26-44). Eighteen were multiparous and nine nulliparous. The former had had normal vaginal deliveries. All the women were married and sexually active. They had regular menstrual cycles and no gynecologic complaint at the time of recruiting or in the past. Physical, neurologic and gynecologic examinations had normal findings. The study was approved by the Cairo University Faculty of Medicine Review Board and Ethics Committee.

Methods. Both uterine and vaginal pressure were evaluated under basal conditions and after semen or saline deposition in the vagina and uterus. The women were asked to abstain from coitus three days prior to testing so as to exclude the presence of residual semen. With the subject in the lithotomy position, a self-retaining speculum was introduced into the vagina. The cervix uteri were dilated with Hegar's dilators of a size from 2/5 to 3/6 mm. Uterine pressure was measured by means of a manometric tube of 0.5 mm inner and 1 mm outer diameter. It was perfused by a pneumohydraulic perfusion system (Arndolfer Medical Specialties, Greentale, WI, USA). The tube was introduced into the uterine cavity for 3-4 cm and connected to a strain gauge pressure transducer (Statham 230 B, Oxnard, CA, USA).

Vaginal pressure was measured simultaneously by a similar manometric tube inserted into the vagina for 3-4 cm and connected to a second Statham pressure transducer. The women as well as vagina and uterus, were allowed a 30-minute lapse to adapt to the inserted tubes before the test was performed.

The husbands of the women agreed to participate in the study after the test was explained to them and they gave written informed consent. They had normal semen characteristics in two semen examinations performed two weeks apart prior to the experiment. They were requested to give a semen sample to be deposited in the vagina of their respective wives. At first, we

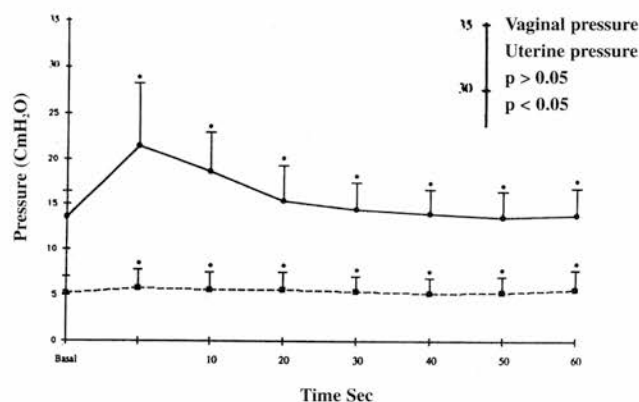


Figure 1. — Vaginal and uterine pressure recorded before and immediately after semen deposition in the vagina and every 10 sec thereafter for 60 min.

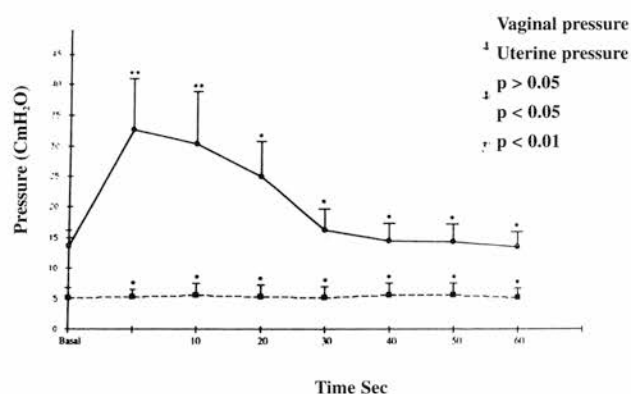


Figure 2. — Vaginal and uterine pressure recorded before and immediately after semen deposition in the uterus and every 10 sec thereafter for 60 min.

asked them to supply the sample via sexual intercourse with their wives while the pressure tubes were inserted. The tubes were thin enough not to interfere with coitus, as was confirmed by the subjects. However, by this method we could not assess the amount of semen deposited in the vagina because a portion of the semen was lost on the penile skin and outside the vagina. For this reason, we preferred to obtain the semen sample by masturbation. Three ml of the specimen were then placed in a seminal syringe connected to a polyethylene tubing. The latter was introduced into the posterior vaginal fornix while the woman was lying in the lithotomy position, and the semen was injected. Uterine and vaginal pressure were recorded before and after vaginal deposition of the semen and every ten seconds thereafter for ten minutes.

One week later the test was repeated with semen deposition into the uterus. The husband provided the semen sample by masturbation. Three ml of semen were injected into the uterine cavity by means of the syringe and the connected polyethylene tube which was introduced, through the cervix, into the uterine cavity. Vaginal and uterine pressure were measured before and after semen deposition into the uterus and every ten seconds thereafter for ten minutes. After one more week, 3 ml of saline instead of semen were injected into the vagina, and one week later into the uterine cavity, each time repeating the tests as mentioned above.

All the pressure measurements were repeated at least twice to assure reproducibility in the individual subject. The results were analyzed statistically using the Student's *t* test. Significance was ascribed to $p < 0.05$, and values were given as mean \pm standard deviation (SD).

Results

No complications were encountered during or after the performance of the tests, and all the women were evaluated. The resting pressure of the vagina recorded a mean of 5.2 ± 1.8 cm H₂O (range 4.6-7.4) and of the uterus a mean of 13.6 ± 3.2 cm H₂O (range 9.3-16.8) (Figure 1). The vaginal and uterine pressure after semen deposition in the vagina are shown in Figure 1. The vaginal pressure showed no significant changes ($p > 0.05$) after semen deposition into the vagina. In contrast, the uterine pres-

sure exhibited a significant rise ($p < 0.05$) 4-9 sec (mean 7.3 ± 1.2) after semen deposition into the vagina. The pressure rise was momentary, persisted for 12-30 sec (mean 17.3 ± 5.2) and then dropped to the basal level, to rise again after 18-35 sec (mean 26.6 ± 7.3). The repeated uterine pressure elevations recorded similar values each time ($p > 0.05$). They occurred for a mean period of 6.4 ± 1.2 minutes (range 4-8).

Figure 2 shows the uterine and vaginal pressure on semen deposition into the uterine cavity. The vaginal pressure showed no significant change from the basal values ($p > 0.05$). Meanwhile the uterine pressure increased 2-6 sec (mean 3.2 ± 0.7 , $p < 0.01$) after semen deposition in the uterus (Figure 2). After a mean of 7.3 ± 1.2 minutes of semen deposition (range 5-9), the uterine pressure no longer showed a significant rise against the basal pressure ($p > 0.05$; Figure 2). The rise in uterine pressure occurred for 23-38 seconds (mean 34.3 ± 4.8) and then dropped to the basal values. It rose again after 22-38 seconds (mean 28.6 ± 5.3). The pressure elevations were similar to each other with no significant difference ($p > 0.05$).

Saline injection into the vagina or uterus caused no significant pressure changes in the vagina or uterus compared to the basal values ($p > 0.05$). All pressure measurements were reproducible and showed no significant difference ($p > 0.05$) when the tests were repeated in the same individual.

Discussion

The current study demonstrates that the uterine pressure was elevated in the first 4-9 sec after semen deposition in the vagina. When semen was injected in the uterine cavity, the pressure rise occurred during the first 2-6 sec and recorded higher values than those recorded when semen was deposited in the vagina. The uterine pressure rise occurred in waves with values similar to each other. On the contrary, the vaginal pressure did not respond to semen deposition either in the vagina or uterine cavity.

The rise of uterine pressure seems to be due to the contractile activity of the uterus. The cause of pressure rise is unknown. It might be related to one or more of the substances contained in the seminal fluid. These substances might act directly on the uterus. Action through the blood or lymphatics may be excluded considering the spontaneity of the uterine response occurring a few seconds after semen deposition in the vagina or the uterine cavity. The question is how can the semen act directly on the uterus and evoke such rapid response although it was deposited into the vagina, i.e., away from the uterus? It might be assumed that some of the seminal plasma reaches the uterine cavity immediately after ejaculation, especially because the penis, during ejaculation or the polyethylene tubing during semen injection, are at or close to the uterine cervix so that the force of ejaculation or injection may help immediate passage of a part of the ejaculate to the uterine cavity. Furthermore, the uterine contractile activity as represented by the pressure rise might induce suction pressure action that might help the passage of more ejaculate to the uterine cavity. This view might be supported by the three stages recognized in the sperm transport [13]. In the rapid transport stage which occurs immediately after insemination, sperm penetrate the cervical mucus and are quickly transported through the cervical canal to the uterine cavity.

The suggested direct action of substances contained in the ejaculate on the uterus is evidenced not only by the rapid uterine pressure response to vaginal semen deposition but also by the pressure response to the semen deposition directly in the uterine cavity being rapid and higher than with deposition in the vagina. This might be attributable to the bigger amount of semen contained in the uterus when semen was directly deposited in the uterine cavity than the amount reaching the uterus when semen was placed in the vagina. On the other hand, it needs to be investigated in a further study whether the sperm or seminal plasma, the two components of semen, is responsible for the uterine pressure elevation. The role of high uterine pressure upon semen deposition needs to be evaluated.

Role of elevated uterine pressure on semen deposition

As mentioned above, the high uterine pressure indicates uterine contractile activity. The intermittent uterine contractile activity upon vaginal or uterine semen deposition might help the semen deposited in the vagina to pass to the uterine cavity. Uterine contractions followed by relaxation seem to act as a "pump" that sucks the semen from the vagina into the uterus and then pumps it up the uterine cavity to the oviduct. A "suction-ejection" pump might thus be created. When the semen gains access to the uterine cavity, it induces a higher pressure rise than when it is in the vagina, and consequently the pumping action is augmented. It would appear that any derangement in uterine pressure response as a consequence of abnormal semen quality or uterine pathology might result in fertility disorders.

In conclusion, the intermittent uterine pressure rise upon semen deposition in vagina seems to indicate uterine contractile activity which is suggested to act as a "suction-ejection pump" that helps sucking semen from the vaginal fornices into the uterus with subsequent transport up to the oviduct. Further studies are needed to define the substance or substances in the semen inducing the rise of uterine pressure.

Acknowledgment

M. Yehia and W. Reichelt assisted in preparing the manuscript.

References

- [1] Basu S.C.: "Semen analysis". In: "Male Reproductive Dysfunction". S.C. Basu (ed.), New Delli, India, Jaypee Brothers, 2005, 129.
- [2] Krause W., Viethen G.: "Quality assessment of computer-assisted semen analysis (CASA) in the andrology laboratory". *Andrologia*, 1999, 31, 125.
- [3] Guyton A.C.: "Male reproductive functions: the male sex hormones and the pineal gland". In: A.C. Guyton (ed.), *Human Physiology and Mechanisms of Disease*. 6th edition. Philadelphia, WB Saunders, PA, 1997, 648.
- [4] Mann T., Lutwak-Mann C. (eds.): "Male reproductive function and semen: Themes and trends in physiology, biochemistry and investigative andrology". Berlin, Springer-Verlag, 1981, 28.
- [5] Ewald E.S.: "The reproductive system". In: E.S. Ewald (ed.), *Basic Physiology for Health Sciences*. Boston, MA, Little Brown, 1982, 572.
- [6] Carrell D.T.: "Semen analysis at the turn of the century: an evaluation of potential uses of new sperm function assays". *Arch. Androl.*, 2000, 44, 65.
- [7] Rosecrans R.P., Jeyenran A.S., Perez Pelaez, Kennedy W.P.: "Comparison of the biochemical parameters of human blood serum and seminal plasma". *Andrologia*, 1987, 19, 625.
- [8] Shafik A.: "Study of the intramural oviduct response to tubal and uterine distension: Identification of tubo-uterine sphincter and reflex". *Human Reprod.*, 1996, 11, 2527.
- [9] Shafik A.: "Electro-oviductogram: A study of the electromechanical activity of the canine oviduct". *Gynecol. Obstet. Invest.*, 1996, 42, 253.
- [10] Shafik A.: "Electrohysterogram: Study of the electromechanical activity of the uterus in humans". *Eur. J. Obstet. Gynecol. Reprod. Biol.*, 1997, 73, 85.
- [11] Moran C., Garica Hernandez E., Carranza E., Carranza-Lira S., Cortes A., Varon J. *et al.*: "Prognosis for fertility analyzing different variables in men and women. (A cohort of 123 infertile couples was studied)". *Arch. Androl.*, 1996, 36, 197.
- [12] Hilgers T.W., Daly K.D., Prebil A.M., Hilgers S.K.: "Cumulative pregnancy rates in patients with apparently normal fertility and fertility-focused intercourse". *J. Reprod. Med.*, 1992, 37, 864.
- [13] Pedersen H., Fawcett D.W.: "Functional anatomy of the human spermatozoon". In: E.S.E. Hafez (ed.), *Human Semen and Fertility Regulation in Men*, St Louis, MO, CV Mosby, 1976.

Address reprint requests to:
A. SHAFIK, M.D., Ph.D.
2 Talaat Harb Street
Cairo 11121 (Egypt)