

# Ovarian ossification associated with endometriosis

R. Shaco-Levy<sup>1</sup>, M.D., T. Lazer<sup>2</sup>, M.D., B. Piura<sup>2</sup>, M.D., F.R.C.O.G., A. Wiznitzer<sup>2</sup>, M.D.

Department of Pathology<sup>1</sup>, Department of Obstetrics and Gynecology<sup>2</sup>, Soroka University Medical Center and Faculty of Health Sciences, Ben-Gurion University of the Negev, Beer-Sheva (Israel)

## Summary

**Background:** Bone formation in the ovary, with the exception of developing in the setting of mature cystic teratoma, is exceedingly rare. **Case:** A 46-year-old woman with a history of endometriosis and chronic pelvic pain underwent total abdominal hysterectomy and bilateral salpingo-oophorectomy. A 3 cm solid heavily calcified mass with a stony hard consistency was detected within the right ovary. Microscopic examination revealed extensive calcification of the right ovarian stroma with formation of abundant mature bone, adjacent to small foci of endometriosis. **Conclusions:** Endometriosis can be associated with ovarian ossification, forming an extensively calcified adnexal mass. Conservative treatment with close follow-up may be adequate in patients with a history of endometriosis who present with a small heavily calcified ovarian mass and wish to preserve their fertility.

**Key words:** Ovary; Endometriosis; Ossification; Calcification.

## Introduction

Bone formation in the ovary, with the exception of developing in the setting of mature cystic teratoma, is exceedingly rare [1]. Sporadic cases of osseous metaplasia occurring in ovarian serous cystadenocarcinoma [2], mucinous cystadenomas [1, 3], fibromas and leiomyomas [4] are described as single case reports. Bone formation in the ovary with no clear underlying cause, which probably represents heterotopia or metaplasia of the connective tissue of the ovary, has also been reported as two single case reports [5, 6]. To the best of our knowledge, only two cases of bone formation within the ovary in association with endometriosis have been reported in the English literature [7, 8]. We describe an unusual case of extensive ossification and calcification of an ovarian stroma, associated with small foci of endometriosis.

## Case Report

A 46-year-old, para 3, Caucasian woman, was admitted because of menorrhagia and lower abdominal pain. Her past medical history included endometriosis and left partial oophorectomy performed due to an endometriotic cyst. Physical examination disclosed an essentially healthy appearance and normal vital signs. Pelvic examination revealed a mildly enlarged uterus and bilateral adnexal masses. Ultrasound examination confirmed bilateral adnexal cysts, a 3-cm right ovarian mass with hyperechogenic foci, and a mildly enlarged uterus with an intramural mass compatible with leiomyoma in the posterior uterine wall. At laparotomy, foci of endometriosis were identified on both ovaries, and a well-defined stony hard mass was detected within the right ovary. Total abdominal hysterectomy and bilateral salpingo-oophorectomy (TAH&BSO) were performed. Postoperative recovery was unremarkable.

Pathological examination of the TAH&BSO specimen revealed an enlarged uterus with extensive adenomyosis and a leiomyoma. The left ovary was partially replaced by endometriotic cysts. The right ovary showed small foci of endometriosis, and was distorted by a 3 cm well-defined slightly lobulated white firm mass appearing exactly like a stone. Microscopically this mass showed a peculiar zone formation, with a deep region showing ovarian stroma heavily infiltrated by lymphocytes and foamy and hemosiderin-laden macrophages with formation of cholesterol clefts, a midportion composed of well-formed bone (Figure 1), and a peripheral portion showing extensive calcifications adjacent to hyalinized connective tissue. Only two microscopic foci of endometriosis were identified within this ovarian "stone".

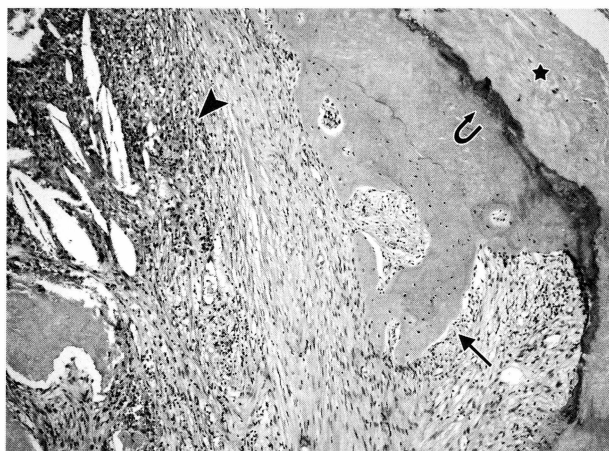


Figure 1. — Well-formed bone (arrow) adjacent to inflamed ovarian stroma (arrowhead). Calcification (curved arrow) and dense fibrosis (asterisk) are also evident (hematoxylin & eosin, original magnification x100).

## Discussion

This report documents a case of extensive ossification with adjacent calcification of the ovarian stroma, arising in the background of endometriosis, a lesion that to our knowledge has been reported in the English literature only twice [7, 8]. The foci of bone formation had peculiar zone formations, with a deep region of inflamed ovarian stroma with microscopic foci of endometriosis, a midportion composed of well-formed bone, and a peripheral portion showing extensive calcifications adjacent to a hyalinized connective tissue. This "zonal phenomenon" is somewhat reminiscent of myositis ossificans, a reactive process of bone formation that occurs in soft tissues [9]. Thus, since the foci of ossification arose in the background of endometriosis with inflammation and showed zonal formation, we assume that the process of ossification in the presented case was reactive; possibly ovarian endometriosis with its associated inflammatory response served as the stimulus for dystrophic calcification followed by osseous metaplasia of undifferentiated stromal mesenchymal cells. This may be similar to ossification seen in the endometrium, a more common site for ossification in the female reproductive system. Endometrial heterotopic bone tissue is associated with chronic endometritis [10], or more commonly with prior pregnancy, repeated abortions or instrumentation [11]. Thus, it is possible that the ovarian stromal cells undergo osseous metaplastic transformation, in a similar fashion to the rare cases of heterotopic bone in the endometrium of women with a history of chronic endometritis [10].

A rare case of hyaline cartilage formation adjacent to endometriosis is documented [12]. Thus, endometriosis, probably with its accompanying inflammatory response, has the ability to initiate a process of metaplasia in the surrounding tissues.

A calcified adnexal mass demonstrated by ultrasound or CT-scan warrants the diagnosis of calcified ovarian tumor, for which surgical intervention is the treatment of choice [7]. However, extensive calcification in otherwise ultrasonographically normal ovaries is likely to prove benign and even not neoplastic [7, 13], warranting careful consideration when contemplating surgical intervention. In our case extensive calcification and ossification occurred with endometriosis of the ovary, and formed a small heavily calcified ovarian mass. It seems that follow-up may be adequate in this setting, especially when the lesion is discovered in a young woman with a history of endometriosis who wants to preserve her fertility. Our patient suffered from pelvic pain and menor-

rhagia due to endometriosis and adenomyosis. As she was not interested in preserving her fertility, TAH&BSO was carried out.

## Conclusion

This report documents a rare case of ovarian endometriosis associated with extensive calcification and bone formation. Thus, an extensively calcified adnexal mass could be attributed to endometriosis, and this possibility should be raised, especially in women with a history of endometriosis. Conservative treatment with close follow-up may be adequate in patients who want to preserve their fertility.

## References

- [1] Zahn C.M., Kendall B.S.: "Heterotopic bone in the ovary associated with a mucinous cystadenoma". *Mil. Med.*, 2001, 166, 915.
- [2] Barua R., Cox L.W.: "Occurrence of bone in serous cystadenocarcinoma of the ovary". *Aust. N. Z. J. Obstet. Gynaecol.*, 1982, 22, 183.
- [3] Misselevich I., Boss J.H.: "Metaplastic bone in a mucinous cystadenoma of the ovary". *Pathol. Res. Pract.*, 2000, 196, 847.
- [4] Talerman A.: "Nonspecific tumors of the ovary, including mesenchymal tumors and malignant lymphoma". In: Kurman R.J., "Blaustein's Pathology of the Female Genital Tract", 5th edition, New York, Springer-Verlag, 2002, 1035.
- [5] Shipton E.A., Meares S.D.: "Heterotopic bone formation in the ovary". *Aust. N. Z. J. Obstet. Gynecol.*, 1965, 5, 100.
- [6] Ding D.C., Yu M.H., Liu J.Y.: "Autocalcification of the ovary". *Int. J. Gynecol. Obstet.*, 2002, 79, 249.
- [7] Su W.H., Wang P.H., Chang S.P.: "Ovarian stone – a case report". *J. Reprod. Med.*, 2002, 47, 329.
- [8] Badawy S.Z.A., Kasello D.J., Powers C., Elia G., Wojtowycz A.R.: "Supernumerary ovary with an endometrioma and osseous metaplasia: a case report". *Am. J. Obstet. Gynecol.*, 1995, 173, 1623.
- [9] Sumiyoshi K., Tsuneyoshi M., Enjoji M.: "Myositis ossificans. A clinicopathologic study of 21 cases". *Acta Pathol. Jpn.*, 1985, 35, 1109.
- [10] Ganem K.J., Parsons L., Friedell G.H.: "Endometrial ossification". *Am. J. Obstet. Gynecol.*, 1982, 83, 1592.
- [11] Newton C.E. III, Abell M.R.: "Iatrogenic fetal implants". *Obstet. Gynecol.*, 1973, 40, 686.
- [12] Jirasek J.E., Henzl M.R., Uher J.: "Periovarian peritoneal adhesions in women with endometriosis. Structural patterns". *J. Reprod. Med.*, 1998, 43, 276.
- [13] Clement P.B., Cooney T.P.: "Idiopathic multifocal calcification of the ovarian stroma". *Arch. Pathol. Lab. Med.*, 1992, 116, 204.

Address reprint requests to:  
R. SHACO-LEVY, M.D.  
Department of Pathology  
Soroka Medical Center  
POB 151 - Beer-Sheva 84101  
(Israel)