

Double cervix, septate uterus, and longitudinal vaginal septum: a rare Müllerian anomaly with leiomyoma of the uterus

Ş. Gezer¹, B. Vural¹¹Department of Obstetrics and Gynecology, Kocaeli University School of Medicine, Kocaeli (Turkey)

Summary

Objective: To discuss a rare anomaly, double cervix, septate uterus, and longitudinal vaginal septum with a leiomyoma of the uterus. **Case Report:** A case of double cervix, septate uterus, and longitudinal vaginal septum that underwent surgery for incomplete uterine septoplasty and subserosal leiomyoma. **Conclusion:** Combination of leiomyoma with complete septate uterus, cervical duplication, and longitudinal vaginal septum is a rare entity. Treatment options should be individualized for patients' expectations.

Key words: Septate uterus; Vaginal septum; Cervical duplication; Leiomyoma.

Introduction

A complete septate uterus with cervical duplication and longitudinal vaginal septum is a rare congenital anomaly. This anomaly could be the result of non-fusion of the Müllerian ducts or the non-resorption of the septum formed by fusion. Some authors consider this a variant of complete uterine septum (Type Va) [1], others consider it as an unclassified anomaly [2]. Embryologic theories to explain the development of this anomaly include the unidirectional theory, which hypothesizes that development proceeds cranial to caudal [3], and the bidirectional theory, which proffers simultaneous cranial and caudal development [4, 5]. One case of leiomyoma on the septum of septate uterus with double cervix and vaginal septum has previously been reported [6]. Treatment is a subject of controversy, but if the patients become symptomatic from dyspareunia, infertility, and recurrent pregnancy loss, uterine septoplasty and vaginal excision of the septum are a good treatment option [7]. Here, the authors present a case of septate uterus with cervical duplication and longitudinal vaginal septum with leiomyoma that had undergone previous surgery for a uterine and vaginal septum. The authors performed a second hysteroscopic septoplasty for insufficient excision of the uterine septum and laparoscopy for subserosal leiomyoma on the septum of the uterus.

Case Report

A nulligravid woman aged 25 years was admitted to this hospital with infertility. Her husband was oligospermic. She underwent surgery in another hospital three years ago because of pain during vaginal penetration and infertility. Excision of a longitu-

dinal vaginal septum and hysteroscopic excision of a uterine septum was performed in the first operation. The uterus was noted as normal during the laparoscopic examination. A transvaginal ultrasound examination demonstrated a subserosal leiomyoma 3×3 cm in diameter on the posterior of the uterine septum. The hysterosalpingography revealed insufficiently excised thick uterine septum (Figure 1). The uterus was normal in laparoscopy except of for the subserosal 3×3-cm pedunculated leiomyoma on the posterior (Figure 2). A laparoscopic myomectomy was performed.

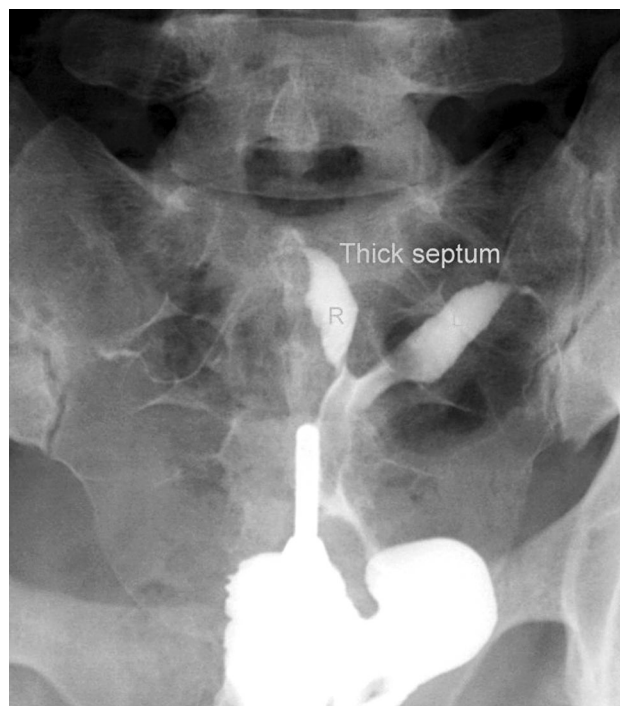

Figure 1. — Thick septum on hysterosalpingography.

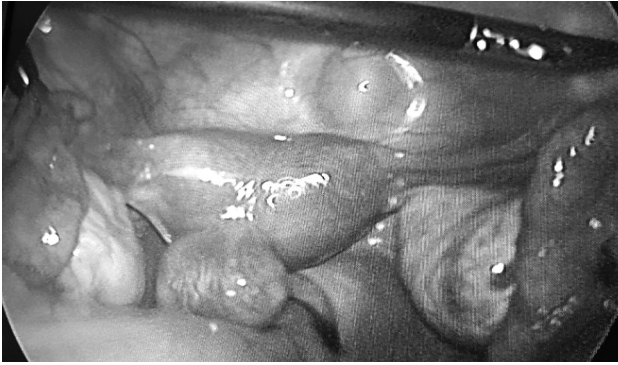

Figure 2. — Laparoscopic view of leiomyoma.

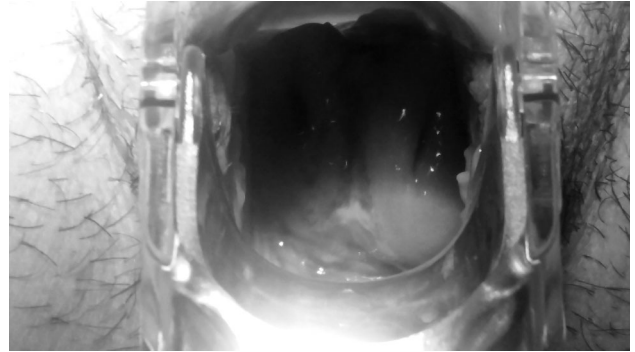


Figure 3. — Double cervix on gynecological examination.

Double cervix was seen in a gynecologic examination but a longitudinal septum could not be seen because it was excised in the first operation (Figure 3). The operative hysteroscopy was then inserted and two cavities were observed related to each other. Thick septum was observed beginning at 2 cm proximal to the internal cervical os. Unipolar resection of the uterine septum was performed under the guidance of 12 F Foley catheter, which was previously inserted in the other uterine cavity. Methylene blue was given from each cervical orifice and the tubal passage was seen bilaterally under laparoscopic observation. After six months she has not conceived.

Discussion

A complete septate uterus with cervical duplication and longitudinal vaginal septum is a rare congenital condition. The true incidence of this anomaly might be greater than reported because physicians usually misdiagnose it as uterus didelphys [7]. When Müllerian duct anomalies are suspected, ultrasound is usually the first examination ordered. More definitive diagnostic modalities include magnetic resonance imaging, hysterosalpingography, hysteroscopy, and laparoscopy. Treatment for Müllerian duct anomalies is variable and depends on the type of anomaly. It is uncertain what type of treatment is necessary for this congenital Müllerian anomaly because it is rare.

Prophylactic metroplasty of the uterine septum in patients with no history of previous miscarriages or pregnancy complications is controversial [8]. Lin *et al.* compared reproductive outcomes of 21 treated women who underwent vaginal and uterine septum resection and 15 untreated women. Cycle fecundity and the rate of term delivery was increased, and the rate of spontaneous abortion was decreased in the treatment group. However, they found no significant effect of hysteroscopic septum resection on primary infertility. The authors thought that the improvement in cycle fecundity was related to vaginal enlargement, penile access to both cervixes, and the increased capacity of sperms to travel into the two oviducts [9]. Patton *et al.* reported 17 pregnancies (14 live births or ongoing third trimester pregnancies after hysteroscopic resection (9/12) or abdominal metroplasty (5/5)) in 16 women with com-

plete septate uterus with cervical duplication and longitudinal vaginal septum [7].

Many of these patients had thick uterine septa which contained substantial myometrial tissue. Therefore this is similar to uterus didelphys and they could be managed expectantly [10]. On the other hand, if we accept these patients as having class V anomalies, they will benefit from uterine septum resection. Some authors advocate not resecting the uterine septum in patients with no history of recurrent pregnancy loss because it can lead to pregnancy complications such as cervical incompetence and uterine perforation [11, 12].

Combination of leiomyoma with this Müllerian anomaly (complete septate uterus with cervical duplication and longitudinal vaginal septum) was previously reported by Eray *et al.* [6]. Their patient was had dyspareunia and infertility. The authors performed a two-step operation; first, a laparotomic excision of the leiomyoma on the uterine septum and vaginal septum excision. Second, the uterine septum was excised through hysteroscopy and the two cervixes were unified using fine scissors. The woman reached the third trimester of pregnancy without any evidence of cervical incompetence.

In conclusion, treatment options should be individualized in cases of complete septate uterus with double cervix and vaginal septum. In this case, the reason for surgery was to complete the incomplete hysteroscopic septoplasty procedure and to excise the subserosal leiomyoma laparoscopically. The authors preferred laparoscopic excision of the leiomyoma and hysteroscopic septoplasty, which is a simpler technique than abdominal metroplasty, because the leiomyoma had a subserosal location.

References

- [1] Buttram Jr. V.C., Gomel V., Siegler A., DeCherney A., Gibbons W., March C.: "The American Fertility Society classifications of adnexal adhesions, distal tubal occlusion, tubal occlusion secondary to tubal ligation, tubal pregnancies, Müllerian anomalies and intrauterine adhesions". *Fertil. Steril.*, 1988, 49, 944.
- [2] Pavone M.E., King J.A., Vlahos N.: "Septate uterus with cervical duplication and a longitudinal vaginal septum: a müllerian anomaly without a classification". *Fertil. Steril.*, 2006, 85, 494.e9.

- [3] Crosby W.M., Hill E.C.: "Embryology of the müllerian duct system. Review of present-day theory". *Obstet. Gynecol.*, 1962, 20, 507.
- [4] Muller P., Musset R., Netter A., Solal R., Vincourd J.C., Gillet J.Y.: "Etat du haut appareil urinaire chez le porteuses de malformations uterines. Etude de observations". *Presse. Med.*, 1967, 75, 133.
- [5] Hundley A.F., Fielding J.R., Hoyte L.: "Double cervix and vagina with septate uterus: an uncommon mullerian malformation". *Obstet. Gynecol.*, 2001, 98, 982.
- [6] Caliskan E., Cakiroglu Y., Turkoz E., Corakci A.: "Leiomyoma on the septum of a septate uterus with double cervix and vaginal septum: a challenge to manage". *Fertil. Steril.*, 2008, 89, 456.e3.
- [7] Patton P.E., Novy M.J., Lee D.M., Hickok L.R.: "The diagnosis and reproductive outcome after surgical treatment of the complete septate uterus, duplicated cervix and vaginal septum". *Am. J. Obstet. Gynecol.*, 2004, 190, 1669.
- [8] Parsanezhad M.E., Alborzi S., Zarei A., Dehbashi S., Shirazi L.G., Rajaeefard A., Schmidt E.H.: "Hysteroscopic metroplasty of the complete uterine septum, duplicate cervix and vaginal septum". *Fertil. Steril.*, 2006, 85, 1473.
- [9] Lin K., Zhu X., Xu H., Liang Z., Zhang X.: "Reproductive outcome following resectoscope metroplasty in women having a complete uterine septum with double cervix and vagina". *Int. J. Gynaecol. Obstet.*, 2009, 105, 25.
- [10] Nigam A., Puri M., Trivedi S.S., Chattopadhyay B.: "Septate uterus with hypoplastic left adnexa with cervical duplication and longitudinal vaginal septum: Rare Mullerian anomaly". *J. Hum. Reprod. Sci.* /2010, 3, 105.
- [11] Duffy D.A., Nulsen J., Maier D., Schmidt D., Benadiva C.: "Septate uterus with cervical duplication: a full-term delivery after resection of a vaginal septum". *Fertil. Steril.*, 2004, 81, 1125.
- [12] Heinonen P.K.: "Complete septate uterus with longitudinal vaginal septum". *Fertil. Steril.*, 2006, 85, 700.

Corresponding Author:

Ş. GEZER, M.D.

Division of Gynecologic Oncology

Department of Obstetrics and Gynecology

Kocaeli University School of Medicine

Kocaeli (Turkey)

e-mail: dr.senergezer@gmail.com