

Application of ultrasound in hepatic pregnancy: a case report and literature review

Xiao-Hua Li¹, Jian-Kun Zhou², Jing-Dan Cheng^{1,*}

¹Department of Ultrasonography, Affiliated Hospital of Jining Medical University, 272000 Jining, China

²Information Network Center, Shandong Polytechnic College, 272077 Jining, China

*Correspondence: cjdjining@163.com (Jing-Dan Cheng)

DOI: [10.31083/j.ceog.2021.02.5202](https://doi.org/10.31083/j.ceog.2021.02.5202)

This is an open access article under the CC BY-NC 4.0 license (<https://creativecommons.org/licenses/by-nc/4.0/>).

Submitted: 25 March 2019 Revised: 24 July 2020 Accepted: 28 July 2020 Published: 15 April 2021

As an ectopic pregnancy, hepatic pregnancy is extremely rare. Early diagnosis and treatment may prevent acute bleeding caused by the invasion of trophoblasts into maternal hepatic vessels. Here, we report a case of hepatic pregnancy diagnosed by ultrasonography in early pregnancy. Diagnostic laparoscopy, followed by laparotomy, was carried out and the intrahepatic mass was excised, and pathological results confirmed the ultrasonographic findings. Based on a current literature review, this report aims to investigate the ultrasonic features of hepatic pregnancy and summarize the application of ultrasonography in the diagnosis and treatment of hepatic pregnancy.

Keywords

Abdominal pregnancy; Ectopic pregnancy; Ultrasonography; Hepatic pregnancy; Preoperative diagnosis

1. Introduction

As an ectopic pregnancy, hepatic pregnancy is extremely rare. Given that the hepatic parenchyma is highly vascularized, with the invasion of trophoblasts, hepatic pregnancy may lead to acute massive hemorrhage that endangers the pregnant woman's life [1]. If an early diagnosis of hepatic pregnancy is made prior to acute rupture and followed with appropriate treatment, the patient can have a good prognosis. However, hepatic pregnancy is often misdiagnosed due to its rarity, and the diagnosis is even more challenging clinically when the ectopic pregnancy mass is relatively small or imaging characteristics are atypical. In some cases, a ruptured hepatic pregnancy is identified as the source of bleeding during emergency surgery in patients who present with an acute abdomen [2, 3]. Here, we report a case of hepatic pregnancy diagnosed early in the first trimester based on ultrasonographic findings. The ultrasonographic characteristics of hepatic pregnancy are analyzed, and the current literature on the application of ultrasonography in hepatic pregnancy is reviewed.

2. Case presentation

A 30-year-old woman (gravida 1, para 1) was admitted to our hospital with a complaint of amenorrhea for 63 days and vaginal bleeding for 15 days. She had normal menstruation and underwent a cesarean delivery in a local hospital four years before admission. The patient had visited another

local secondary hospital 15 days before, 8 days before and 3 days before admission, and the serum β -human chorionic gonadotropin (β -HCG) level was tested and transvaginal ultrasonography performed each time. The results showed that the serum β -HCG level was gradually increasing (no specific β -HCG level was obtained for each essay), and no gestational sac or suspicious mass was found in the uterus or pelvic cavity. The patient was highly suspected of ectopic pregnancy and transferred to our hospital.

Upon admission to our hospital, the patient showed an elevated serum β -HCG level of 17,193 U/L. A repeated transvaginal ultrasonography scan revealed no positive findings. Then the entire abdominal cavity was carefully scanned with an abdominal convex probe, and no obvious effusion or abnormal mass was found in the abdominal cavity, however, an abnormal nodule with a hyperechoic ring and cystic center was accidentally found in the right lobe of the liver when we explored the space between liver and kidney, and peripheral blood flow signals were detected in the nodule. A diagnosis of hepatic pregnancy was considered with an estimated gestational age of 9 weeks based on the patient's last menstrual period (Fig. 1). An enhanced spiral computed tomography (CT) scan of the upper abdomen confirmed the findings by revealing a cystic and solid mass enriched with blood vessels in the lower right posterior lobe of the liver (Fig. 2).

No abnormality was detected in the patient's preoperative examination. Considering the high level of HCG, surgical treatment rather than methotrexate was chosen to prevent the rupture of ectopic pregnancy during conservative treatment. An exploratory laparoscopy performed on the following day revealed normal fallopian tubes and ovaries, and no blood in the pouch of Douglas; however, an abnormal lesion in paragraph VI of the liver was detected. To avoid life-threatening haemorrhage, laparotomy was immediately carried out to remove the intrahepatic mass. The surgery was successful, and the mass was completely excised. The pathological results revealed an ectopic pregnancy in the liver (Fig. 3). A follow-up ultrasonography scan performed one month later showed no abnormality in the liver or pelvic cavity.

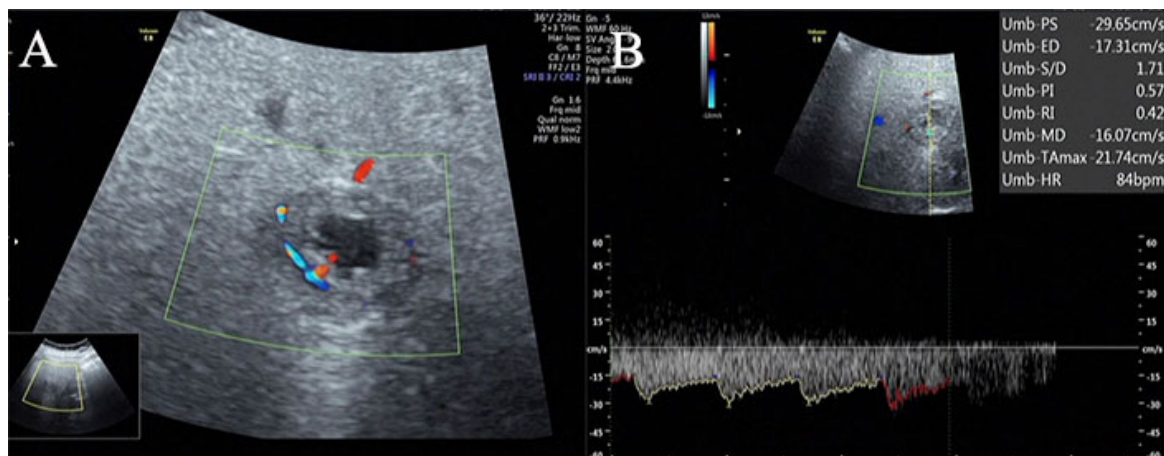


Fig. 1. Abdominal ultrasonography scan showing a nodule with a hyperechoic ring and cystic center in the right lobe of the liver, and strip blood flow signals were detected at the edge of the nodule. (A) Doppler examination of the blood flow revealing an arterial spectrum, RI: 0.42. (B) Except for the nodule, an echo of other regions of the liver were normal.

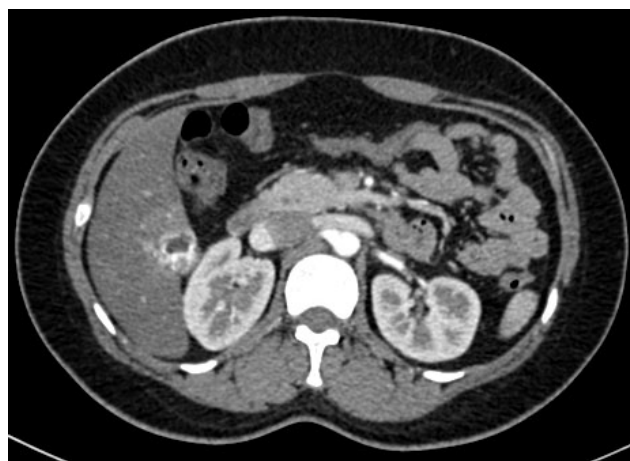

Fig. 2. CT scan revealing a solid and cystic abnormal mass in the right lobe of the liver, and during the arterial phase, the enhancement of peripheral solid components of the lesion dramatically increased.

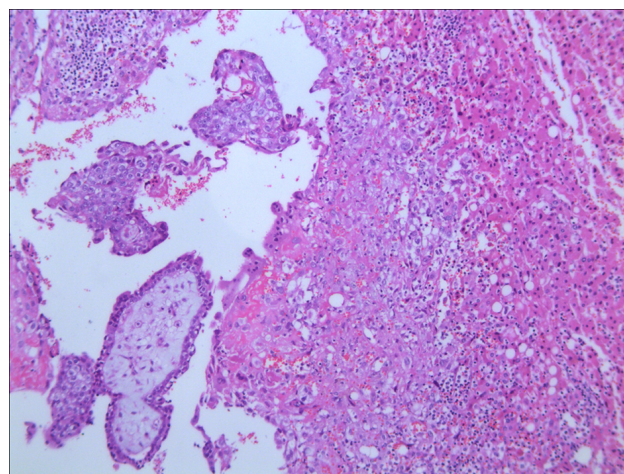


Fig. 3. Histologic examination showing a large number of well-developed chorionic villi and trophoblasts invading the liver parenchyma (H&E, original magnification $\times 40$), consistent with the diagnosis of primary hepatic pregnancy.

3. Discussion

Approximately 95% of ectopic pregnancies occur within fallopian tubes, with fewer arising in the cervix, ovaries and the abdominal cavity. An abdominal pregnancy is defined as the implantation of a fertilized egg in the peritoneum, mesentery or omentum, and they are extremely rare. Abdominal pregnancies may be primary or secondary. The secondary type is the result of re-implantation of the fetal sac onto the peritoneal surface after rupture of a tubal ectopic pregnancy and more frequent. Abdominal pregnancies account for 1% of ectopic pregnancies, with an incidence of 1 : 10,000–1 : 30,000 among all pregnancies [4]. Hepatic pregnancy, a specific type of abdominal pregnancy, means that the principal site of implantation is the liver. The presenting symptoms of early hepatic pregnancy are generally variable and clinically atypical, including amenorrhea, abdominal pain, vaginal bleeding, an increased serum HCG level, and even hemorrhagic shock, which makes the diagnosis challenging. There-

fore, hepatic pregnancy is commonly misdiagnosed in early pregnancy.

From a nutritional point of view, the liver is a favorable site of implantation because of its abundant vascular supply. However, the decidual reaction around an ectopic fetus in the liver is absent or incomplete, and maternal liver blood vessels may be invaded by trophoblasts, which may disrupt the implantation site and cause massive abdominal hemorrhage, resulting in an acute abdomen, with a mortality rate 7.7 times that of ectopic tubal pregnancy, and 90 times that of intrauterine pregnancy [1]. In some cases, a diagnosis of hepatic pregnancy can only be made after surgical intervention and pathological examination [1]. However, if partial disruption occurs, the hepatic pregnancy may continue until term without further bleeding or slight bleeding [5]. The symptoms of advanced hepatic pregnancy are also confusing, and they include abdominal discomfort, vaginal bleeding,

decreased or painful fetal movement, gastrointestinal symptoms, and urinary symptoms [6, 7]. The diagnosis can be made incidentally on transabdominal ultrasonography.

Early diagnosis is the most effective means of reducing the current mortality rate of hepatic pregnancy. The primary imaging modalities for hepatic pregnancy are ultrasonography, CT and magnetic resonance imaging (MRI). Ultrasonography is a simple, safe and cost-effective imaging modality. Compared with CT, ultrasonography causes no radiation damage; therefore, it is more accepted by pregnant women. Furthermore, ultrasonography is the preferred option when it is difficult to distinguish clinically between a very early intrauterine pregnancy and an ectopic pregnancy.

We searched the PubMed database for hepatic pregnancy-related English language articles from 1 January 1956 to 31 December 2018 using key search terms as follows “hepatic ectopic”, “hepatic pregnancy”, “intrahepatic pregnancy” and “pregnancy in the liver”, and 33 published articles were identified and reviewed. We found that the preoperative diagnostic rate of hepatic pregnancy improved significantly due to the application of ultrasonography. The ultrasound diagnosis of hepatic pregnancies was first described in 1989 [8]. Before December 1988, ten cases of hepatic pregnancy [5, 9–17] had been reported, two of which were diagnosed preoperatively by X-ray [16, 17], accounting for 20%, and eight of which were diagnosed during intraoperative exploration or after postoperative pathology, accounting for 80%. From January 1989 to December 2018, 23 cases of hepatic pregnancy have been reported, including 18 cases [5, 8, 9, 11, 18–31] diagnosed preoperatively by ultrasonography (78.3%), two cases by other imaging modalities (including one by CT [2] and one by CT combined with MRI [32]), accounting for 8.7%, and three cases diagnosed by emergency laparotomy [33, 34] or laparoscopy [3], accounting for 13.0%. A description of the 18 cases diagnosed by abdominal ultrasound is presented in Table 1. Of the 18 cases, 12 were in the first trimester, five were beyond the first trimester, and no exact pregnancy time was documented in one case. According to the literature and our case, three ultrasonographic characteristics of early hepatic pregnancy have been reported, namely a well-defined pregnancy sac with or without a fetal heartbeat, an inhomogenous mass and a hyperechoic ring with a cystic center on or within the liver. As for an advanced hepatic pregnancy, the most frequent ultrasound findings include an empty uterus that is separate from the fetus, lack of myometrial tissue surrounding the fetus and an ectopic placenta attached to the liver [6].

Management of hepatic pregnancy described in the literature varies from surgery, either laparoscopy or laparotomy, to conservative alternatives, including medical therapy and expectant management. In addition to its importance in the diagnosis of hepatic pregnancy, ultrasonography has great significance in other treatments, including surgical and non-surgical options. For example, postoperative follow-up ultrasonography can monitor the residual placenta left *in situ* during surgery, and demonstrate whether the mass disappears

or abdominal or pelvic fluid collects. The application of ultrasonography makes it possible to use medical and expectant treatments for hepatic pregnancies. Medical treatments described in the literature include ultrasound-guided intracardiac potassium chloride (KCl) or feticide combined with maternal intramuscular injection of methotrexate (MTX), and only intramuscular injection of MTX. Medical treatments are conducted effortlessly under the guidance of ultrasound, and a follow-up ultrasonography scan can evaluate the reduction in size of the mass [4, 21]. When the fetus in an abdominal pregnancy is more than 20 gestational weeks, expectant treatments may be applied to deliver a live infant [7]. Ultrasonography is used to closely monitor the fetus and placenta and determine the termination time. Expectant treatments for hepatic pregnancies were carried out and live infants were delivered in two articles [6, 7]. Ramphal *et al.* [7] described a case in which the hepatic pregnancy was diagnosed at 19 weeks of gestation, and the decision was made to terminate the pregnancy when ultrasound showed reduced liquor at 34 weeks of gestation, without any maternal or fetal complications. Brouard *et al.* [6] described another case of hepatic pregnancy, which was not diagnosed by routine ultrasonography until 37 weeks of gestation. An ultrasonography scan revealed an empty uterus that was separated from the fetus; it was near to the liver so a hepatic pregnancy was suspected. At laparotomy, the diagnosis was confirmed and a live infant was delivered successfully.

Although ultrasonography plays important roles in the diagnosis and treatment of hepatic pregnancy, it inevitably has its limitations. The ultrasonographic criterion for the diagnosis of ectopic pregnancy is a pregnancy sac attached anywhere other than the uterine cavity, and it has a high specificity but a poor sensitivity [24]. In some cases, ultrasonography is not sensitive enough to show clearly the blood flow to early ectopic pregnancy, and when an advanced hepatic pregnancy is encountered, ultrasonography often fails to show clearly where the placenta is attached [6]. The advantages of CT and MRI are that they may accurately locate the ectopic pregnancy and clearly show its relationship with the surrounding structures. In addition, both methods may provide a more accurate evaluation of the blood supply to the mass, and in some cases, MRI may identify the site of placental attachment more clearly, thus helping to determine whether to remove the placenta or leave it in place during surgery [23]. In our case, the hepatic pregnancy was first detected by ultrasonography, and further confirmed by enhanced CT, and finally confirmed by surgery and pathology. Therefore, ultrasonography is a primary evaluation modality for hepatic pregnancies, and CT and MRI may provide information on the exact regional anatomy as well as other detailed information.

Table 1. Basic data collected from case reports on ultrasonography in hepatic pregnancies.

Year	Age	Pregnancy in lobe of liver	Clinical manifestation	Meno-pause (week)	Elevated serum HCG or positive urine HCG	Sonographic features	The size of the mass (cm)	Fetal heart beat	Therapeutic method	Outcome	Complication	Follow-up ultrasound
1989 [8]	23	Right	NA	14	NA	GS	NA	Yes	LAT	Cure	NA	NA
1995 [19]	32	CL	Abdominal pain, vomit, acute peritonitis, vaginal bleeding, nausea	NA	Yes	S-GS	2.3 × 2.2	No	LAT and intraoperative injection of MTX intopregnancy sac	Cure	Ileus	NA
1999 [20]	46	Right	Abdominal pain, shock	12	Yes	GS	NA	Yes	LAT	Cure	NA	NA
2007 [7]	NA	Right	Abdominal pain	11	Yes	GS	NA	Yes	Injection of MTX and KCl via liver under ultrasound guidance, maternal intramuscular injection of MTX Injection of KCl and fetocide via liver under ultrasound guidance, maternal intramuscular injection of MTX	Cure	NA	Yes
2010 [21]	19	Right	No	18	NA	GS	NA	Yes	LAT	Live birth	No	Yes
2010 [22]	23	Right	Abdominal pain, nausea, gallstone	12	Yes	GS	NA	Yes	Injection of KCl and fetocide via liver under ultrasound guidance, maternal intramuscular injection of MTX	Cure	No	Yes
2012 [23]	25	Right	Abdominal pain, shock, vomit, acute peritonitis	18	Yes	GS	NA	Yes	LAT and PIOMTX and PTACE	Death	Multiple organ failure	No
2013 [18]	31	Right	No	10	Yes	GS	NA	Yes	LAT	Cure	Chickenpox	NA
2013 [1]	33	Right	Abdominal pain, right shoulder pain	5	Yes	A mixed echogenic mass	9.1 × 3.7	NA	LAT	Cure	NA	NA
2014 [24]	32	Right	Abdominal pain	8 weeks and 2 days	Yes	GS	3.3	Yes	LAT	Cure	NA	Yes
2015 [6]	20	Right	No	37	Yes	GS	NA	Yes	LAT	Live birth	No	Yes
2016 [25]	33	Right	Abdominal pain	8	NA	GS	NA	Yes	LAT	Cure	NA	NA
2017 [26]	31	Right	Abdominal pain	5 weeks and 5 days	Yes	S-GS	4.3	No	LAT	Cure	NA	NA
2017 [27]	21	Left	Vaginal bleeding	14	Yes	GS	NA	Yes	LAS	Cure	No	Yes
2017 [28]	24	Right	Abdominal pain	8 weeks and 5 days	Yes	A heterogeneous mass	4.2 × 3.8	No	Maternal intramuscular injection of MTX	Cure	No	No
2018 [29]	28	Right	Abdominal pain	4 weeks and 2 days	Yes	An uneven high echo mass	7.4 × 3.1	No	LAT	Cure	No	NA
2018 [30]	37	Right	Abdominal pain, vaginal bleeding, presyncope	9	Yes	A mixed echogenic mass	4.8 × 3.7	No	LAS		No	Yes
2016 [31]	31	Right	Abdominal distension	5 weeks and 5 days	Yes	S-GS	NA	No	LAT	Cure	No	No

GS, Gestational sac; S-GS, Similar to pregnancy sac, namely a hyperechoic ring with a cystic center; CL, Caudate lobe; KCL, potassium chloride; LAS, laparoscopic; LAT, laparotomy; NA, not available; PIOMTX, Postoperative injection of methotrexate; PTACE, postoperative transarterial chemoembolization.

4. Conclusions

In conclusion, for women of child-bearing age with elevated HCG levels, the possibility of hepatic pregnancy should be considered when ultrasonography shows a pregnancy sac, a hyperechoic ring or an inhomogenous mass within or on the liver and no pregnancy signs are identified in the uterine cavity or bilateral adnexal. Early diagnosis and appropriate treatment may prevent acute liver bleeding and other adverse outcomes. Ultrasonography is not only helpful for the early diagnosis of hepatic pregnancies, but also plays important roles in the follow-up of this condition, and sometimes it may facilitate treatment options other than surgery, including medical and expectant treatments.

Author contributions

XHL and JDC designed the research study. XHL and JKZ wrote the manuscript. JKZ edited the image. All authors contributed to editorial changes in the manuscript. All authors read and approved the final manuscript.

Ethics approval and consent to participate

This study was conducted in accordance with the Declaration of Helsinki, and the protocol was approved by the Ethics Committee of Jining Medical University Affiliated Hospital (2020C020). Informed consent for research and publication purposes was obtained from the patient mentioned in the study before collecting data.

Acknowledgment

We would like to express our gratitude to all those who helped during the writing of this manuscript. The authors also thank all the peer reviewers for their opinions and suggestion.

Funding

This study was supported by Department of Education of Shandong Province (J18KB128), and Science and Technology Bureau of Jining (2019SMNS032).

Conflict of interest

The authors declare no conflict of interest.

References

- [1] Kuai XP, Wang SY, Qiu JM. Ectopic pregnancy implanted in the liver under the diaphragm. *Taiwanese Journal of Obstetrics & Gynecology*. 2013; 52: 586–587.
- [2] Chui AK, Lo KW, Choi PC, Sung MC, Lau JW. Primary hepatic pregnancy. *ANZ Journal of Surgery*. 2001; 71: 260–261.
- [3] Chin PS, Wee HY, Chern BS. Laparoscopic management of primary hepatic pregnancy. *Australian and New Zealand Journal of Obstetrics and Gynaecology*. 2010; 50: 95–98.
- [4] Rohilla M, Joshi B, Jain V, Neetimala, Gainer S. Advanced abdominal pregnancy: a search for consensus. Review of literature along with case report. *Archives of Gynecology and Obstetrics*. 2018; 298: 1–8.
- [5] Borlum KG, Blom R. Primary hepatic pregnancy. *International Journal of Gynecology & Obstetrics*. 1988; 27: 427–429.
- [6] Brouard KJ, Howard BR, Dyer RA. Hepatic pregnancy suspected at term and successful delivery of a live neonate with placental attachment to the right lobe of the liver. *Obstetrics & Gynecology*. 2015; 126: 207–210.
- [7] Shippey SH, Bhoola SM, Royek AB, Long ME. Diagnosis and management of hepatic ectopic pregnancy. *Obstetrics & Gynecology*. 2007; 109: 544–546.
- [8] Harris GJ, Al-Jurf AS, Yuh WT, Abu-Yousef MM. Intrahepatic pregnancy, a unique opportunity for evaluation with sonography, computed tomography, and magnetic resonance imaging. *Journal of the American Medical Association*. 1989; 261: 902–904.
- [9] Veress B, Wallmänder T. Primary hepatic pregnancy. *Acta Obstetrica et Gynecologica Scandinavica*. 1987; 66: 563–564.
- [10] Kirby NG. Primary hepatic pregnancy. *British Medical Journal*. 1969; 1: 296.
- [11] Krause DW. Hepatic tumor or hepatic pregnancy. *American Journal of Roentgenology*. 1979; 133: 355–356.
- [12] Hietala SO, Andersson M, Emdin SO. Ectopic pregnancy in the liver: report of a case and angiographic findings. *Acta Orthopaedica Scandinavica*. 1983; 149: 633–635.
- [13] Murley AH. Liver pregnancy. *The Lancet*. 1956; 270: 994–995.
- [14] Mitchell RW, Teare AJ. Primary hepatic pregnancy: a case report and review. *South African Medical Journal*. 1984; 65: 220.
- [15] Paulino-Netto A, Roselli A. Hepatic ectopic pregnancy: successful surgical treatment of a patient with hepatic pregnancy and acute hemorrhage. *Mount Sinai Journal of Medicine*. 1986; 53: 514–517.
- [16] Shukla VK, Pandey S, Pandey LK, Roy SK, Vaidya MP. Primary hepatic pregnancy. *Postgraduate Medical Journal*. 1985; 61: 831–832.
- [17] Luwuliza-Kirunda JM. Primary hepatic pregnancy: case report. *BJOG: An International Journal of Obstetrics and Gynaecology*. 1978; 85: 311–313.
- [18] Qiao JC, Chang ZG, Wei JM, Liu YN, Cui HY, Zhang Y. Hepatic ectopic pregnancy treated successfully by hepatectomy. *Chinese Medical Journal*. 2013; 126: 4806–4807.
- [19] Nichols C, Koong D, Faulkner K, Thompson G. A hepatic ectopic pregnancy treated with direct methotrexate injection. *Australian and New Zealand Journal of Obstetrics and Gynaecology*. 1995; 35: 221–223.
- [20] Delabrousse E, Site O, Le Mouel A, Riethmüller D, Kastler B. Intrahepatic pregnancy: sonography and CT findings. *American Journal of Roentgenology*. 1999; 173: 1377–1378.
- [21] Ramphal SR, Moodley J, Rajaruthnam D. Hepatic pregnancy managed conservatively. *Tropical Doctor*. 2010; 40: 121–122.
- [22] Moores KL, Keriakos RH, Anumba DO, Connor ME, Lashen H. Management challenges of a live 12-week sub-hepatic intra-abdominal pregnancy. *BJOG: An International Journal of Obstetrics and Gynaecology*. 2010; 117: 365–368.
- [23] Yadav R, Raghunandan C, Agarwal S, Dhingra S, Chowdhary S. Primary hepatic pregnancy. *Journal of Emergencies, Trauma and Shock*. 2012; 5: 367–369.
- [24] Hu S, Song Q, Chen K, Chen Y. Contrast-enhanced multiphasic CT and MRI of primary hepatic pregnancy: a case report and literature review. *Abdominal Imaging*. 2014; 39: 731–735.
- [25] Tu J, Wang E, Shen J. Primary hepatic ectopic pregnancy: a case report. *Journal of Reproductive Medicine for the Obstetrician and Gynecologist*. 2016; 61: 175–178.
- [26] Wang T, Chen P, Bian D. Primary hepatic pregnancy. *Clinics and Research in Hepatology and Gastroenterology*. 2017; 41: 241–242.
- [27] Zhao RF, Huang SR, Xu LL, Liu NP, Liang N. Successful management of a live 14-week primary hepatic ectopic pregnancy combined with a residual horn of the uterus using laparoscopy. *Chinese Medical Journal*. 2017; 130: 3013–3014.
- [28] Sibetcheu Tchato A, Tchounzou R, Mbuagbaw L, Mboudou ET. Successful medical treatment of a hepatic pregnancy: a case report. *Journal of Medical Case Reports*. 2017; 11: 70.
- [29] Yin H, Liu Y, Cao Y, Zhang M, Wang T, Wang Z, et al. Primary hepatic pregnancy. *Monthly Journal of the Association of Physicians*. 2018; 111: 411–423.
- [30] Garzon S, Raffaelli R, Montin U, Ghezzi F. Primary hepatic pregnancy: report of a case treated with laparoscopic approach and review of the literature. *Fertility and Sterility*. 2018; 110: 925–931.
- [31] Guo B, Li D. Hepatobiliary and pancreatic: ectopic pregnancy in the liver: another rare cause of space occupying lesion. *Journal of Gastroenterology and Hepatology*. 2016; 31: 1514.
- [32] Wang C, Cheng L, Zhang Z, Yuan Z. Imaging diagnosis of hepatic ectopic pregnancy: a report of one case. *Intractable and Rare Diseases Research*. 2012; 1: 40–44.
- [33] Ma J, Zhou C, Duan Z, Jiang Y. Successful management of primary hepatic pregnancy with selective hepatic artery embolization and intra-arterial methotrexate infusion. *International Journal of Gynecology and Obstetrics*. 2013; 122: 78–79.
- [34] Barbosa Júnior Ade A, de Freitas LA, Mota MA. Primary pregnancy in the liver: a case report. *Pathology Research and Practice*. 1991; 187: 329–331.