

Short Communication

Fetal Autopsy: Improving Clinicians' Knowledge to Increase Parents' Acceptance. A Prospective Questionnaire-Based Study

Laura Avagliano^{1,*}, Elisa Martini², Monica Antuono², Gaetano Bulfamante^{3,4}¹Egeria Medical Center, 20122 Milano, Italy²Department of Clinical Sciences and Community Health, University of Milan, 20122 Milano, Italy³Department of Health Sciences, University of Milan, 20124 Milano, Italy⁴Toma Advanced Biomedical Assays S.p.A., 21052 Busto Arsizio, Varese, Italy*Correspondence: laura.avagliano@unimi.it (Laura Avagliano)

Academic Editor: Michael H. Dahan

Submitted: 7 July 2022 Revised: 25 July 2022 Accepted: 3 August 2022 Published: 9 November 2022

Abstract

Background: Knowing the cause of stillbirth is of paramount importance for bereaved parents and fetal autopsy is one of the key investigations aimed at providing explanation about the fetal death. However, parents often manifest concerns in autopsy acceptance. Barriers against fetal autopsy can be related to caregivers' disinformation and misconceptions. Our aim was to investigate the knowledge about fetal autopsy in a third level Italian University care Center. **Methods:** We investigated the knowledge of caregivers (n = 60) about fetal autopsy collecting data from an on-line anonymous questionnaire. We investigated about dismemberment, disfigurement and whether the parents can see their baby after the autopsy. **Results:** We obtained 34/60 (56.7%) answers, highlighting the discomfort of health care providers about addressing this issue. Only half of the responders knows that the baby will not be dismembered during the autopsy and only one third of caregivers knows that the baby will not be disfigured after the autopsy and parents can see their baby after the post-mortem investigation if they wish. More than 30% of health care providers reported that they did not know technical details about the autopsy procedures, and they did not know answers to some common questions about autopsy such as whether the fetus would be disfigured or dismembers and whether the remains could be viewed following completion of the autopsy. **Conclusions:** To overcome some barriers about fetal autopsy, it is of paramount importance that both caregivers and parents are aware that the baby will not be dismembered, and the face, hands, feet, and limbs of the baby are untouched during the full autopsy investigation. Deleting caregivers' misconceptions is a crucial point for improving parents' autopsy acceptance.

Keywords: autopsy; post-mortem examination; stillbirth

1. Introduction

Stillbirth is a devastating event that affects more than 2.5 million babies worldwide every year [1] and knowing its cause is of paramount importance for bereaved parents [2]. Caregivers should assure grieving parents that everything possible will be performed for understanding the cause of the fetal death [3]. One of the key investigations after stillbirth is fetal autopsy. Autopsy is strongly recommended worldwide [3–5] and the Royal College of Pathologists [6] and the American College of Obstetricians and Gynecologists [4] suggests that it should be included in all cases of stillbirth as it represents one of the most useful diagnostic tests in determining the cause of fetal death [4,6]. Accordingly, as highlighted by the Clinical Practice Guideline for Care Around Stillbirth and Neonatal Death provided by the Perinatal Society of Australia and New Zealand [3], there is strong evidence about the effectiveness of fetal autopsy: it is useful for revealing the cause of death in a significant proportion of cases otherwise reported as “unexplained” [7–9]. Autopsy results are also able to provide significant additional information [8], useful in the understanding the events surrounding the death, aiming at identifying disor-

ders important for subsequent pregnancies [3]. Moreover, autopsy can exclude some potential cause of death [3] and can reveal changes in diagnosis [7]. Indeed, autopsy results are important to help the bereaved parents in the process of understanding the real cause of death and the underlying pathologies that contributed to the fetal demise. Results of fetal autopsy, therefore, are useful for alleviating the parents' guilt feelings [3].

While autopsy is the gold standard for understanding the cause of stillbirth, parents often manifest discomfort and concerns in its acceptance; parents feel shocked, distressed, unprepared and overwhelmed by their grief [10,11]. Therefore, they may be not able to provide their consent for fetal examination. For this reason, only 30–40% of parents provide their consent to this examination [12]. Moreover, the trend of agreeing to the fetal post-mortem examination is dangerously decreasing, as highlighted by Auger *et al.* [13]. For example, autopsy rates declined by 29% in Canada from 1981 to 2015, with an irremediable missed opportunities of determining the cause of death.

Caregivers need to be prepared for the difficulty of speaking about autopsy with parents [10]. Parents feel



afraid and distressed about the procedure [11] and they have wrong concerns about disfigurement and dismemberment [10,11,14]. Unfortunately, this barrier against fetal autopsy is sometimes related to caregivers' disinformation and misconceptions. Commonly, in a real-life clinical setting, a great number of caregivers in Italy think that the baby will be disfigured after post-mortem examination. Therefore, our aim was to investigate the knowledge about fetal autopsy in a third level, Italian University Care Center.

2. Methods

We investigated the caregivers' knowledge about fetal autopsy collecting data from an on-line anonymous questionnaire administered to the entire staff ($n = 60$) of the Obstetrics Unit of a third level, University Center in Northern Italy. The Unit can provide antenatal, intrapartum and post-partum care to low risk, moderate risk and high-risk pregnancies, with Ob-Gyn, Anesthesiologist and Neonatologist physically present at all times and full complements of subspecialists readily available at all times for inpatients consultation; in-house availability of all of blood components; onsite availability of maternal intensive care unit and neonatal intensive care unit.

The survey consisted of questions across several key areas including: (1) Sociodemographic information, (2) Knowledge about international stillbirth guidelines, (3) Knowledge about fetal autopsy. The present manuscript focused on the results obtained about the knowledge about fetal autopsy. The Carlo Poma Hospital of Mantova approved the protocol and authorized the study. All data were collected and analyzed anonymously.

We investigated about dismemberment, disfigurement and whether the parents can see their baby after the autopsy.

The definition of dismemberment was "cutting and entire removal of a large section of the body, including disconnection of the limbs and or the head".

The definition of disfigurement was "irreparable mutilation of the face of the baby with visible, devastating cutting and tearing".

3. Results

We obtained 34/60 (56.7%) answers, suggesting the discomfort of Italian health care providers about addressing this issue. However, our response rate of half of caregivers was not poor and is not significantly lower than other anonymous studies about stillbirth, for example the response rate obtained in an UK survey was one-third of professionals [15]. About the responders, 32 were females and two were males; the mean age was 40.5 years, standard deviation (SD) 10.0; the mean working years was 14.4 (SD 10.5). Responders were also asked to quantify their experience about stillbirth during their professional career: 25% of the midwives and 27.3% of the obstetricians affirmed to have assisted more than 10 cases of stillbirths, whereas 43.7% of the midwives and 63.6% of the obstetricians af-

firmed to have assisted less than five stillbirths.

Unfortunately, only half of the responders knew that the baby will not be dismembered and only one third of caregivers knew that the baby will not be disfigured after the autopsy and parents can see their baby after the post-mortem investigation (Fig. 1). We did not observed differences in the knowledge between midwives and medical doctors.

More than 30% of health care providers reported that they did not know technical details about the autopsy procedures, and they did not know answers to some common questions about autopsy such as whether the fetus would be disfigured or dismembers and whether the remains could be viewed following completion of the autopsy.

4. Discussion

Our survey demonstrates the presence of poor knowledge and common misunderstandings within caregivers regarding fetal autopsy. Importantly, caregivers should be mindful that the decision to perform the autopsy does not impede the opportunity to give parents time to spend with their baby. The autopsy is not an emergency intervention; therefore, it is of paramount importance giving parents the time to stay, see, hold and grieve their baby, taking photograph and tangible mementos if they wish.

First of all, full autopsy includes the combination of more factors: a review of history of the pregnancy, results of antenatal investigations, maternal clinical investigations after stillbirth, placental macroscopic and histological examination, and external and internal examination of the baby [3]. The combination of all these factors allows to provide a useful autopsy report, containing clinicopathological information that can help identifying the underlying causes of the death. As suggested by the "Guidelines on autopsy practice - third trimester antepartum and intrapartum stillbirth" provided by Royal College of Pathologists [6], the external examination of the baby includes a detailed inspection of the aspect of the baby with the aim of evaluating: the presence of maceration, the presence of local/generalized edema, the color of the skin and mucosae (evaluating for example redness or pallor or petechiae), the nutritional status and muscle bulk, the presence of dysmorphic features. The evaluation also includes detailed fetal measurements (i.e., body weight, crown-rump length, crown-heel length, foot length, occipito-frontal circumference, abdominal circumference) and clinical photographs. The internal examination of the baby includes a longitudinal Y-shaped surgical skin incision from the top of the chest to the lower abdomen, performed to permit the internal organ examination, dissection, and then a detailed histological evaluation.

Recently, the possibility of minimally invasive post-mortem examinations has been suggested as an opportunity of investigation, aimed at determining the cause of fetal death if a full post-mortem is not accepted [3]. Some

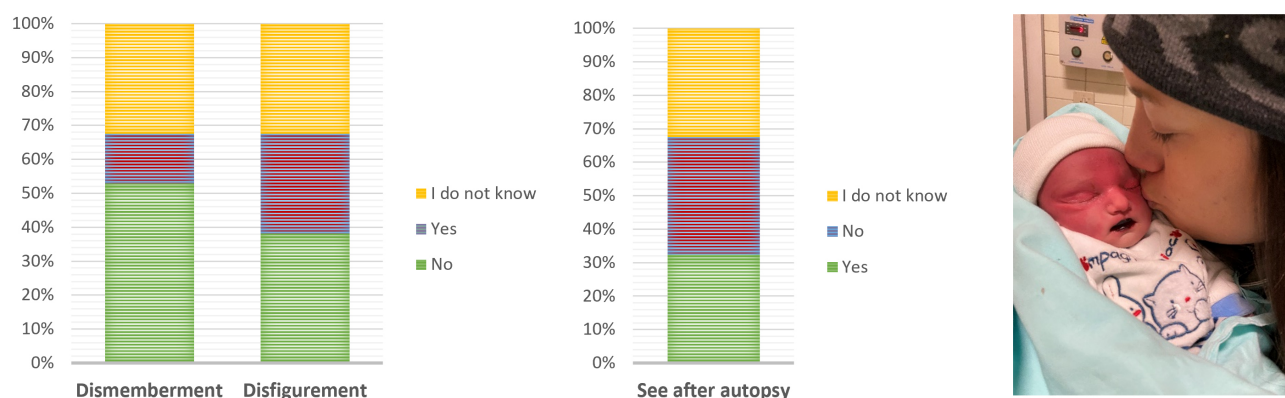


Fig. 1. Results of investigation about stillbirth in a third level University Center in Northern Italy. Bars show the percentage of the answers provided by caregivers. In green the right response. Questions are about fetal appearance after autopsy (dismemberment and disfigurement) and whether the parents can see their baby after investigations (as showed in the photo on the right).

Authors also provided protocols for post-mortem imaging (including post-mortem ultrasound, radiographs, computerized tomography, magnetic resonance) that can be used when the proposal of the autptic post-mortem examination is declined [16]. However, parents should be informed about the risk of missing important findings when a full autopsy is not performed [3].

To overcome some barriers about fetal autopsy, it is of paramount importance that both caregivers and parents are aware that the face, hands, feet, and limbs of the baby are untouched during the full autopsy investigation. At the end of the procedures all the body incisions are sutured and are not visible once the baby is dressed.

Deleting caregivers' misconceptions is a crucial point for improving parents' acceptance. The Clinical Practice Guideline for Care Around Stillbirth and Neonatal Death provided by the Perinatal Society of Australia and New Zealand [3] suggests organizing formal and informal educational for clinicians about the procedures of post-mortem examination and the high value and potential benefits of the fetal autopsy. Moreover, clinicians should be trained on compassionate counselling about fetal post-mortem investigation and obtaining parental consent. Indeed, the Clinical Practice Guideline for Care Around Stillbirth and Neonatal Death provided by the Perinatal Society of Australia and New Zealand [3], highlighted that the discussion about post-mortem examination should involve a trusted and knowledgeable caregiver [17]. Caregivers should be mindful that their mode of approach and communication will influence parents' decision about investigations. Parents should be assured that their baby will be treated always with respect and dignity [3]. Ambivalent, insensitive, non-supportive mode of providing information represents a common barrier to obtain autopsy consent [17].

Caregivers should also knowledge the location of the baby during and after the autopsy procedure, and they should provide this information to parents: caregivers

should be mindful that for parents it is important to know where the baby is [3]; caregivers should address the opportunity for parents to accompany the baby to the mortuary if they wish it [3]. Caregivers should also ensure grieving parents that they can see the baby following the examination if they wish. Moreover, caregivers should assure the parents that fetal autopsy does not impede the opportunity of rituals: the parents can organize burial and funeral arrangements afterwards if they wish.

One critical point of fetal autopsy is the timeframe between the examination and the results. Caregivers should inform parents that the final result may not be available for several weeks (sometimes several months). Health care providers should be mindful that a lengthy wait can increase the emotional distress of the parents [15]. To keep in contact with parents, providing them information about the progress of the report is a useful strategy to help to reduce anxiety [3].

It is important for caregivers to note that parents who choose not to have fetal autopsy may experience later regret [15,18] due to the lack of knowledge about the cause of death. Moreover, caregivers should always keep in mind that the results of autopsy can guide appropriate management strategies in future pregnancies and guide counseling for preventing recurrence [3,5]. For these reasons, caregivers should improve their knowledge about autopsy procedures, and the usefulness of autopsy results.

Finally, the medical literature highlights that some parents who agreed to an autopsy, later reported dissatisfaction with the way the autopsy results were given to them [10]. It is of paramount importance that caregivers make an appointment to discuss the results in a sensitive manner, without the use of medical terminology, allowing parents to formulate all their questions and express their concerns [3].

In our clinical practice we often facing with the difficulties of speaking about fetal autopsy with bereaved parents. Institutional formal education has improved our abil-

ity about providing honest but compassionate information. In our opinion, one useful strategy for improving the skills of caregivers is collecting parents' feedbacks. Here we provide an example of feedback that we recently received from a mother. We obtained her consent to share her words:

"Everything before that day was great, my baby boy was fine... Then, one day I woke up and I could not feel him moving. ... I could not believe that I was experiencing a stillbirth...."

After giving birth, I had the chance to spend some time with my baby, hold him, and take some pictures. I will always be grateful for those moments I spend with him.

For me it was fundamental having on my side Doctors that helped me to find the real reason for the death of my baby. I will always be grateful for it. This supported me during my next pregnancy, that was a roller-coaster of emotions... Now after 2 years and another baby in my arms, what I would recommend to parents that experience a stillbirth is to take time; a wound like this will never truly heal, but one day you will be able to breathe again, laugh again not feeling guilty. You are not alone! I asked for help and met other mums like me, and this gave a new strength and a new awareness. Out there is full of parents like us ready to share their experience and give hope. The pain will remain but some days it will be easier to deal with it".

In conclusion, for overcoming the misconception around fetal autopsy and allowing for better diagnosis and clinical management, it would be useful to plan a multidisciplinary approach based on open dialogue which could contribute to empowerment of parents. We strongly agree with the suggestion provided by the Clinical Practice Guideline for Care Around Stillbirth and Neonatal Death provided by the Perinatal Society of Australia and New Zealand [3], that states that "clinicians should cooperate with pathologists and parent-based organizations to promote public awareness of the value of fetal autopsy".

Author Contributions

Conception and design of the article by LA. LA performed the literature search, drafted the manuscript, collected, and analyzed data. EM and MA collected data and drafted the manuscript. GB actively discussed results, expanded literature search and drafted the manuscript. All authors read, edited, and approved the final version of manuscript.

Ethics Approval and Consent to Participate

ASST Mantova; date of approval July 2nd, 2020, number 0031776. All subjects gave their informed consent for inclusion before they participated in the study.

Acknowledgment

The authors are grateful to parents and clinicians for their support and inspiration.

Funding

This research received no external funding.

Conflict of Interest

The authors declare no conflict of interest. LA is serving as one of the Editorial Board members/Guest editors of this journal. We declare that LA had no involvement in the peer review of this article and has no access to information regarding its peer review. Full responsibility for the editorial process for this article was delegated to MHD.

References

- [1] Blencowe H, Cousens S, Jassir FB, Say L, Chou D, Mathers C, et al. National, regional, and worldwide estimates of stillbirth rates in 2015, with trends from 2000: a systematic analysis. *The Lancet Global Health*. 2016; 4: e98–e108.
- [2] Gold KJ. Navigating care after a baby dies: a systematic review of parent experiences with health providers. *Journal of Perinatology*. 2007; 27: 230–237.
- [3] Flenady V, Oats J, Gardener G, Masson V, McCowan L, Kent A, et al. Clinical Practice Guideline for Care Around Stillbirth and Neonatal Death. 2020. Available at: URL <https://starlegacyfoundation.org/wp-content/uploads/Flenady-2020-PSANZ-Clinical-Practice-Guideline-for-Stillbirth-and-Neonatal-Death.pdf> (Accessed: 29 June 2022).
- [4] ACOG Practice Guideline. Management of Stillbirth: Obstetric Care Consensus No. 10. *Obstetrics and Gynecology*. 2020; 135: e110–e132.
- [5] RCOG. Late Intrauterine Fetal Death and Stillbirth Green-top Guideline No. 55. October 2010. Available at: URL <https://www.rcog.org.uk/guidance/browse-all-guidance/green-top-guidelines/late-intrauterine-fetal-death-and-stillbirth-green-top-guideline-no-55/> (Accessed: 29 June 2022).
- [6] The Royal College of Pathologists. Guidelines on autopsy practice Third trimester antepartum and intrapartum stillbirth. 2017. Available at: <https://www.rcpath.org/uploads/assets/0e55a233-5fe6-4965-b85f4fa7c9971742/Guidelines-on-autopsy-practice-Third-trimester-antepartum-and-intrapartum-stillbirth.pdf> (Accessed: 29 June 2022).
- [7] Gordijn SJ, Erwich JJHM, Khong TY. Value of the Perinatal Autopsy: Critique. *Pediatric and Developmental Pathology*. 2002; 5: 480–488.
- [8] Pekkola M, Tikkanen M, Loukovaara M, Lohi J, Paavonen J, Stefanovic V. Postmortem examination protocol and systematic re-evaluation reduce the proportion of unexplained stillbirths. *Journal of Perinatal Medicine*. 2020; 48: 771–777.
- [9] Page JM, Christiansen-Lindquist L, Thorsten V, Parker CB, Reddy UM, Dudley DJ, et al. Diagnostic Tests for Evaluation of Stillbirth: results from the stillbirth collaborative research network. *Obstetrics & Gynecology*. 2017; 129: 699–706.
- [10] Horey D, Flenady V, Conway L, McLeod E, Yee Khong T. Decision influences and aftermath: parents, stillbirth and autopsy. *Health Expectations*. 2014; 17: 534–544.
- [11] Kilcullen M, Kandasamy Y, Watson D, Cadet-James Y. Decisions to consent for autopsy after stillbirth: Aboriginal and Torres Strait Islander women's experiences. *Australian and New Zealand Journal of Obstetrics and Gynaecology*. 2020; 60: 350–354.
- [12] Shelmerdine SC, Hutchinson JC, Arthurs OJ, Sebire NJ. Latest developments in post-mortem foetal imaging. *Prenatal Diagnosis*. 2020; 40: 28–37.
- [13] Auger N, Bilodeau-Bertrand M, Poissant J, Shah PS. Decreasing

use of autopsy for stillbirths and infant deaths: missed opportunity. *Journal of Perinatology*. 2018; 38: 1414–1419.

- [14] McHaffie HE, Fowle PW, Hume R, Laing IA, Lloyd DJ, Lyon AJ. Consent to autopsy for neonates. *Archives of Disease in Childhood - Fetal and Neonatal Edition*. 2001; 85: F4–F7.
- [15] Heazell A, McLaughlin M, Schmidt E, Cox P, Flenady V, Khong T, *et al.* A difficult conversation? The views and experiences of parents and professionals on the consent process for perinatal postmortem after stillbirth. *BJOG: An International Journal of Obstetrics & Gynaecology*. 2012; 119: 987–997.
- [16] Shelmerdine SC, Arthurs OJ. Post-mortem perinatal imaging: what is the evidence? *The British Journal of Radiology*. 2022; 20211078.
- [17] Lewis C, Hill M, Arthurs O, Hutchinson C, Chitty L, Sebire N. Factors affecting uptake of postmortem examination in the prenatal, perinatal and paediatric setting. *BJOG: An International Journal of Obstetrics & Gynaecology*. 2018; 125: 172–181.
- [18] Ellis A, Chebsey C, Storey C, Bradley S, Jackson S, Flenady V, *et al.* Systematic review to understand and improve care after stillbirth: a review of parents' and healthcare professionals' experiences. *BMC Pregnancy and Childbirth*. 2016; 16: 16.