

## ANCILLARY FISH ANALYSIS FOR 1p AND 19q STATUS: PRELIMINARY OBSERVATIONS IN 287 GLIOMAS AND OLIGODENDROGLIOMA MIMICS

Arie Perry<sup>1</sup>, Christine E. Fuller<sup>1</sup>, Ruma Banerjee<sup>1</sup>, Daniel J. Brat<sup>2</sup>, Bernd W. Scheithauer<sup>3</sup>

<sup>1</sup> Divisions of Neuropathology, Washington University School of Medicine, St. Louis, MO, <sup>2</sup> Emory Univ. Hospital, Atlanta, GA, and <sup>3</sup> Mayo Clinic, Rochester, MN

### TABLE OF CONTENTS

1. Abstract
2. Introduction
3. Materials and Methods
  - 3.1. Patient and tumor cohort
  - 3.2. Fluorescence in situ hybridization (FISH)
4. Results and Discussion
  - 4.1. Technical considerations and 1p/19q FISH patterns in diffuse gliomas
  - 4.2. "Oligodendroglioma mimics" and specificity of deletions
  - 4.3. Clinical followup and associations with survival time
  - 4.4. Other potentially useful genetic markers
5. Summary
6. Acknowledgements
7. References

### 1. ABSTRACT

Deletions of chromosomes 1p and 19q are associated with chemosensitivity and enhanced survival in oligodendrogliomas. Therefore, we have utilized FISH analysis as an ancillary tool for diffuse gliomas with suspected oligodendroglial features. To date, 246 gliomas have been analyzed in 131 male and 93 female patients, including 109 oligodendrogliomas (O), 109 mixed oligoastrocytomas / equivocal gliomas (MOA), and 28 astrocytomas (A). To address specificity, we also analyzed 41 oligodendroglioma mimics, including 12 central and 12 extraventricular neurocytomas (EVN), 12 dysembryoplastic neuroepithelial tumors, and 5 clear cell ependymomas. Aside from 2 EVNs, no mimics demonstrated codeletion. Three patterns were associated with glioma cell type (O vs. MOA/A): -1p/19q, -19q alone, and polysomies. Long-term survivals of >5-years (N=47) and >10-years (N=16) were associated with 1p/19q codeletion in 60% and 75% respectively, whereas solitary 19q deletion accounted for 11% and 6% respectively. Survivals <2-years (N=10) were associated with lack of deletions in 70%. A few older patients with high-grade, "genetically favorable" tumors did poorly, whereas prolonged survival was observed in several low-grade glioma patients despite a lack of the "genetically favorable" pattern. Our data suggests that: 1) FISH-detectable 1p/19q codeletion is relatively specific for oligodendrogliomas with long survival, 2) solitary 19q deletion may also portend a favorable prognosis in a smaller subset, and 3) combined clinicopathologic and genetic assessment likely provides a more accurate means of patient stratification than either one alone.

### 2. INTRODUCTION

Despite early pessimism, encouraging progress has been made over the last 15 years regarding the classification, genetic characterization, and therapy of

diffusely infiltrating gliomas (1-3). For example, it was observed that tumors with well-developed oligodendroglial features were associated with both prolonged survival and response to "PCV" chemotherapy (procarbazine, CCNU, vincristine), even when high-grade or poorly differentiated (4-7). At about the same time, neuropathologists came to recognize that the histologic spectrum of oligodendroglioma was wider than originally appreciated and could include glial fibrillary acidic protein (GFAP)-expressing minigemistocytes and gliofibrillary oligodendrocytes, cell types once thought to indicate astrocytic differentiation (3, 8-10). Based on revised morphologic definitions and an increased awareness of their clinical implications, oligodendrogliomas have been transformed from a once rare tumor (5% of gliomas) to a commonly encountered one (25-33% of gliomas) (11-13). Unfortunately, the classification scheme remains somewhat subjective, with significant histopathologic overlap among glial neoplasms. Thus, considerable differences of opinion remain among neuropathologists, regarding what constitutes minimal criteria for an oligodendroglioma designation (3). This has led to considerable interobserver variability in glioma diagnosis (3, 11, 14, 15). Although a reliable oligodendroglioma-specific marker has yet to be identified, genetic studies have shown that 50-80% of oligodendrogliomas harbor deletions, typically involving the entire chromosome 1p and 19q arms (1-3, 16-19). Of even greater importance were recent findings that this "genetically favorable" subset of oligodendrogliomas is the group most strongly associated with enhanced survival and therapeutic sensitivity to both PCV chemotherapy and radiation therapy (1-3, 20-22).

Over the past 4 years, as part of our molecular diagnostics research and development program at Washington University School of Medicine, we have been

assessing 1p and 19q status by fluorescence *in situ* hybridization (FISH) for all in-house and consultation brain tumor biopsies demonstrating clear or suspected oligodendroglial features. The FISH technique was chosen due to its relative simplicity, lack of requirement for matching non-neoplastic cells or tissue, low cost, applicability to formalin-fixed paraffin-embedded tissue, morphologic preservation, and rapid turnaround time (23). The current study summarizes our experience to date with 246 diffuse gliomas and 41 oligodendroglioma mimics. Although clinical followup is currently limited, most cases having been studied prospectively, several interesting associations have already been found. Preliminary clinicopathologic observations and practical aspects of 1p/19q ancillary testing are emphasized.

### 3. MATERIALS AND METHODS

#### 3.1. Patient and tumor cohort

Between September 1998 and May 2002, 246 diffusely infiltrative gliomas from 131 male and 93 female patients ranging in age from 3 to 76 (median, 40 years) were prospectively and retrospectively studied at Washington University School of Medicine. Inclusion of cases required the presence of a clear or suspected oligodendroglial component, as indicated by either an in-house or referring pathologist. They consisted of 193 (78%) primary, 53 (22%) recurrent, 94 (38%) in-house, and 152 (62%) outside biopsies. The latter consisted of both neuropathology consultation cases and unsolicited pathology reviews for patients seeking additional medical care or second opinions at the Washington University Medical Center. Although the majority of cases were studied prospectively, several archival cases were retrospectively studied upon clinical and/or radiographic evidence of tumor recurrence or progression. Final diagnoses were rendered using World Health Organization (WHO) criteria (1). However, glioblastomas (GBMs) with oligodendroglial components were referred to as “grade IV mixed oligoastrocytomas” and high-grade oligodendrogliomas with pseudopalisading necrosis were referred to as “grade IV oligodendrogliomas”. Morphologically ambiguous gliomas and mixed oligoastrocytomas (MOA) were more common in the consultation material and these challenging cases were typically shown to all 3 staff neuropathologists at Washington University before the official diagnosis was rendered. None of the previously reported gliomas from the Mayo Clinic (19, 21) were included in this study and none of the current Washington University cases have been previously published.

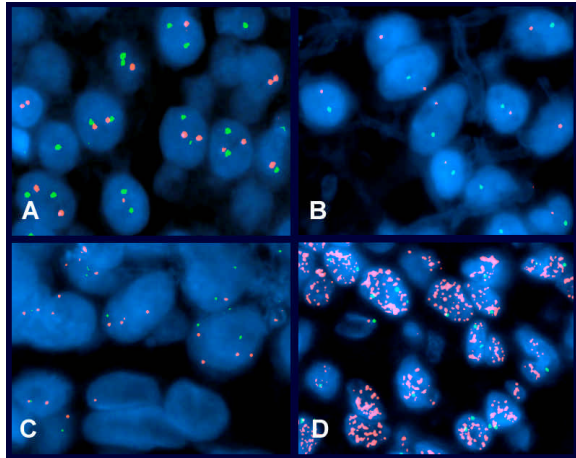
In order to further assess specificity for our genetic markers, we also evaluated 41 recently encountered oligodendroglioma mimics from the pathology files of Washington University, Mayo Clinic, and Emory University. These consisted of 12 central neurocytomas (CN), 12 extraventricular neurocytomas (EVN), 12 dysembryoplastic neuroepithelial tumors (DNT), and 5 clear cell ependymomas (CCE).

#### 3.2. Fluorescence *in situ* hybridization (FISH)

Dual-color fluorescence *in situ* hybridization (FISH) was performed on 5- $\mu$ -thick paraffin sections as previously published (23, 24). In the few instances wherein archival blocks or unstained sections could not be found, negative immunostain control slides were destained and utilized for FISH analysis. Paired DNA probes consisted of a FITC-labeled chromosome 1p32 probe (Human BAC RPCI-11 library clone 260I23, Research Genetics, Huntsville, AL) and one of two rhodamine-labeled chromosome 19q13.4 probes (19q-telomere probe initially, Vysis, Downers Grove, IL; RPCI-11 BAC clone 426G3 in later part of study, Research Genetics). The 1p32 probe was originally developed for our meningioma studies (24), but was felt to be useful for glioma testing as well, given its high hybridization efficiency in paraffin sections and the fact that 1p deletions in classic oligodendrogliomas nearly always involve the entire arm. The Vysis 19q-telomere probe was originally chosen due to its commercial availability. However, the relatively high cost and lower hybridization efficiency of this probe eventually led us to replace it with the BAC clone listed above. Neither the 1p nor the 19q probes were specifically selected from the “regions of minimal deletion”, since the majority of the rare gliomas defining such regions have actually been astrocytomas. In other words, we sought maximal specificity for the typical “oligodendroglioma pattern” with combined 1p/19q whole arm deletions, rather than maximal sensitivity for small interstitial deletions. Nevertheless, it is likely that virtually any probe on 1p or 19q would have given similar results overall, since the entire chromosomal arms are lost in the majority of cases.

Deparaffinization was achieved with Hemo-D (Sigma; St. Louis, MO), followed by three washes in isopropanol, a wash in running tap water and another in distilled water. DNA target retrieval was carried out in a steam cooker with 10-mM citrate buffer, pH 6.0. Sections were subjected to 30 minutes of pepsin digestion at 37° C. Paired 1p and 19q probes were diluted to 1:50 in DenHyb buffer (Insitus; Albuquerque, NM), applied to each slide and co-denatured with the target DNA at 90° C for 13 minutes. The slides were incubated overnight at 37° C in a humidified oven and subsequently washed for five minutes each with 50% formamide/1X SSC and two washes in 2X SSC.

Green and red fluorescent signals were enumerated under an Olympus BX60 fluorescence microscope with appropriate filters (Olympus; Melville, NY). For each hybridization, a minimum of 100 non-overlapping nuclei were assessed for numbers of green and red signals. An interpretation of deletion was made when >50% of the nuclei harbored only one red or one green signal. This was based on the frequencies of non-neoplastic nuclei containing one signal for the same probes in seizure-resection specimens (median + 3 standard deviations). Hybridizations where the FISH signals were either lacking or too weak to be interpreted were repeated using higher probe concentrations (e.g. 1:20). Those still uninterpretable were considered “noninformative”. In order to rule out the possibility of relative 1p deletions (e.g. 2 copies of 1p in association with tetrasomy 1), negative



**Figure 1.** Representative FISH hybridizations. A) Central neurocytoma with a normal disomic complement of 1p (green) and 19q (red) signals. Most cells have 2 green and/or 2 red signals, though some have less due to the truncation artifact encountered in thin tissue sections (i.e. incomplete DNA complement in sectioned nuclei). Also, some signals are beyond the planes of focus represented in the photograph. B) Pattern of 1p/19q codeletion in an oligodendroglioma with 1 green and 1 red signal detected in most nuclei. C) Recurrent anaplastic oligodendroglioma with a relative 1p deletion as evidenced by the presence of up to 4 chromosome 1q (red) and 2 1p (green) signals in tumor nuclei. D) Small cell GBM containing overlapping morphologic features with anaplastic oligodendroglioma. It displayed *EGFR* gene amplification with innumerable *EGFR* signals (red), rather than 1p/19q deletions. A chromosome 7 centromere-enumerating probe (CEP7, green) was utilized as the reference probe for delineating copy numbers of chromosome 7.

cases were later reevaluated by pairing the 1p32 probe with a 1q42 reference probe. Polysomies or gains were arbitrarily set at 5% nuclei with >2 signals, given that such cells are rarely ever seen in non-neoplastic brain specimens.

Images were captured using a black and white, high resolution COHU CCD camera, Z-stack motor and CytoVision™ basic workstation (Applied Imaging, Santa Clara, CA), with sequential DAPI (1 level), FITC (5 levels), and rhodamine (5 levels) filter settings. The resulting images were reconstituted with blue, green, and red pseudocolors using CytoVision™ software.

Associations between FISH patterns and histologic subtype or grade were determined using chi-square tests. P-values of <0.05 were considered statistically significant.

## 4. RESULTS AND DISCUSSION

### 4.1. Technical considerations and 1p/19q FISH patterns in diffuse gliomas

In our lab, FISH was primarily chosen over loss of heterozygosity (LOH) for determination of 1p/19q status

due to the first author's familiarity and expertise with the technique, its morphologic basis, and its applicability to formalin-fixed paraffin-embedded tissue. Given the infiltrative nature of gliomas, it also has the advantage that deletions can be detected in clonal populations comprising as little as 20-30% of the specimen, as compared to requirements of 70-80% purity for LOH studies. Furthermore, the retained morphologic architecture allows the interpreter to focus on the most cellular tumor-associated regions, thus enhancing the likelihood of analyzing the appropriate cells, even in small biopsies from low-grade gliomas where non-neoplastic elements may constitute a relatively high proportion of the specimen's cellularity. Lastly, FISH lacks the requirements of LOH for non-neoplastic DNA from blood leukocytes or microdissected tissue and is therefore applicable to a greater number of glioma specimens, including those that are composed primarily of tumor with no available matching blood specimen collected. Alternatively, LOH is easier to interpret than FISH in tumors with complex ploidy alterations and numerous microsatellite markers can be applied simultaneously to each specimen, allowing for detection of small deletions. Also, it can detect losses associated with mitotic recombination or deletion followed by reduplication, wherein one allele is lost (e.g. wild type) and the other is duplicated (e.g. mutant form). Fortunately, this does not appear to be a significant mechanism with 1p and 19q losses in oligodendrogliomas and the concordance rates between FISH and LOH have been excellent (19).

In the current study, FISH hybridizations were interpretable for 1p and 19q in 243 (98.8%) and 231 (93.9%) cases respectively. The commercial Vysis 19q-telomere probe initially utilized was typically weaker than the paired 1p probe and accounted for most of the noninformative 19q hybridizations. Thus, a 19q13.4 BAC probe with improved hybridization efficiency was subsequently developed in our lab and was employed in the more recent cases. On metaphase preparations, this substitute probe co-localized with the Vysis probe near the 19q-telomere. Therefore, the data obtained with either probe was felt to be analogous.

Four basic patterns were identified using FISH analysis: 1p/19q codeletion, 19q deletion alone, polysomies (i.e. gains) of 1p and/or 19q, and normal (i.e. 2 copies of each) (Figure 1). The associations between these patterns and clinicopathologic features are summarized in Tables 1-3. The 1p/19q codeletion pattern was highly associated with oligodendroglial morphology ( $p < 0.001$ ). In the majority of positive cases, nearly all neoplastic nuclei demonstrated 1 green and 1 red signal (Figure 1B), suggesting that this alteration was acquired early in tumor development, being a "primary tumorigenic event". The detection of this pattern in 70% of oligodendrogliomas compares well with the 50-80% figures previously reported with LOH and FISH studies (16-19). On re-review, the 30% of oligodendrogliomas without this molecular signature tended to show slightly more nuclear irregularities and pleomorphism compared with those having deletions. Nonetheless, there was considerable morphologic overlap between the two groups. Only 17%

## 1p/19q FISH testing in gliomas

**Table 1.** FISH Patterns vs. Glioma Type

Cell Type	1p/19q Deleted	-19q only	Polysomies	Normal
O (N=109)	70%	2%	16%	16%
MOA (N=109)	17%	21%	47%	23%
A (N=28)	4%	8%	53%	33%
P-value*	<0.001	<0.001	<0.001	0.132

O = oligodendroglioma, MOA = mixed oligoastrocytoma, A = astrocytoma, \*P-value is for O versus MOA and A.

**Table 2.** FISH Patterns vs. Histologic Grade

Grade	1p/19q Deleted	-19q only	Polysomies	Normal
II (N=89)	34%	8%	31%	27%
III (N=124)	48%	9%	32%	15%
IV (N=33)	18%	24%	42%	24%
P-value*	0.015	0.029	0.285	0.786

\*P-value is for grades II and III vs. IV

**Table 3.** FISH Patterns vs. Tumor Location

Location	1p/19q Deleted	-19q only	Polysomies	Normal
Frontal (N=115)	50%	7%	31%	15%
Temporal (N=48)	25%	8%	46%	35%
Parietal (N=22)	32%	23%	32%	23%
Occipital (N=5)	60%	0	0	40%
Thalamus (N=5)	0	0	40%	60%
Other* (N=21)	29%	10%	19%	43%
P-value <sup>1,2,3</sup>	0.001 <sup>1</sup>	0.042 <sup>2</sup>	0.046 <sup>3</sup>	0.002 <sup>1</sup>

\*Other = multiple lobes or cerebral hemisphere, not otherwise specified; P-value<sup>1</sup> = frontal lobe vs. all other locations, P-value<sup>2</sup> = parietal lobe vs. all other locations, P-value<sup>3</sup> = temporal lobe vs. all other locations

of mixed oligoastrocytomas had the codeletion pattern. These tumors tended to be among those displaying the most convincing oligodendroglial morphology (data not shown). Therefore, this assay was only occasionally helpful in supporting oligodendroglial differentiation when applied to diagnostically challenging tumors, such as those with ambiguous cytologic features.

The associations of 1p/19q FISH patterns with tumor grade (Table 2) were not as impressive as those with cell type (Table 1). However, there were fewer 1p/19q codeletions and more solitary 19q deletions in the grade IV tumors and these differences were statistically significant. The former likely reflects the fact that most of our grade IV tumors were astrocytomas and the latter is consistent with the notion that 19q deletions are associated with tumor progression in a subset of gliomas (19, 25). Nevertheless, this pattern was not limited to our high-grade tumors and was most commonly encountered in mixed oligoastrocytomas. Despite its potential association with tumor progression, some of these patients did surprisingly well (see clinical followup section below).

Associations between FISH patterns and tumor location are summarized in Table 3. For the 216 patients where the site of primary tumor resection was listed, frontal lobe accounted for 53% of the cases and represented the region with the highest frequency of combined 1p/19q deletions (50%;  $p=0.001$ ) and the lowest frequency of a normal FISH pattern (15%;  $p=0.002$ ). In contrast, the parietal lobe harbored the greatest fraction of tumors with solitary 19q deletion (23%;  $p=0.042$ ) and polysomies were seen most often in the temporal lobe gliomas (46%;  $p=0.046$ ). Although there were only 5 thalamic tumors, none showed any deletions. These associations with tumor site were not simply due to variable diagnoses according to site, since there were no statistical associations between histopathologic diagnosis and tumor location (data not shown). For example, pure oligodendroglioma accounted for roughly half the tumors in both frontal and temporal lobes. However, 1p/19q codeletion was encountered twice as often in the former site. The reason for these site-specific patterns is not clear, though Zlatescu *et al.* similarly found that LOH for 1p and 19q was significantly less common in oligodendrogliomas arising from the temporal lobe, insula, and diencephalon (26).

Not surprisingly, polysomies were encountered most often in astrocytic and higher-grade gliomas. This pattern is often a reflection of aneuploidy/polyploidy resulting from genomic instability and/or endoreduplication (i.e. DNA replication without cellular division). It was also encountered in occasional low-grade tumors (WHO grade II), particularly mixed oligoastrocytomas. More than likely, the frequency of tumors containing polyploid cells was underestimated in our study, since only 2 chromosomal sites were probed. In most examples, the polyploid population represented a minor subset of cells, though some tumors were composed primarily of such cells. As is often the case with such tumors, the prevalence of polysomies varied from region to region, thus contributing to overall tumoral heterogeneity. Polyploidy also complicated the interpretation of deletion in rare cases. For example, since most oligodendrogliomas are diploid or near diploid, we originally opted for the simplest FISH approach, with direct pairing of 1p and 19q probes on a single slide. In this way, as little as one unstained or destained section suffices per case. However, we recently encountered 2 oligodendrogliomas that recurred after many years; FISH demonstrated clear 1p/19q codeletion in the primaries, but no apparent deletions in the recurrences. As this seemed unlikely, we acquired a chromosome 1q42 probe and re-examined these cases using this reference probe (contaminant isolate from BAC clone 309C5, CIT978SK-A Library, Research Genetics). In both recurrent tumors, we identified a relative deletion, there being 4 copies of 1q (tetrasomy) but only 2 copies of 1p in the majority of cells (Figure 1C). Re-screening of our gliomas previously interpreted as negative for deletion revealed a total of 5 such cases, indicating that roughly 6% of 1p deletions are missed without the use of a reference probe. Thus far, our oligodendrogliomas with relative, rather than absolute deletion have all been high-grade and/or recurrent, suggesting that this pattern of polyploidy reflects a later stage of tumor progression. We have

recently switched to this method of testing with paired 1p and 19q probes. A 19p13.3 probe (BAC clone 575H1, RPCI-11 Library, Research Genetics) for use as a reference to the 19q probe has similarly been developed in our lab recently and is currently being evaluated. This probe pairing may be a bit more complicated to evaluate, given the chromosome 19 gains that may be seen in high-grade gliomas. However, simple gains that are unassociated with polyploidy often yield only one extra signal, rather than two. Relative 19q deletion (e.g. 4 copies of 19p, 2 copies of 19q) can also be distinguished from absolute 19p gains in most cases by the presence of a second subset of tumor cells with one 19q and two 19p signals, given that polyploid tumors typically retain some diploid neoplastic cells as well. Alternatively, one may use a chromosome 19 centromere-enumerating probe (CEP19) as the reference and then, this distinction would be less of an issue.

### 4.2. “Oligodendroglioma mimics” and specificity of deletions

Of the 41 oligodendroglioma mimics studied, all but 3 demonstrated the normal disomic state (i.e. 2 copies) for both 1p and 19q (Figure 1A). Two of 12 (17%) extraventricular neurocytomas (EVN) represented “false positives” with codeletion for 1p and 19q, while a third case showed evidence of a solitary 1p deletion. Thus, using histopathology as the “gold standard”, the 1p/19q codeletion was associated with a sensitivity of 70%, specificity of 95%, positive predictive value of 97%, and negative predictive value of 45% for the diagnosis of oligodendroglioma, when compared to this group of oligodendroglioma mimics. In the differential with EVN, the specificity dropped to 83%, whereas it was 100% when considering DNT, CN, and CCE. In other words, our data suggests that the finding of 1p/19q codeletion strongly supports a diagnosis of oligodendroglioma, whereas a negative result does not rule out this possibility. The “false positives” among the EVNs were of interest in that it introduces the possibility of misinterpretation. Re-review of our three deletion-bearing cases confirmed the original diagnosis of EVN based on diffuse synaptophysin immunoreactivity, the presence of neurocytic-like rosettes, and a more discrete growth pattern than is typically seen in oligodendroglioma. It is of interest that we have recently encountered bonafide oligodendrogliomas with a focal or patchy neurocytic component and 1p/19q codeletion by FISH (manuscript submitted). Our current data and prior studies demonstrating limited neuronal differentiation in morphologically typical oligodendrogliomas (27-30) all suggest that a greater overlap exists between oligodendroglioma and EVN than previously appreciated.

In terms of the differential between oligodendroglioma and astrocytoma, our data demonstrated a specificity of 96%, positive predictive value of 99%, and negative predictive value of 54% for the codeletion pattern. Again, this implies that a positive result is substantially more helpful than a negative one. As noted above however, mixed oligoastrocytomas demonstrate the 1p/19q deletion pattern in only 17% of cases, positive cases having the most convincing oligodendroglial morphology.

### 4.3. Clinical followup and associations with survival time

Given the prospective nature of this study, clinical followup has been limited to date (median, 1.1 years for the entire group), the longest follow-ups coming from patients with recurrent or progressive disease. Of 59 patients with meaningful followup (24%), 20 were followed until death and 47 for over 5 years. Sixteen patients (7%) have been followed for >10 years. For the 20 patients followed until death, the time from primary tumor diagnosis to death ranged from 3 months to 19.3 years; the clinical, pathologic and genetic features of these cases are summarized in Table 4.

Survivals of >5 years were associated with 1p/19q codeletion or solitary 19q deletion in 28 (60%) and 5 (11%) of 47 cases, respectively. Survivals of >10 years were associated with co-deletion of 1p/19q or with 19q deletion alone in 12 (75%) and 1 (6%) of 16 cases, respectively. In contrast, survivals ≤2 years (N=10) were associated with a normal FISH pattern for 1p and 19q in 70% of cases. Therefore, similar to previous retrospective series (20-22), there appear to be strong associations between genetic patterns and survival in our patients with sufficient followup. A number of notable exceptions are evident, however. For example, three patients had short survival times despite their having “genetically favorable” tumors with combined 1p/19q deletions (case numbers 55, 63, and 17). In these cases, there were other, clinicopathologic clues that portended a poor outcome. On average, the patients were older and all had bilateral, large contrast-enhancing tumors, two with a ring-enhancement pattern. The latter has been reported as an independent indicator of poor prognosis (20). Furthermore, one patient had multifocal disease and another was diagnosed as a grade IV MOA or GBM with oligodendroglial features. Likewise, there were a number of patients that enjoyed prolonged survival despite a lack of demonstrable 1p or 19q deletions. Most of them were young and were diagnosed with low-grade (WHO grade II) oligodendrogliomas or MOAs.

These exceptions highlight the importance of factoring in other well-established prognostic variables, such as patient age, presence or absence of oligodendroglial morphology, and histologic grade. Rather than relying purely on genetic features or histologic diagnosis alone, the greatest prognostic accuracy will likely be achieved by the combination of both. Analyses from our patients with multiple biopsies provide further support of this concept. All low-grade primary tumors with 1p/19q deletion that subsequently recurred as high-grade gliomas retained this “genetically favorable” pattern, either as absolute or relative deletions. Although the overall survival times in these patients was typically long, being greater than 19 years in two examples, the survival interval following the high-grade recurrence was often short. In other words, even “genetically favorable” oligodendroglial neoplasms eventually progress and the determination of survival time reflects their stage of biologic and genetic progression at the time of biopsy (see next section). In the case of our three deletion-bearing tumors with short survival, a more

**Table 4.** Summary of clinicopathologic and genetic features for 20 patients that have been followed until death

Case #	Age/Sex	Location	Primary	Recurrence	1p/19q status	Survival time
55	61 M	Frontal	O-III		Codeleted	3 months
64	69 M	Temp-Par	MOA-III		Normal	6 months
104	19 F	Thalamus	A-III		Normal	6 months
119	44 F	Frontal	MOA-II*		Normal	6 months
63	48 M	Cerebral	MOA-IV		Codeleted	6 months
23	41 M	Parietal	MOA-III		Normal	9 months
17	55 F	Frontal	O-III		Codeleted	11 months
44	55 M	Temporal	A-IV		Normal	1.1 years
15	52 M	Temporal	MOA-IV		Normal	1.8 years
29	40 M	Cerebral	O-III	O-III <sup>‡</sup>	Normal	2.0 years
20	35 F	Temporal	MOA-III	MOA-IV <sup>‡</sup>	19q deleted	2.2 years
10	49 M	Frontal	O-III <sup>‡</sup>	O-III <sup>‡</sup>	Polysomy	2.3 years
31	29 M	Temporal	O-II	O-III <sup>‡</sup>	Polysomy	6.6 years
42	29 M	Temporal	MOA-II	MOA-II <sup>‡</sup>	19q deleted	6.9 years
110	34 F	Parietal	O-II	MOA-III <sup>‡</sup>	Polysomy	7.5 years
11	26 M	Temporal	MOA-III <sup>‡</sup>	MOA-III <sup>‡</sup>	19q deleted	8.8 years
14	58 F	Frontal	O-III	O-III <sup>‡</sup>	Codeleted	12.4 years
78	35 F	Frontal	O-III <sup>‡</sup>	MOA-III <sup>‡</sup>	Codeleted	14.8 years
53	44 M	Parietal	O-II	O-IV <sup>‡</sup>	Codeleted	17.7 years
38	48 M	Frontal	O-II	O-III <sup>‡</sup>	Codeleted	19.3 years

\*Small biopsy with high likelihood of undersampling, Temp-Par = temporo-parietal, O = oligodendroglioma, A = astrocytoma, MOA = mixed oligoastrocytoma, <sup>‡</sup>specimen(s) assessed by FISH in cases with recurrences

advanced stage of biologic and genetic progression may already have been achieved at the time of clinical presentation. It is possible for example, that they either had subclinical disease for many years prior to their presentation or that their tumors accumulated additional mutations more rapidly than in most cases.

Our cases with prolonged survival despite lack of 1p/19q codeletion suggest that other “genetically favorable” phenotypes may also exist. Though significantly less common, the solitary 19q deletion may be one such example, despite its previously reported association with tumor progression in astrocytomas (25). In this study and in general, we have encountered this pattern most often in the mixed oligoastrocytomas and in morphologically ambiguous gliomas. For example, we recently performed a retrospective FISH study on 89 MOAs with either a) intermixed oligodendroglial and astrocytic elements or b) wherein the majority of tumor nuclei displayed features intermediate between those of classic oligodendroglioma and astrocytoma (manuscript submitted). This group comprises roughly 10-15% of the diffusely infiltrating gliomas and represents the subset in which diagnostic consensus is lowest and, therefore, the one wherein the benefits of ancillary genetic testing are potentially the greatest. Despite the relatively poor overall concordance among the 5 experienced neuropathologists defining this set of tumors, survival times fell between those typically encountered for pure oligodendrogliomas and astrocytomas of similar grade. This supports the value of assessing subtle signs of oligodendroglial morphology, even in this frustratingly challenging subset of diffuse gliomas. The 7% frequency of 1p/19q codeletion was even lower than that seen in the current study, though the 19q-only pattern of deletion was similarly encountered in 15% of cases and was generally associated with prolonged patient survival, particularly when one takes into account the high-grade designation for most of these tumors. Of even greater statistical significance, those tumors exhibiting genetic alterations typically encountered in high-grade astrocytoma (e.g. *PTEN* deletion, *p16* deletion, *EGFR*

amplification) were associated with markedly reduced survival times, suggesting that the incorporation of these markers could further improve prognostic accuracy. Interestingly, Burton and colleagues similarly found solitary 19q deletions by comparative genomic hybridization (CGH) in 6 (15%) of their 39 GBM patients with prolonged survival (personal communication, with Dr. Kenneth Aldape of MD Anderson Cancer Center, Houston, TX). Nevertheless, neither the current study nor others have thus far demonstrated an independent survival benefit to the solitary 19q deletion pattern by multivariate analysis. Given the relatively low incidence of this pattern, large series with extensive followup will likely be required to confirm or refute this possibility.

#### 4.4. Other potentially useful genetic markers

As alluded to above, 1p and 19q testing may be only one part of the story. Other genetic markers may further aid the diagnostic workup or affect the management of glioma patients. As our knowledge of tumor genetics increases, the list of potential markers will undoubtedly increase as well. Nonetheless, currently known alterations that provide potentially useful information include those primarily implicated in the development and progression of astrocytomas, such as *p53* mutation, *EGFR* gene amplification, chromosome 10 or *PTEN* (10q23.3) deletion, and *p16* (*CDKN2A*)/*p14*<sup>ARF</sup> deletions (1,2). Although we do not routinely test any for these in our FISH lab, in selected instances we have utilized each of these markers, except *p53*, which requires other techniques for accurate assessment. Ino *et al.* recently reported that anaplastic oligodendroglial tumors lacking 1p loss can be subdivided into those with and those without *p53* mutations (31). Those with mutations tended to respond well to chemotherapy, but recurred quickly and represented an intermediate prognostic group, in terms of survival. Those with neither 1p loss nor *p53* mutation were poorly responsive to therapy and had short survival times, similar to GBM.

*EGFR* amplification is relatively rare in oligodendroglial tumors (31). Furthermore, whether or not



these amplifications provide independent prognostic information in high-grade gliomas in general remains a matter of debate. We have, however, found the *EGFR* probe to be particularly useful in the differential diagnosis between small cell GBM and high-grade oligodendroglioma (23). Both tumors contain uniform round to oval nuclei and exhibit a high proliferation index (32). Whereas 70% of our oligodendrogliomas harbor 1p/19q deletions by FISH, small cell GBMs show a similar frequency of *EGFR* amplification (Figure 1D) and are typically negative for 1p/19q deletions (32).

Although some have found evidence for independent prognostic information regarding chromosome 10 losses in astrocytomas (33-35), others have found it to be statistically significant only on univariate analysis, given its strong association with histologic grade (36, 37). Losses of the *PTEN* gene on 10q23.3 have engendered similar debates (38-40). As with *EGFR*, both chromosome 10 losses and *PTEN* mutations are significantly less common in oligodendrogliomas than in astrocytomas. Nevertheless, these alterations as well as *p16 (CDKN2A)/p14<sup>ARF</sup>* deletions on 9p21 have been reported in a subset of high-grade oligodendrogliomas (31, 41-47) and in a significant proportion of MOAs (manuscript submitted).

## 5. SUMMARY

As the field of tumor genetics continues to grow, so will the role of ancillary genetic testing in the diagnostic workup of gliomas. Thus far, chromosome 1p and 19q testing is the only application routinely utilized within but a few laboratories in the USA. To our knowledge, ours is the largest summary of prospectively studied gliomas to date. Based on preliminary observations, we conclude that: 1) 1p/19q codeletion by FISH is relatively specific for oligodendrogliomas having a favorable prognosis, 2) solitary 19q deletions may also represent a “genetically favorable” pattern, particularly in high-grade MOAs, and 3) combined clinicopathologic and genetic assessment likely provides more accurate patient stratification than either approach alone. Additional followup is needed to solidify these possibilities. In addition, data derived from future inter-laboratory studies on sensitivities, specificities, and reproducibility will be of great value. In that 5-10% of morphologically typical GBMs also harbor 1p/19q deletions and since this may be prognostically relevant, it remains unclear whether testing should be restricted to oligodendroglial tumors or should be performed on all diffuse infiltrating gliomas. Similar questions related to other potential markers remain as well, and must be addressed with additional research. For example, if all potentially useful markers are sought in all tumors, glioma testing may rapidly become prohibitively expensive and time-consuming. Potentially useful genetic markers are also being identified in other central and peripheral nervous system tumors, further increasing the complexity and the volume of cases analyzed. More than likely, an agreed upon panel of genetic markers will eventually emerge and will become routinely available to pathologists, who will be called upon to judiciously select specific marker panels depending upon a tumor’s morphology and differential

diagnostic considerations. Such a scenario would be analogous to the current situation with antibody panels in immunohistochemistry. Given the technical similarities of FISH to immunohistochemistry and the utility of similarly processed paraffin sections, FISH will likely continue to play an increasingly important role in ancillary testing in neuro-oncology.

## 6. ACKNOWLEDGEMENTS

The authors are grateful to Drs. Robert Schmidt and Kevin Roth of the Neuropathology Division at Washington University School of Medicine for their diagnostic input.

## 7. REFERENCES

1. Kleihues, P. & W. K. Cavenee (Eds): World Health Organization classification of tumours. Pathology & genetics of tumours of the nervous system. IARC Press, Lyon, France (2000)
2. Smith, J. S. & R. B. Jenkins: Genetic alterations in adult diffuse glioma: occurrence, significance, and prognostic implications. *Frontiers Biosci* 5, d213-d231 (2000)
3. A Perry: Oligodendroglial neoplasms: Current concepts, misconceptions, and folklore. *Adv Anat Pathol* 8, 183-199 (2001)
4. Cairncross, J. G. & D. R. Macdonald: Successful chemotherapy for recurrent malignant oligodendroglioma. *Ann Neurol* 23, 350-364 (1988)
5. Glass, J. Hochberg, F. H. Gruber, M. L. Louis, D. N. Smith, D. & B. R. Rattner: The treatment of oligodendrogliomas and mixed oligodendroglioma-astrocytomas with PCV chemotherapy. *J Neurosurg* 76, 741-745 (1992)
6. Cairncross, J. G. Macdonald, D. Ludwin, S. Lee, D. Cascino, T. Buckner, J. Fulton, D. Dropcho, E., Stewart, D. Schold, J. Wainman N. & E. Eisenhauer: chemotherapy for anaplastic oligodendroglioma: National Cancer Institute of Canada Clinical Trials Group. *J Clin Oncol* 12, 2013-2021 (1994)
7. Mason, W. P. Krol, G. S. & L. M. DeAngelis: Low-grade oligodendroglioma responds to chemotherapy. *Neurology* 46, 2093-2097 (1996)
8. Jagadha, V. Halliday, W. C. & L. E. Becker: Glial fibrillary acidic protein (GFAP) in oligodendrogliomas: a reflection of transient GFAP expression by immature oligodendroglia. *Can J Neurol Sci* 13, 307-311 (1986)
9. Kros, J. M. van Eden, C. G. Stefanko, S. Z. Waayer-Van Batenburg, M. & T. H. van der Kwast: Prognostic implications of glial fibrillary acidic protein containing cell types in oligodendrogliomas. *Cancer* 66, 1204-1212 (1990)

10. Kros, J. M. de Jong, A. A. W. & T. H. van der Kwast: Ultrastructural characterization of transitional cells in oligodendrogliomas. *J Neuropathol Exp Neurol* 51, 186-193 (1992)
11. Coons, S. W. Johnson, P. C. Scheithauer, B. W. Yates, A. J. & D. K. Pearl: Improving diagnostic accuracy and interobserver concordance in the classification and grading of primary gliomas. *Cancer* 79, 1381-1393 (1997)
12. Daumas-Duport, C. Varlet, P. Tucker, M. L. Beuvon, F. Cervera, P. & J. P. Chodkiewicz: Oligodendrogliomas. Part I: Patterns of growth, histological diagnosis, clinical and imaging correlations: a study of 153 cases. *J Neuro-Oncol* 34, 37-59 (1997)
13. Fortin, D. Cairncross, G. J. & R. R. Hammond: Oligodendroglioma: an appraisal of recent data pertaining to diagnosis and treatment. *Neurosurgery* 45, 1279-1291 (1999)
14. Bruner, J. M. Inouye, L. Fuller, G. N. & L. A. Langford: Diagnostic discrepancies and their clinical impact in a neuropathology referral practice. *Cancer* 79, 796-803 (1997)
15. Aldape, K. Simmons, M. L. Davis, R. L. Miike, R. Wiencke, J. Barger, G. Lee, M. Chen, P. & M. Wrensch: Discrepancies in diagnoses of neuroepithelial neoplasms. The San Francisco Bay area adult glioma study. *Cancer* 88, 2342-2349 (2000)
16. Reifenberger, J. Reifenberger, G. Liu, L. James, C. D. Wechsler, W. & V. P. Collins: Molecular genetic analysis of oligodendroglial tumors shows preferential allelic deletions on 19q and 1p. *Am J Pathol* 145, 1175-1190 (1994)
17. Bello, M. J. Leone, P. E. Vaquero, J. de Campos, J. M. Kusak, M. E. Sarasa, J. L. Pestana, A. & J. A. Rey: Allelic loss at 1p and 19q frequently occurs in association and may represent early oncogenic events in oligodendroglial tumors. *Int J Cancer* 64, 207-210 (1995)
18. Kraus, J. A. Koopmann, J. Kaskel, P. Maintz, D. Brandner, S. Louis, D. N. Wiestler, O. D. & A. von Deimling: Shared allelic losses on chromosomes 1p and 19q suggest a common origin of oligodendroglioma and oligoastrocytoma. *J Neuropathol Exp Neurol* 54, 91-95 (1995)
19. Smith, J. S. Alderete, B. Minn, Y. Borell, T. J. Perry, A. Mohapatra, G. Smith, S. M. Kimmel, D. Yates, A. Feuerstein, B. G. Burger, P. C. Scheithauer, B. W. & R. B. Jenkins: Localization of common deletion regions on 1p and 19q in human gliomas and their association with histological subtype. *Oncogene* 18, 4144-4152 (1999)
20. Cairncross, J. G. Ueki, K. Zlatescu, M. C. Lisle, D. K. Finkelstein, D. M. Hammond, R. R. Silver, J. S. Stark, P. C. Macdonald, D. R. Ino, Y. Ramsay, D. A. & D. N. Louis: Specific genetic predictors of chemotherapeutic response and survival in patients with anaplastic oligodendrogliomas. *J Natl Cancer Inst* 90, 1473-1479 (1998)
21. Smith, J.S. Perry, A. Borell, T. J. Lee, H. K. O'Fallon, J. Hosek, S. M. Kimmel, D. Yates, A. Burger, P. C. Scheithauer, B. W. & R. B. Jenkins: Alterations of chromosome arms 1p and 19q as predictors of survival in oligodendrogliomas, astrocytomas, and mixed oligoastrocytomas. *J Clin Oncol* 18, 636-45 (2000)
22. Bauman, G.S. Ino, Y. Ueki, K. Zlatescu, M. C. Fisher, M. C. Macdonald, D. R. Stitt, L. Louis, D. N. & J.G. Cairncross: Allelic loss of chromosome 1p and radiotherapy plus chemotherapy in patients with oligodendrogliomas. *Int J Radiat Oncol Biol Phys* 48, 825-830 (2000)
23. Fuller C. E. & A. Perry: Fluorescence *in situ* hybridization (FISH) in diagnostic and investigative neuropathology. *Brain Pathol* 12, 67-86 (2002)
24. Cai, D. X. Banerjee, R. Scheithauer, B. W. Lohse, C. M. Kleinschmidt-DeMasters, B .K. & A. Perry: Chromosome 1p and 14q FISH analysis in clinicopathologic subsets of meningioma: Diagnostic and prognostic implications. *J Neuropathol Exp Neurol* 60, 628-36 (2001)
25. von Deimling, A. Bender, B. Jahnke, R. Waha, A. Kraus, J. A. Albrecht, S. A. Wellenreuther, R. Fassbender, F. Nagel, J. & A. G. Menon: Loci associated with malignant progression in astrocytomas: a candidate on chromosome 19q. *Cancer Res* 54, 1397-1401 (1994)
26. Zlatescu, M. C. Yazdi, A. T. Sasaki, H. Megyesi, J. F., Betensky, R. A. Louis, D.N. & J. G. Cairncross: Tumor location and growth pattern correlate with genetic signature in oligodendroglial neoplasms. *Cancer Res* 61, 6713-6715 (2001)
27. Ng, H-K. Ko, H. C. W. & C. C. H. Tse: Immunohistochemical and ultrastructural studies of oligodendrogliomas revealed features of neuronal differentiation. *Int J Surg Pathol* 2, 47-56 (1994)
28. Patt, S. Labrakakis, C. Bernstein, M. Weydt, P. Cervos-Navarro, J. Nisch, G. & H. Kettenmann: Neuron-like physiological properties of cells from human oligodendroglial tumors. *Neuroscience* 71, 601-611 (1996)
29. Wolf, H. K. Buslei, R. Blumcke, I. Wiestler, O. D. & T. Pietsch: Neural antigens in oligodendrogliomas and dysembryoplastic neuroepithelial tumors. *Acta Neuropathol* 94, 436-443 (1997)
30. Wharton, S. B. Chan, K. K. Hamilton, F. A. & J. R. Anderson: Expression of neuronal markers in oligodendrogliomas: an immunohistochemical study. *Neuropathol Appl Neurobiol* 24, 302-308 (1998)



31. Ino, Y. Betensky, R. A. Zlatescu, M. Z. Sasaki, H. Macdonald, D. R. Stemmer-Rachamimov, A. O. Ramsay, D. A. Cairncross, J. G. & D. N. Louis: Molecular subtypes of anaplastic oligodendroglioma: Implication for patient management at diagnosis. *Clin Cancer Res* 7, 839-845 (2001)
  32. Burger, P. C. Pearl, D. K. Aldape, K., Yates, A. J. Scheithauer, B. W. Passe, S. M. Jenkins, R. B. & C. D. James. Small cell architecture—A histologic equivalent of EGFR amplification in glioblastoma multiforme? *J Neuropathol Exp Neurol* 60, 1099-1104 (2001)
  33. Perry, A. Tonk, V. McIntire, D. & C. White: Interphase cytogenetic (*in situ* hybridization) analysis of astrocytomas using archival formalin-fixed, paraffin-embedded tissue and light microscopy. *Am J Clin Pathol* 108, 166-174 (1997)
  34. Balesaria, S. Brock, C. Bower, M. Clark, J. Nicholson, S. K. Lewis, P. de Sanctis, S. Evans, H. Peterson, D. Mendoza, N. Glaser, M. G. Newlands, E. S. & R. A. Fisher: Loss of chromosome 10 is an independent prognostic factor in high-grade gliomas. *Br J Cancer* 81, 1371-1377 (1999)
  35. Cianiulli, A. M. Morace, E. Coletta, A. M. Occhipinti, E. Gandolfo, G. M. Leonardo, G. & C. M. Carapella: Investigation of genetic alterations associated with development and adverse outcome in patients with astrocytic tumor. *J Neuro-Oncol* 48, 95-101 (2000)
  36. Ganju, V. Jenkins, R. B. O'Fallon, J. R. Scheithauer, B. W. Ransom, D. T. Katzmann, J. A. & D. W. Kimmel: Prognostic factors in gliomas. A multivariate analysis of clinical, pathologic, flow cytometric, cytogenetic, and molecular markers. *Cancer* 74, 920-927 (1994)
  37. Horiguchi, H. Hirose, T. Sano, T. & S. Nagahiro: Loss of chromosome 10 in glioblastoma: Relation to proliferation and angiogenesis. *Pathol Int* 49, 681-686 (1999)
  38. Lin, H. Bondy, M. L. Langford, L. A. Hess, K. R. Delclos, G. L. Wu, X. Chan, W. Pershouse, M. A. Yung, W. K. & P. A. Steck: Allelic deletion analyses of MMAC/PTEN and DMBT1 loci in gliomas: Relationship to prognostic significance. *Clin Cancer Res* 4, 2447-2454 (1998)
  39. Raffel, C. Frederick, L. O'Fallon, J. R. Atherton-Skaff, P. Perry, A. Jenkins, R. B. & C. D. James: Analysis of oncogene and tumor suppressor gene alterations in pediatric malignant astrocytomas reveals reduced survival for patients with PTEN mutations. *Clin Cancer Res* 5, 4085-90 (1999)
  40. Smith, J. S. Tachibana, I. Passe, S. M. Huntley, B. K. Borell, T. J. Iturria, N. O'Fallon, J. Schaefer, P. L. Scheithauer, B. W. James, C. D. Buckner, J. C. & R. B. Jenkins: PTEN mutations, EGFR amplification, and outcome in patients with anaplastic astrocytoma and glioblastoma multiforme. *J Natl Cancer Inst* 93, 1246-1256 (2001)
  41. Reifenberger, J. Reifenberger, G. Ichimura, K. Schmidt, E. E. Wechsler, W. & V. P. Collins: Epidermal growth factor receptor expression in oligodendroglial tumors. *Am J Pathol* 149, 29-35 (1996)
  42. Bortolotto, S. Chado-Piat, L. Cavalla, P. Bosone, I. Chio, A. Mauro, A. & D. Schiffer: *CDKN2A/p16* inactivation in the prognosis of oligodendrogliomas. *Int J Cancer* 88, 554-557 (2000)
  43. Sasaki, H. Zlatescu, M. C. Betensky, R. A. Ino, Y. Cairncross, J. G. & D. N. Louis: *PTEN* is a target of chromosome 10q loss in anaplastic oligodendrogliomas and *PTEN* alterations are associated with poor prognosis. *Am J Pathol* 159, 359-367 (2001)
  44. Kraus, J. A. Lamszus, K. Glesmann, N. Beck, M. Wolter, M., Sabel, M. Krex, D. Klockgether, T. Reifenberger, G. & U. Schlegel: Molecular genetic alterations in glioblastomas with oligodendroglial component. *Acta Neuropathol* 101, 311-320 (2001)
  45. He, J. Mokhtari, K. Sanson, M. Marie, Y. Kujas, M. Huguet, S. Leuraud, P. Capelle, L. Delattre, J. Y. Poirier, J. & K. Hoang-Xuan: Glioblastomas with an oligodendroglial component: a pathological and molecular study. *J Neuropathol Exp Neurol* 60, 863-871 (2001)
  46. Wolter, M. Reifenberger, J. Blaschke, B. Ichimura, K. Schmidt, E. E. Collins, V. P. & G. Reifenberger: Oligodendroglial tumors frequently demonstrate hypermethylation of the *CDKN2A* (*MTS1*, *p16<sup>INK4a</sup>*), *p14<sup>ARF</sup>*, and *CDKN2B* (*MTS2*, *p15<sup>INK4b</sup>*) tumor suppressor genes. *J Neuropathol Exp Neurol* 60, 1170-1180 (2001)
  47. Watanabe, T. Yokoo, H. Yokoo, M. Yonekawa, Y. Kleihues, P. & H. Ohgaki: Concurrent inactivation of RB1 and TP53 pathways in anaplastic oligodendrogliomas. *J Neuropathol Exp Neurol* 60, 1181-1189 (2001)
- Key Words:** Astrocytoma, Brain Tumors, Chromosome 1, Chromosome 19, Dysembryoplastic Neuroepithelial Tumor, Genetics, In Situ Hybridization, Loss Of Heterozygosity, Neurocytoma, Oligodendroglioma, Prognosis, Review
- Send correspondence to:** Arie Perry, M.D., Division of Neuropathology, Campus Box 8118, Washington Univ. School of Medicine, 660 South Euclid Avenue, St. Louis, MO 63110-1093, Tel: 314-362-9130, Fax: 314-362-4096, E-mail: aperry@pathbox.wustl.edu