

Pitfalls in the diagnosis and initial management of acute cerebral venous thrombosis

Huaying Cai¹, Xiaobin Ye^{1,2}, Weiliang Zheng³, Li Ma⁴, Xingyue Hu^{1,*} and Xing Jin^{1,*}

¹Department of Neurology, Neuroscience Center, Sir Run Run Shaw Hospital, School of Medicine, Zhejiang University. No.3 East Qingchun Rd., Hangzhou, Zhejiang, China, 310020

²Department of Neurology, Wen Ling Hospital of Traditional Chinese Medicine. No.21 North Mingyuan Rd. Taizhou, Zhejiang, China, 317500

³Department of Radiology, Sir Run Run Shaw Hospital, School of Medicine, Zhejiang University. No.3 East Qingchun Rd., Hangzhou, China, 310020

⁴Department of Neurology, Shao Xing No. 2 People's Hospital. No.147 Yanan Rd. Shaoxing, Zhejiang, China, 312000

*Correspondence to Xing Jin: jxmartin@zju.edu.cn
Xingyue Hu: huxingyue2003@zju.edu.cn

DOI: 10.31083/j.rcm.2018.04.4081

This is an open access article under the CC BY-NC-ND license (<https://creativecommons.org/licenses/by-nc/4.0/>)

Cerebral venous thrombosis is an important etiology of stroke in young patients. Its clinical manifestations are variable and based on different involved venous or sinus processes. Cerebral venous thrombosis could mimic ischemic infarction and is easy to misdiagnose. Although many patients have favorable outcomes, delayed or incorrect diagnosis due to atypical symptoms may lead to a poor prognosis. Here we present a case of a 33-year-old woman with transient headache and recurrent right extremity weakness whose symptoms progressed and were sustained in the hospital. She was diagnosed with ischemic infarction and recombinant tissue plasminogen activator (rtPA) thrombolysis was performed. However, her symptoms progressed, and intracranial hematoma was found on a computed tomography scan. Ruling out other hemorrhage etiology, we confirmed the presence of cerebral venous thrombosis using magnetic resonance venography. She underwent mechanical thrombectomy and her condition improved thereafter. This case raises the awareness that in young woman patients on oral contraceptives with neurological deficits and headache, cerebral venous thrombosis is a considerable diagnosis. A contrast CT or MRI scan should be ordered in the early course of evaluation, which can help the physician to make the right clinical decision.

Keywords

Cerebral venous thrombosis; recombinant tissue plasminogen activator; catheter-based local thrombolysis; thrombectomy

1. Introduction

Cerebral venous thrombosis (CVT) is a rare but important cause of stroke for young patients. The incidence of CVT is approximately 1.3/100,000 with a ratio of women to men 3:1

(Coutinho et al., 2012). Risk factors associated with CVT include female, oral contraceptive, pregnant, genetic thrombophilia, tumor and obesity. Clinical manifestations are variable based on different involved cortical venous or sinuses. Main clinical symptoms include headache, focal or generalized seizure, confusion and focal neurologic deficits (Ferro, 2004). CVT usually has a favorable prognosis, but delayed diagnosis or treatment may lead to poor outcome.

We report the details of a patient with CVT who had ischemic infarction but experienced intracranial hemorrhage after undergoing recombinant tissue plasminogen activator (rtPA) thrombolysis. As far as we know, this is the first reported patient in whom CVT was misdiagnosed as ischemic infarction that was complicated by severe hematoma after rtPA thrombolysis was performed.

2. Case Report

A 33-year-old woman was in normal health until one day before hospital admission, when she presented with a transient headache and right extremity weakness that lasted for a couple of minutes. Her medical history included endometrial hyperplasia, and she took norethisterone for 3 months. She denied any history of hypertension, diabetes, major surgery, trauma, or other drug use. She was diagnosed with transient ischemic attack. She was prescribed aspirin and clopidogrel to prevent another attack.

After admission, she presented with right arm weakness again that was sustained for almost 1 hour. A physical examination revealed that the patient had decreased right arm strength (4/5). The remainder of the examination was unremarkable. The initial National Institute of Health Stroke Scale (NIHSS) score was 5. Laboratory findings included a C-reactive protein level of 25.1 mg/L (normal range: 0-10 mg/L) and D-dimer level of 414 ng/ml (normal range: 0-400 ng/ml). A computed tomography (CT) scan ruled out cerebral hemorrhage (Fig. 1A); then, intravenous rtPA throm-

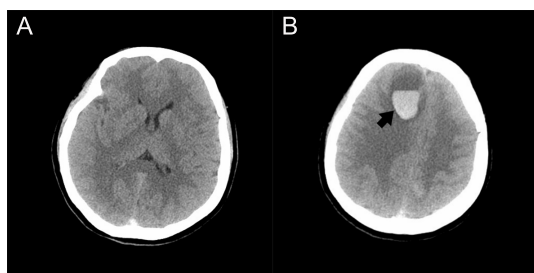


Figure 1. A: The initial CT scan on admission ruled out intracerebral hemorrhage. There is an ambiguous hyperdensity in the superior sagittal sinus. It was difficult to diagnose CVT at that moment based on this atypical, B: A CT scan at 2 hours after rtPA thrombolysis revealed a right frontal lobe hematoma (arrow). The middle line was left-shifted, with progressed paralysis and decreased consciousness level CT: computed tomography; sign CT: computed tomography; CVT: cerebral venous thrombosis; rtPA: recombinant tissue plasminogen activator

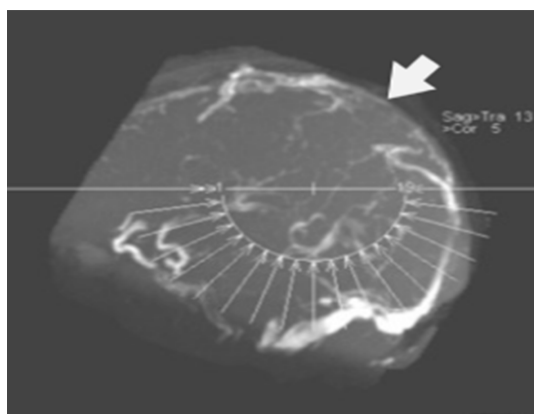


Figure 2. Emergent MRV revealed a thrombosis in the superior sagittal sinus and transverse sinus (arrow) MRV: magnetic resonance angiography

bolysis (0.9 mg/kg, total dose: 36 mg) was administered and the patient's symptoms improved (the NIHSS score was 3). About 1 hour after thrombolysis was administered, the patient experienced a severe headache with vomiting, and went into a coma. An immediate physical examination revealed a score of 1/5 in the left lower extremity and 0/5 in the rest of the extremities. Both pupils' size was 4 mm and was reactive to light. The Glasgow coma scale score was 2+1+4. A cerebral CT scan revealed the presence of a right frontal lobe hematoma (Fig. 1B). Emergent cerebral magnetic resonance angiography (MRA) and magnetic resonance venography (MRV) revealed the presence of superior sagittal sinus and bilateral transverse sinus thromboses (Fig. 2).

The patient underwent emergent cerebral venous angiography and mechanical thrombectomy. A filling defect in the superior sagittal sinus was revealed (Fig. 3A). Several thrombi were retrieved using Solitaire stenting, and the superior sagittal sinus was completely recanalized (Fig. 3B). Anticoagulation therapy with low molecular weight heparin was started one day after the

thrombectomy. Over the next 2 weeks, the patient began rehabilitation, and her strength improved, with a score of 5/5 in the left extremities and 5-/5 in the right extremities. A review of CT scans showed resolution of the frontal hematoma. The thrombophilia workup was unremarkable except for decreased levels of protein C and S (protein C: 37% [normal range: 60%-140%]; protein S: 55.8% [normal range: 63.5%-149%]). Tests for vasculitis, syphilis, human immunodeficiency virus, and toxicity were all negative. The patient continued recovering well, and warfarin was bridged with a goal international normalized ratio of 2-3 at discharge. MRV at 3 months' and 6 months' follow-up was positive for mild stenosis of the left transverse sinus (Fig. 4), but the venous flow was clear and there was no obvious neurological defect. At her 1-year follow-up visit, she was still doing well.

3. Discussion

We report the case of a patient with CVT that initially manifested as acute ischemic infarction. It is difficult for us to diagnose CVT based on non-contrast CT scan (Fig. 1A). When the symptoms progressed, unilateral weakness was sustained. It was reasonable to perform intravenous rtPA thrombolysis when the patient was still in the time window for administration without contraindications. We found that the patient had a history of oral contraceptive drug use, and headaches, and an elevated D-dimer level when the symptoms began, which were combined with focal hemorrhage and edema, strongly suggesting CVT. The most common cause of parenchymal hematoma after thrombolysis is thrombolytic drug-associated hemorrhage. Other differential diagnoses of hematoma include vascular malformation, aneurysm, CVT, and systemic coagulation disorders. In our case, emergent cerebral MRA ruled out arterial system problems. Cerebral venous thrombosis is easily misdiagnosed. In one study (WANG et al., 2012), 8 of 18 (44.4%) CVT patients were misdiagnosed as hemorrhage, infarction, subarachnoid hemorrhage, encephalitis and occupying lesion. Most misdiagnoses were due to variable clinical manifestations and ambiguous neuroimaging signs (WANG et al., 2012). (Table. 1) summarizes cases of CVT that were misdiagnosed and mismanagement.

There are no published randomized trials on thrombolysis for CVT. Only a few reports have been published on CVT that was treated with systemic rtPA thrombolysis. The optimal dose and

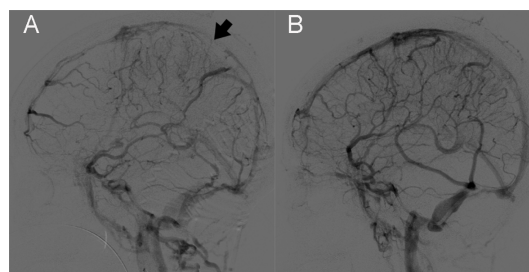


Figure 3. A: A cerebral DSA revealed a filling defect in the superior sagittal sinus (arrow) and confirmed the diagnosis of CVT. DSA: digital subtraction angiography; CVT: cerebral venous thrombosis, B: Sagittal sinus recanalization after mechanical thrombectomy revealed improved venous flow in the sagittal sinus

Table 1. Reported cases of cerebral venous thrombosis that were misdiagnosed

Author	Age/Gender	Clinical Presentation	Misdiagnosis	Outcome	Lessons Learned
Gupta et al., 2009	42/male	continuous headache, photophobia, speech disturbance and weakness of right upper limb	delayed diagnosis CVT	full recovery	clinician should have high index of suspicion to facilitate a prompt diagnosis through neuroimaging
Unal et al., 2016	78/male	sudden-onset, thunderclap headache	subarachnoid hemorrhage	full recovery	non-contrast CT can be misinterpreted, MRV should be performed in suspected patients
Taniguchi et al., 2017	52/female	Altered consciousness	acute necrotizing encephalopathy	slight memory impairment and mild hemiparesis	bilateral thalamic lesions presence, CVT should be considered
Alshurafa et al., 2018	35/female	left frontal, continuous, throbbing headache	migraine	permanent vegetative state	CVT can present with migraine-like headache alone
Iqbal and Sharma, 2013	35/female	sudden onset of headache, blurred vision, left side weakness	metastases	full recovery	CVT should be considered with cortical hemorrhagic lesions with massive edemas
Zahrani et al., 2019	24/female	slurred speech and generalized tonic-clonic seizure	intracranial hemorrhage	full recovery	CVT should be differentiated in pregnant female with headaches

administration route are still undetermined. Tarani reported a 3-year-old CVT patient treated by rtPA at 0.6 mg/kg/day for 9 days and total dosage was 378 mg ([Tarani et al., 2002](#)). Another patient received intravenous rtPA at 0.9 mg/kg for 1 hour with total dosage 63 mg and followed by heparin. Both patients had a favorable outcome. Three recent systematic reviews analyzed CVT patients who were treated with systemic thrombolysis ([Canhão et al., 2003](#); [Dentali et al., 2010](#); [Viegas et al., 2014](#)). Urokinase was the most frequently used thrombolytic drug (in 70.5%-75.1% of cases); only a few patients underwent rtPA thrombolysis (7.7%-28.8%). The partial and complete recanalization rates were 61.5%-91.2%, respectively. The intracranial hemorrhage rate was 7.7%-11.5% and the mortality rate due to intracranial hemorrhage was 4.5%-7.7%. Therefore, it is unwise to perform intravenous thrombolysis on CVT patients unless the risks of intracranial hemorrhage are carefully evaluated. The first-line acute treatment of CVT is immediate anticoagulation with heparin or low molecular weight heparin. Both ESO and AHA/ASA guidelines recommended anticoagulation for patients with acute CVT ([Ferro et al., 2017](#); [Saposnik et al., 2011](#)). A meta-analysis revealed that anticoagulation was associated with relative risk of death of 0.33 (95% CI 0.08-1.21) and a risk of death or dependency of 0.46 (95% CI 0.16-1.31) ([Stam et al., 2003](#)). After acute phase, most CVT patients should receive long-term anticoagulation with warfarin for at least 3 months to prevent CVT recurrence, aiming at an INR target 2 to 3 ([Ferro et al., 2017](#)). However, about 13% patients still had poor outcomes despite anticoagulation therapy ([Ferro, 2004](#)). Predictors of poor outcomes include clinical deterioration, intracerebral hemorrhage, alteration of consciousness and deep CVT ([Canhao et al., 2005](#)). Patients with these critical predictors may benefit from catheter-based local thrombolysis or mechanical thrombectomy. While the purpose of systemic anticoagulation is mainly to prevent throm-

bus propagation, catheter-based local thrombolysis and mechanical thrombectomy can lead to rapid restoration of the venous blood flow. Thrombolytic drug is directedly infused into the venous sinus through a microcatheter during local thrombolysis. It can increase the intra-sinus thrombolytic drug concentration and drug-thrombus contact surface ([Li et al., 2013](#)). However, only several small cases series reported the advantage of local thrombolysis. Guo et al. reported 37 CVT patients treated by local thrombolysis, 34 (91.9%) had good outcomes, 2 (5.4%) died and 1 (2.7%)

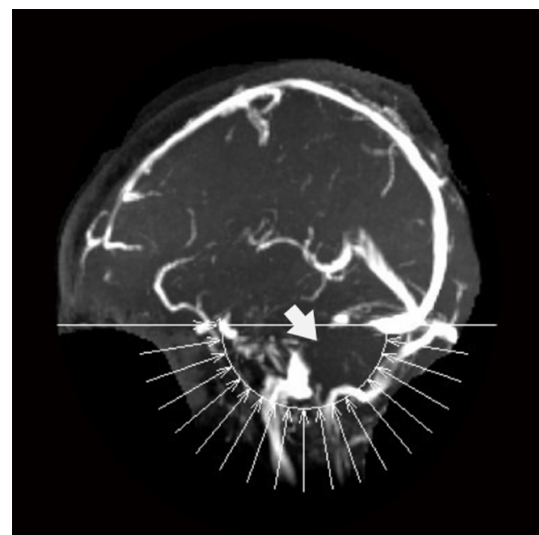


Figure 4. MRV was reviewed at the 3-month follow-up. The sagittal and transverse sinus venous flow was clear, although segmental stenosis was found in the left transverse sinus (arrow). MRV: magnetic resonance venography

remained disability (Guo et al., 2012). Safety is also a concern in local thrombolysis. Dentali reported 9.8% major hemorrhage rate and 7.6% intracranial hemorrhage rate during local thrombolysis (Dentali et al., 2010). Other limitations including lacking standard procedure, taking too much time in critical patients restrain its clinical usage. As development of endovascular technique and devices, local thrombolysis is rarely performed alone, but in combination with mechanical thrombectomy. The most common indications for thrombectomy included severe sinus thrombosis, poor mental status, progression of neurological deficits, failed anticoagulation therapy, and elevated intracranial pressure. All these indications called attention to the high risk of poor outcomes that may occur in patients with CVT. A systemic analysis reviewed 185 CVT patients underwent mechanical thrombectomy, among whom 95% had partial and complete recanalization, 84% had a good outcome and 12% died (Siddiqui et al., 2015). This indicates that thrombectomy is reasonably safe and effective in patients with a high risk of having a poor outcome. In our case, severe intracranial hematoma aggravated the patient's paralysis and disturbed her consciousness, putting her at risk of developing herniation. Although anticoagulation is not contraindicated in patients with intracerebral hemorrhage, mechanical thrombectomy is a better option in these critical situations. Therefore, for CVT patients whose clinical symptoms have progressed and there is an obvious mass effect, severe hemorrhage, or intracranial hypertension, thrombectomy should be considered.

Approximately 22% CVT patients had genetic thrombophilia (Viegas et al., 2014). More than half of female patients have a history of oral contraceptive use (Viegas et al., 2014). Oral contraceptive users with gene mutations had an estimated risk of CVT that was 34 times higher than that of women with neither factor (Saadatnia and Tajmirriahi, 2007). Protein S and C deficiencies are the most common genetic thrombophilia risk factor of CVT; protein C deficiency is the most prevalent thrombophilia marker (Pai et al., 2013). The patient in our report took oral contraceptive drugs and had decreased levels of protein C and protein S, which led to hypercoagulability and cerebral venous thrombosis. She had a higher recurrence rate for risk factors that previously reported and need long-term anticoagulation therapy.

4. Conclusion

Cerebral venous thrombosis is a rare etiology of stroke. However, in patient presented with sudden neurological deficit with severe headache, especially in a young woman with contraceptive drug usage, CVT is a considerable diagnosis. For those patients, a contrast CT or MRI scan should be ordered in the early course of evaluation, which can help the physician to make the right diagnosis and avoid the potential risks of systemic rTPA thrombolysis. Anticoagulation is still the first-line therapy for CVT. The effect of both systemic or local thrombolysis is undefined. Mechanical thrombectomy is reasonably safe and effective, especially for patients with progressed clinical symptoms, obvious mass effect or severe intracranial hematoma.

Acknowledgements

We thank the patient and her families for their active cooperation. This work was supported in part by the Natural Science Foundation of China (grant numbers 81400926), Health General Research Project of Zhejiang Province, China (grant numbers 2018RC045), and the Natural Science Foundation of Zhejiang Province of China (LY19H090027).

Conflict of interest

The authors have no conflict of interest to declare. This study was approved by the Medical Ethics Committee of Sir Run Run Shaw Hospital, Zhejiang University. All treatments and operation were carried out after obtaining informed consent from the patient.

References

- Alshurafa S, Alfihil W, Alshurafa A, et al. Cerebral venous sinus thrombosis in a young female misdiagnosed as migraine ending in a permanent vegetative state: A case report and review of the literature. *Journal of Medical Case Reports*. 2018;12:323.
- Canhão P, Falcão F, Ferro JM. Thrombolytics for cerebral sinus thrombosis: a systematic review. *Cerebrovascular Diseases*. 2003;15:159-166.
- Canhao P, Ferro JM, Lindgren AG, et al. Causes and predictors of death in cerebral venous thrombosis. *Stroke*. 2005;36:1720-1725.
- Coutinho JM, Zuurbie SM, Aramideh M, et al. The incidence of cerebral venous thrombosis: a cross-sectional study. *Stroke: a Journal of Cerebral Circulation*. 2012;43:3375-3377.
- Dentali F, Squizzato A, Gianni M, et al. Safety of thrombolysis in cerebral venous thrombosis. a systematic review of the literature. *Thrombosis and Haemostasis*. 2010;104:1055-1062.
- Ferro JM. Prognosis of cerebral vein and dural sinus thrombosis: results of the international study on cerebral vein and dural sinus thrombosis (ISCVT). *Stroke*. 2004;35:664-670.
- Ferro JM, Boussier MG, Canhão P, et al. European stroke organization guideline for the diagnosis and treatment of cerebral venous thrombosis – endorsed by the european academy of neurology. *European Journal of Neurology*. 2017;24:1203-1213.
- Guo X, Guan S, Fan Y, et al. Local thrombolysis for severe cerebral venous sinus thrombosis. *American Journal of Neuroradiology*. 2012;33:1187-1190.
- Gupta RK, Jamjoom AAB, Devkota UP. Superior sagittal sinus thrombosis presenting as a continuous headache: a case report and review of the literature. *Cases Journal*. 2009;21:1-4.
- Iqbal N, Sharma A. Cerebral venous thrombosis: a mimic of brain metastases in colorectal cancer associated with a better prognosis. *Case Reports in Oncological Medicine*. 2013;2013:1-3.
- Li G, Zeng X, Hussain M, et al. Safety and validity of mechanical thrombectomy and thrombolysis on severe cerebral venous sinus thrombosis. *Neurosurgery*. 2013;72:730-738.
- Pai N, Ghosh K, Shetty S. Hereditary thrombophilia in cerebral venous thrombosis. *Blood Coagulation & Fibrinolysis*. 2013;24:540-543.
- Saadatnia M, Tajmirriahi M. Hormonal contraceptives as a risk factor for cerebral venous and sinus thrombosis. *Acta Neurologica Scandinavica*. 2007;115:295-300.
- Saposnik G, Barinagarrementeria F, Brown RD, et al. Diagnosis and management of cerebral venous thrombosis: A statement for healthcare professionals from the American Heart Association/American Stroke Association. *Stroke*. 2011;42:1158-1192.
- Siddiqui FM, Dandapat S, Banerjee C, et al. Mechanical thrombectomy in Cerebral venous thrombosis: systematic review of 185 cases. *Stroke*. 2015;46:1263-1268.
- Stam J, de Bruijn S, DeVeber G. Anticoagulation for cerebral sinus thrombosis. *Stroke*. 2003;34:1054-1055.

- Taniguchi D, Nakajima S, Hayashida A, et al. Deep cerebral venous thrombosis mimicking influenza-associated acute necrotizing encephalopathy: a case report. *Journal of Medical Case Reports*. 2017;11:1-6.
- Tarani L, Iacobini M, De Stefano V, et al. Recombinant plasminogen activator therapy for cerebral vein thrombosis in a child carrier of prothrombin gene mutation. *Journal of Pediatric Hematology/Oncology*. 2002;24:769-771.
- Unal AY, Unal A, Goksu E, et al. Cerebral venous thrombosis presenting with headache only and misdiagnosed as subarachnoid hemorrhage. *World Journal of Emergency Medicine*. 2016;7:234-236.
- Viegas LD, Stolz E, Canhão P, et al. Systemic thrombolysis for cerebral venous and dural sinus thrombosis: a systematic review. *Cerebrovascular Diseases*. 2014;37:43-50.
- WANG X, SUN X, LIU H. Clinical analysis and misdiagnosis of cerebral venous thrombosis. *Experimental and Therapeutic Medicine*. 2012;4:923-927.
- Zahrani, AMA, Sheikh, RA. Cerebral Venous Sinus Thrombosis with an Intracranial Haemorrhage: a case Report. *Open Access Macedonian Journal of Medical Sciences*. 2019;7:1029-1031.