

Case Report

Imminent rupture of abdominal aortic aneurysm complicated by arteriovenous fistulaization and hepatorenal failure: case report and literature review

Daozheng Huang^{1,†}, Feier Song^{2,†}, Xiaomin Zhou³, Huan Ma³, Shuo Chen⁴, Yinjun Xie¹, Shouhong Wang^{1,*} and Tiehe Qin^{1,*}

¹Department of Critical Care Medicine, Guangdong Provincial Geriatrics Institute, Guangdong Provincial People's Hospital, Guangdong Academy of Medical Sciences, Guangzhou 510080, P. R. China

²Department of Emergency and Critical Care Medicine, Guangdong Provincial People's Hospital, Guangdong Academy of Medical Sciences, Guangzhou, 510080, P. R. China

³Department of Cardiology, Guangdong Cardiovascular Institute, Guangdong Provincial People's Hospital, Guangdong Academy of Medical Sciences, Guangzhou 510080, P. R. China

⁴Department of Echocardiography, Guangdong Cardiovascular Institute, Guangdong Provincial People's Hospital, Guangdong Academy of Medical Sciences, Guangzhou 510080, P. R. China

*Correspondence: huang1huang2@163.com (Shouhong Wang) and qintiehe@163.com (Tiehe Qin)

†These authors contributed equally.

DOI: [10.31083/j.rcm.2020.01.588](https://doi.org/10.31083/j.rcm.2020.01.588)

This is an open access article under the CC BY-NC 4.0 license (<https://creativecommons.org/licenses/by-nc/4.0/>).

Arteriovenous fistula (AVF) is a rare complication of the abdominal aortic aneurysm (AAA) with complex clinical features. However, AVF and AAA usually cause no symptoms except when they rupture. This case study demonstrated that ultrasonography was a rapid and non-invasive method for the initial assessment of AAA and AVF. A 65-year-old man was admitted to the intensive care unit with hepatic and renal dysfunction. Physical examination revealed an abdominal vascular murmur and bilateral toe discoloration. Ultrasonic examination revealed an AAA and right common iliac artery aneurysm with an AVF located between the right common iliac artery and inferior vena cava. A computed tomography scan confirmed the sonographic findings. We propose that ultrasound should be used more commonly as part of the initial evaluation of the potential and established vascular diseases.

Keywords

Abdominal aortic aneurysm; arteriovenous fistula; hepatorenal dysfunction; ultrasound

1. Background

Arteriovenous fistula (AVF) is a very rare complication of the abdominal aortic aneurysm (AAA) and is a life-threatening condition with complex clinical features. Timely diagnosis and surgical treatment impose a huge impact on reducing morbidity and mortality for those patients. However, AVF and AAA usually cause no symptoms except when they rupture (Wilmink and Quick, 1998). Most common iliac artery aneurysms develop in patients with AAA, and about 20% of patients with AAA have a common iliac artery aneurysm (Armon et al., 1998). Infrarenal aortic aneurysms

with the involvement of the right iliac artery seem to be associated with a high risk of perforation into the inferior vena cava (IVC), which might result in the ilio caval fistula. It had been rarely reported that hepatic and renal dysfunction be the main manifestations of AAA and AVF in a critically ill patient (Gregoric et al., 1991; Lau et al., 2001; Simsek et al., 2014). Here, we reported a case of a patient with hepatic and renal dysfunction as the main manifestations of AAA and AVF. It was important to be aware of the possibility of AAA and AVF. Once AAA or AVF was suspected, the necessary examinations should be adapted to help differential diagnosis. The gold standard of detecting and characterizing an aortocaval fistula today is computed tomography angiography (CTA) (Rosenthal et al., 1998). But computed tomography (CT) scan has limited usage among critically ill patients, due to the increased risk in patient transport, radiation exposure, and high cost. Our case study demonstrated that ultrasonography was a rapid and non-invasive method for the initial assessment of AAA and AVF.

2. Case presentation

On Jan 25th, 2017, a 65-year-old man was admitted to Guangdong General Hospital, Guangzhou, China. His presenting complaints were fatigue and oliguria for nine days without abdominal pain. He had a history of hypertension for ten years, without a history of alcohol intake, viral hepatitis or chronic kidney disease. He had not taken any drugs that caused liver and kidney damage recently. On presentation, he had a heart rate of 100 beats per minute and a blood pressure of 120/60 mmHg. Laboratory tests in local hospital suggested severe impaired liver and renal function (alanine transaminase (ALT) 2037 U/L, aspartate transaminase (AST)

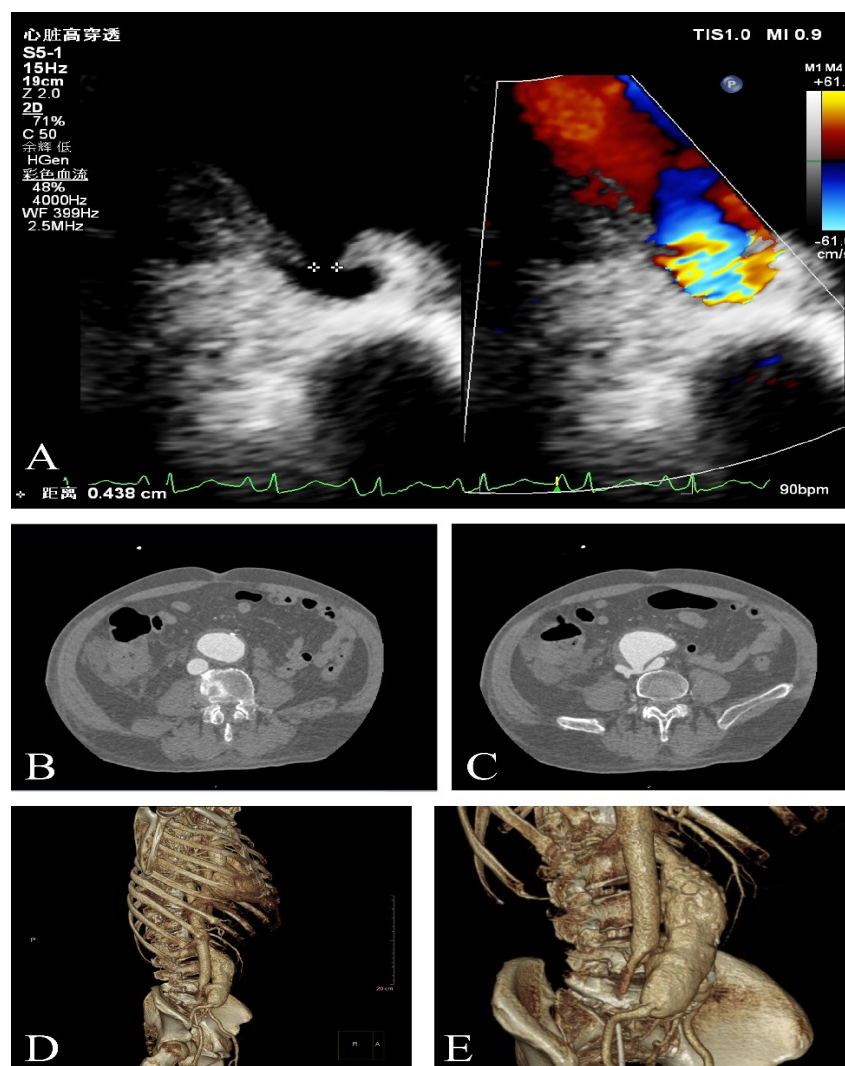


Figure 1. Ultrasound images and CT of an AAA and AVF located between right common iliac artery aneurysm and IVC. Imaging was captured within one hour of admission. Fig. 1A was sonograms showing an AAA and AVF between right common iliac artery aneurysm and IVC. AVF (thick arrows) between right common iliac artery aneurysm and IVC is clearly visible. Fig. 1B and 1C were axial images from enhanced CT scans. Continuity between the right common iliac artery aneurysm and IVC represents AVF (thin arrow). Figure 1D and 1E were three-dimensional volume-rendered images of the AAA and AVF (red arrows). The figure here is original for this paper.

1479 U/L, total bilirubin (TBIL) 123.4 $\mu\text{mol/L}$, direct bilirubin (DBIL) 70.7 $\mu\text{mol/L}$, serum creatinine (SCr) 378.9 $\mu\text{mol/L}$, blood urea nitrogen (BUN) 16.6 mmol/L) with unknown cause.

Under the critical condition, the patient was referred to the intensive care unit (ICU). Physical examination revealed an abdominal vascular murmur and bilateral toe discoloration. Bedside ultrasound was routinely performed for vascular screening in ICU, as well as echocardiography and lung ultrasonography. Ultrasound examination revealed an AAA and the right common iliac artery aneurysm with an AVF located between the right common iliac artery and IVC. The latter led to a similar pathophysiological abnormality of portal hypertension that explained hepatorenal dysfunction. A CT scan confirmed the sonographic findings (Fig. 1).

The patient underwent continuous renal replacement therapy (CRRT) and liver protection therapy. Unfortunately, he died of the ruptured AAA on admission day.

3. Discussion and Conclusions

AAA is generally asymptomatic or has atypical clinical manifestations until rupture (Ali et al., 2016; Sidloff et al., 2014; Wilmink and Quick, 1998). A delay in diagnosis can cause a potentially fatal outcome as the ruptured vessel no longer functions normally. In our case, the patient had been previously diagnosed with hepatic and renal insufficiency for an unknown reason. Unfortunately, the potential of AAA and AVF that may contribute to this pathology had not been investigated. The awareness of the possibility of AAA and AVF is essential to the correct diagnosis. Only in this way can appropriate examination be adapted to help differential diagnosis.

The main manifestation of the patient in our case was hepatic and renal dysfunction. Although the patient complained of no classically abdominal pain, physical examination revealed an abdominal vascular murmur. Impaired liver and renal function happening in patients with AVF might represent consequences of the

hemodynamic derangements of a large volume left-to-right shunt. It results in increased venous return leading to venous hypertension, passive venous congestion, hepatomegaly, ascites, and portal hypertension (Coulrier et al., 2004). Gregoric et al. (1991) first described a case of an aortocaval fistula presenting an acute renal failure. Lau et al. (2001) reported a case of an aortoiliac aneurysm with an aortocaval fistula, presenting a moderate degree of renal and hepatic impairment returned to normal merely two days after successfully treated with endovascular stent-grafting. Simsek et al (Simsek et al., 2014) also pointed out that acute renal and hepatic insufficiency could be caused by a long-term untreated fistula as a consequence of increased venous pressure. In our case, acute hepatic and renal dysfunction had developed as a consequence of increased venous pressure. Though the patient underwent intensive care including CRRT and liver protection therapy, the ruptured AAA and AVF contributed to the lethal outcome before the operation.

Previous studies supported that atypical symptoms should not be an excuse for prolonged investigation and that urgent sonography was favorable to initiate the diagnosis (Catalano et al., 2005; Miller et al., 1999). Point of care ultrasonography (POCUS) is used with increasing worldwide popularity in rapid screening for AAA (Jones et al., 2003) and blunt abdominal trauma (Bode et al., 1999). POCUS provides longitudinal or transverse images of the vasculature and is an easy, accessible extension of the bedside physical examination. Goergen et al. demonstrated that in the infrarenal abdominal aorta, anterior wall displacement is roughly 3.6 times larger than posterior wall displacement, while ultrasound was able to produce a direct measurement with adequate resolution noninvasively (Goergen et al., 2007). Chun et al. (2019) reported the ectatic aorta prevalence, AAA development, rupture risk in an AAA screening program, emphasizing the significance of the initial screening. Ultrasound findings have been shown to correlate well with CT imaging (Manning et al., 2009; Scaife et al., 2016). Three-dimensional(3-D) ultrasound is potentially applied in the measurement of diameter and volume, endoleak detection, and rupture risk prediction (Lowe et al., 2016). By integrating into the patient-specific modeling tool, the 3-D ultrasound showed the potential to help clinical practice (Owen et al., 2016). Van Disseldorp et al. compared geometry and wall stress results of the AAA, which played an important role in rupture risk assessment, and multiperspective 3-D US data revealed a great similarity to CT (van Disseldorp et al., 2020). Rogers et al. demonstrated the utility of contrast-enhanced ultrasound and contrast-enhanced tomographic 3-D ultrasound, for immediate post- endovascular-aneurysm repair endoleak detection (Rogers et al., 2019).

Base on the abovementioned literature, there was more than one imaging way in the diagnosis of AAA and AVF. CT angiography and magnetic resonance angiography were the traditional options, while 3-D ultrasound and contrast-enhanced ultrasound were proven the utility for immediate detection on the critical scenario. Because of the absence of contrast-enhanced ultrasound in our hospital, we used regular ultrasound examination as a screening tool along with a CT scan for confirmation. Moreover, apart from the diagnosis of AAA and AVF, ultrasound-based assessment of AAA geometry and patient-specific risk factors analysis would help reveal the severity. The individualized biomechanical model

predicted morbidity and mortality, which guided the precautions and therapeutic choices.

AVF was a rare pathology, and our case study demonstrated that ultrasonography was a rapid and non-invasive method for the initial assessment of AAA and AVF. However, deficiencies could be found via the post-mortem on our case. It was 9 days since the onset of the symptoms, and we did not have an opportunity for the interventional procedure because of the deteriorations of the clinical condition and acute kidney failure after the admission.

3-D ultrasound is sparsely implemented in the management of AAA but is raising interest for its unique value. We propose that ultrasound should be used more commonly as part of the initial evaluation of the potential and established vascular diseases, particularly in patients presenting hepatorenal dysfunction without a cause.

List of Abbreviations

AAA, abdominal aortic aneurysm; AVF, arteriovenous fistula; IVC, inferior vena cava; CRRT, continuous renal replacement therapy; CT, computed tomography; ICU, intensive care unit; ALT, alanine transaminase; AST, aspartate transaminase; TBIL, total bilirubin; DBIL, direct bilirubin; SCr, serum creatinine; BUN, blood urea nitrogen; POCUS, point of care ultrasonography.

Acknowledgements

This work was supported by the grant from National Clinical Key Specialty Construction Project of China (2012-649, 2013-544) and Medical Scientific Research Foundation of Guangdong Province, Guangdong, People's Republic of China (Grant number: A2018064).

Conflict of Interest

The authors declare that they have no conflict of interest.

Submitted: November 11, 2019

Accepted: February 14, 2020

Published: March 30, 2020

References

- Ali, M. U., Fitzpatrick-Lewis, D., Miller, J., Warren, R., Kenny, M., Sherifali, D. and Raina, P. (2016) Screening for Abdominal Aortic Aneurysm in Asymptomatic Adults. *Journal of Vascular Surgery* **64**, 1855-1868.
- Armon, M., Wenham, P., Whitaker, S., Gregson, R. and Hopkinson, B. (1998) Common Iliac Artery Aneurysms in Patients with Abdominal Aortic Aneurysms. *European Journal of Vascular and Endovascular Surgery* **15**, 255-257.
- Bode, P., Edwards, M., Kruit, M. and Van Vugt, A. (1999) Sonography in a Clinical Algorithm for Early Evaluation of 1671 Patients with Blunt Abdominal Trauma. *AJR American Journal of Roentgenology* **172**, 905-911.
- Catalano, O., Lobianco, R., Cusati, B. and Siani, A. (2005) Contrast-Enhanced Sonography for Diagnosis of Ruptured Abdominal Aortic Aneurysm. *American Journal of Roentgenology* **184**, 423-427.
- Chun, K. C., Anderson, R. C., Smothers, H. C., Sood, K., Irwin, Z. T., Wilson, M. D. and Lee, E. S. (2019) Risk of Developing an Abdominal Aortic Aneurysm after Ectatic Aorta Detection from Initial Screening. *Journal of Vascular Surgery*
- Coulrier, B., Tilquin, O. and Etienne, P.-Y. (2004) Multidetector Row Ct Diagnosis of Aortocaval Fistula Complicating Aortic Aneurysm: A Case Report. *Emergency Radiology* **11**, 100-103.

- Goergen, C. J., Johnson, B. L., Greve, J. M., Taylor, C. A. and Zarins, C. K. (2007) Increased Anterior Abdominal Aortic Wall Motion: Possible Role in Aneurysm Pathogenesis and Design of Endovascular Devices. *Journal of Endovascular Therapy* **14**, 574-584.
- Gregoric, I. D., Jacobs, M. J., Reul, G. J. and Rochelle, D. G. (1991) Spontaneous Common Iliac Arteriovenous Fistula Manifested by Acute Renal Failure: A Case Report. *Journal of Vascular Surgery* **14**, 92-97.
- Jones, P. G., Peak, S., McClelland, A., Holden, A., Higginson, I. and Gamble, G. (2003) Emergency Ultrasound Credentialling for Focused Assessment Sonography in Trauma and Abdominal Aortic Aneurysm: A Practical Approach for Australasia. *Emergency Medicine* **15**, 54-62.
- Lau, L. L., O'Reilly, M. J., Johnston, L. C. and Lee, B. (2001) Endovascular Stent-Graft Repair of Primary Aortocaval Fistula with an Abdominal Aortoiliac Aneurysm. *Journal of Vascular Surgery* **33**, 425-428.
- Lowe, C., Ghulam, Q., Bredahl, K., Rogers, S., Ghosh, J., Sillesen, H., McCollum, C. and Eiberg, J. (2016) Three-Dimensional Ultrasound in the Management of Abdominal Aortic Aneurysms: A Topical Review. *European Journal of Vascular and Endovascular Surgery* **52**, 466-474.
- Manning, B. J., Kristmundsson, T., Sonesson, B. and Resch, T. (2009) Abdominal Aortic Aneurysm Diameter: A Comparison of Ultrasound Measurements with Those from Standard and Three-Dimensional Computed Tomography Reconstruction. *Journal of Vascular Surgery* **50**, 263-268.
- Miller, J., Grimes, P. and Miller, J. (1999) Case Report of an Intraperitoneal Ruptured Abdominal Aortic Aneurysm Diagnosed with Bedside Ultrasonography. *Academic Emergency Medicine* **6**, 661-664.
- Owen, B., Lowe, C., Ashton, N., Mandal, P., Rogers, S., Wein, W., McCollum, C. and Revell, A. (2016) Computational Hemodynamics of Abdominal Aortic Aneurysms: Three-Dimensional Ultrasound Versus Computed Tomography. *Proceedings of the Institution of Mechanical Engineers, Part H: Journal of Engineering in Medicine* **230**, 201-210.
- Rogers, S., Lowe, C., Carreira, J., McCollum, C. and Ghosh, J. (2019) Comparison of Contrast-Enhanced Tomographic 3-D Ultrasound against Rotational Angiography Imaging Immediately after Endovascular Aneurysm Repair. *Ultrasound in Medicine & Biology* **45**, 2356-2362.
- Rosenthal, D., Atkins, C. P., Jerrius, H. S., Clark, M. D. and Matsuura, J. H. (1998) Diagnosis of Aortocaval Fistula by Computed Tomography. *Annals of Vascular Surgery* **12**, 86-87.
- Scaife, M., Giannakopoulos, T., Al-Khoury, G. E., Chaer, R. A. and Avgerinos, E. D. (2016) Contemporary Applications of Ultrasound in Abdominal Aortic Aneurysm Management. *Frontiers in Surgery* **3**, 29.
- Sidloff, D., Stather, P., Dattani, N., Bown, M., Thompson, J., Sayers, R. and Choke, E. (2014) Aneurysm Global Epidemiology Study: Public Health Measures Can Further Reduce Abdominal Aortic Aneurysm Mortality. *Circulation* **129**, 747-753.
- Simsek, E., Caliskan, A., Tutun, U. and Sahin, S. (2014) Cause of a Rare Acute Renal Insufficiency: Rupture Aortocaval Fistula. *Vascular* **22**, 290-292.
- van Disseldorp, E. M., van Dronkelaar, J. J., Pluim, J. P., van de Vosse, F. N., van Sambeek, M. R. and Lopata, R. G. (2020) Ultrasound Based Wall Stress Analysis of Abdominal Aortic Aneurysms Using Multiperspective Imaging. *European Journal of Vascular and Endovascular Surgery* **59**, 81-91.
- Wilmink, A. and Quick, C. G. (1998) Epidemiology and Potential for Prevention of Abdominal Aortic Aneurysm. *British Journal of Surgery* **85**, 155-162.